A 47-year-old man is treated for bacterial sinusitis with ampicillin. A week later he comes to the emergency department with fever and a skin rash. He also reports low urine output. Temperature is 37.5 C (99.5 F), blood pressure is 123/71 mm Hg, and pulse is 88/min. Physical examination shows a diffuse maculopapular rash. Serum creatinine level is 2.4 mg/dL, and urine sediment microscopy reveals 3-4 red blood cells/hpf, 5-10 white blood cells/hpf, and 3-5 eosinophils/hpf. The pathologic process affecting this patient's kidneys most likely involves which of the following structures?

- A. Calyces and ureters
- B. Glomeruli
- C. Renal interstitium
- D. Renal papillae
- E. Small renal arterioles

Submit

A 47-year-old man is treated for bacterial sinusitis with ampicillin. A week later he comes to the emergency department with fever and a skin rash. He also reports low urine output. Temperature is 37.5 C (99.5 F), blood pressure is 123/71 mm Hg, and pulse is 88/min. Physical examination shows a diffuse maculopapular rash. Serum creatinine level is 2.4 mg/dL, and urine sediment microscopy reveals 3-4 red blood cells/hpf, 5-10 white blood cells/hpf, and 3-5 eosinophils/hpf. The pathologic process affecting this patient's kidneys most likely involves which of the following structures?

- A. Calyces and ureters (2%)
- B. Glomeruli (21%)
- ✓ C. Renal interstitium (62%)
- D. Renal papillae (11%)
- E. Small renal arterioles (2%)

Omitted
Correct answer
C

62%
Answered correctly

07 secs
Time Spent

07/02/2020
Last Updated

Explanation

| Acute interstitial nephritis | |
|---|---|
| | • **Antibiotics** (eg, beta-lactam, sulfonamide, rifampin)<br>• Proton pump inhibitors |

Explanation

| Acute interstitial nephritis | |
|---|---|
| **Causes** | • **Antibiotics** (eg, beta-lactam, sulfonamide, rifampin)<br>• Proton pump inhibitors<br>• NSAIDs<br>• Diuretics<br>• Other: Autoimmune diseases, *Mycoplasma*, *Legionella* |
| **Clinical features** | • Rash, fever, or asymptomatic<br>• New drug exposure |
| **Laboratory findings** | • Acute kidney injury<br>• Pyuria, hematuria, WBC casts<br>• Eosinophilia, **urinary eosinophils**<br>• Renal biopsy: Inflammatory interstitial infiltrate and edema |
| **NSAIDs** = nonsteroidal anti-inflammatory drugs; **WBC** = white blood cell. | |

Fever, maculopapular rash, and acute renal failure (eg, elevated creatinine, oliguria) occurring within a few weeks of starting a **beta-lactam antibiotic** are highly suggestive of drug-induced **acute interstitial nephritis** (AIN). Other commonly implicated medications include nonsteroidal anti-inflammatory drugs, sulfonamides, rifampin, proton pump inhibitors, and diuretics. Many patients have increased levels of serum eosinophils and **eosinophiluria** (detected by Hansel or Wright stain). Urinalysis may also show white blood cells, white blood cell casts, and red blood cells. Symptoms most commonly occur **1-3 weeks after drug initiation** and typically resolve with cessation of the offending medication.

AIN is thought to be due to IgE-mediated (type I) or cell-mediated (type IV) hypersensitivity. It primarily involves the **renal interstitium**, causing interstitial edema and **leukocyte infiltration** (particularly lymphocytes, macrophages, and eosinophils). Inflammatory cells commonly infiltrate the tubular epithelium (tubulitis) and granuloma formation may be observed.

AIN is thought to be due to IgE-mediated (type I) or cell-mediated (type IV) hypersensitivity. It primarily involves the **renal interstitium**, causing interstitial edema and **leukocyte infiltration** (particularly lymphocytes, macrophages, and eosinophils). Inflammatory cells commonly infiltrate the tubular epithelium (tubulitis) and granuloma formation may be observed.

**(Choice A)** Calyces and ureters are most commonly involved in nephrolithiasis and associated hydronephrosis, which can cause hematuria and renal failure. However, nephrolithiasis typically causes flank pain; fever, rash, and eosinophiluria would be unexpected.

**(Choice B)** Glomeruli are involved in poststreptococcal glomerulonephritis, which can cause acute kidney injury 1-3 weeks after infection with group A beta-hemolytic streptococcus. However, dysmorphic red blood cells and/or red blood cell casts would be expected in a nephritic disease; eosinophiluria, fever, and rash are more consistent with AIN.

**(Choice D)** Pathology affecting the renal papillae (papillary necrosis) is common in severe, acute pyelonephritis and in patients with sickle cell disease, diabetes mellitus, or analgesic nephropathy. Urinalysis shows hematuria or sterile pyuria, but rash and eosinophiluria are unexpected.

**(Choice E)** Small renal arterioles are not involved in AIN. They are most commonly damaged in hypertensive or diabetic nephropathy, which typically presents with proteinuria, not with pyuria and urinary eosinophils.

**Educational objective:**
Fever, maculopapular rash, and acute renal failure occurring 1-3 weeks after beginning a new medication (eg, antibiotics, proton pump inhibitors) is highly suggestive of acute interstitial nephritis. Peripheral eosinophilia, sterile pyuria, eosinophiluria, and white blood cell casts may also be seen. Histology reveals leukocyte infiltration and edema of the renal interstitium.

**References**

- Acute interstitial nephritis—a reappraisal and update.

| Pathology | Renal, Urinary Systems & Electrolytes | Acute interstitial nephritis |
|---|---|---|
| Subject | System | Topic |

Copyright © UWorld. All rights reserved.

A 20-year-old woman develops gross hematuria. She otherwise feels well and has had no recent illnesses. The patient was diagnosed with type 1 diabetes mellitus approximately 1 year ago and is taking daily insulin injections. She works in a day care center and does not use tobacco, alcohol, or illicit drugs. Temperature is 37 C (98.6 F), blood pressure is 120/80 mm Hg, and pulse is 80/min. Physical examination shows no abnormalities. Laboratory results are as follows:

| | |
|---|---|
| Serum creatinine | 1.0 mg/dL |
| Serum albumin | 4.0 mg/dL |
| Urinalysis | numerous red blood cells (RBCs) and few RBC casts; 1+ protein |
| Serum complement | normal |

Which of the following is the most likely diagnosis?

- A. Diabetic nephropathy
- B. IgA nephropathy
- C. Membranous nephropathy
- D. Minimal change disease
- E. Poststreptococcal glomerulonephritis

Submit

A 20-year-old woman develops gross hematuria. She otherwise feels well and has had no recent illnesses. The patient was diagnosed with type 1 diabetes mellitus approximately 1 year ago and is taking daily insulin injections. She works in a day care center and does not use tobacco, alcohol, or illicit drugs. Temperature is 37 C (98.6 F), blood pressure is 120/80 mm Hg, and pulse is 80/min. Physical examination shows no abnormalities. Laboratory results are as follows:

| | |
|---|---|
| Serum creatinine | 1.0 mg/dL |
| Serum albumin | 4.0 mg/dL |
| Urinalysis | numerous red blood cells (RBCs) and few RBC casts; 1+ protein |
| Serum complement | normal |

Which of the following is the most likely diagnosis?

A. Diabetic nephropathy (18%)
✓ B. IgA nephropathy (46%)
C. Membranous nephropathy (14%)
D. Minimal change disease (6%)
E. Poststreptococcal glomerulonephritis (14%)

Omitted
Correct answer
B

46%
Answered correctly

06 secs
Time Spent

01/23/2020
Last Updated

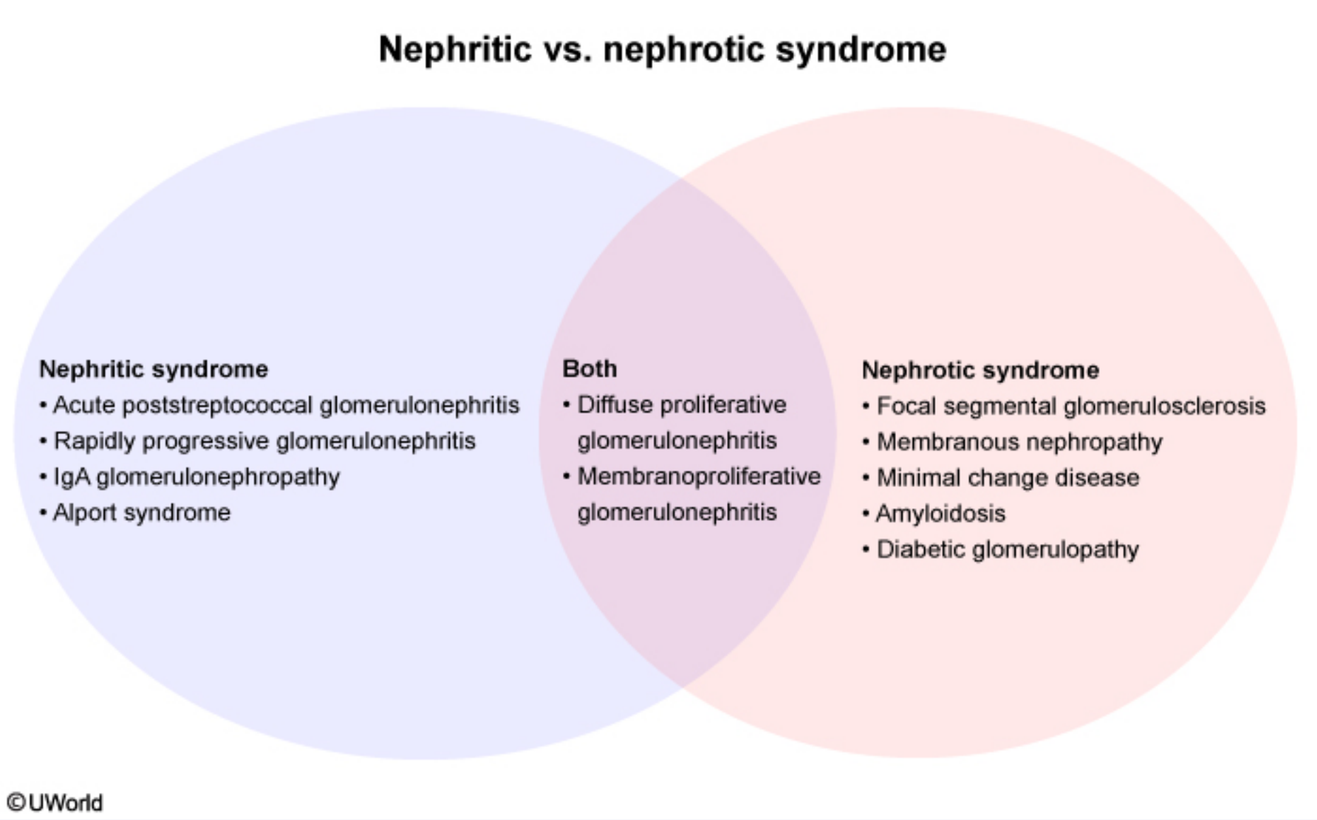


**Nephritic syndromes** (ie, glomerulonephritis) are characterized by glomerular inflammation, resulting in hematuria and **red blood cell casts** on urinalysis. Renal dysfunction (eg, azotemia) and hypertension are common but not always present in early disease. Patients may also have mild to moderate proteinuria and edema, although typically not as severe as in nephrotic syndrome.

The most common cause of nephritic syndrome is **immune complex deposition**. Most immune complex–related nephritic syndromes (eg, poststreptococcal glomerulonephritis [PSGN], membranoproliferative glomerulonephritis, lupus nephritis) are associated with IgG and/or IgM complexes and have heavy glomerular complement deposition and subsequent serum hypocomplementemia (consumption). However, **IgA**

**Nephritic syndromes** (ie, glomerulonephritis) are characterized by glomerular inflammation, resulting in hematuria and **red blood cell casts** on urinalysis. Renal dysfunction (eg, azotemia) and hypertension are common but not always present in early disease. Patients may also have mild to moderate proteinuria and edema, although typically not as severe as in nephrotic syndrome.

The most common cause of nephritic syndrome is **immune complex deposition**. Most immune complex–related nephritic syndromes (eg, poststreptococcal glomerulonephritis [PSGN], membranoproliferative glomerulonephritis, lupus nephritis) are associated with IgG and/or IgM complexes and have heavy glomerular complement deposition and subsequent serum hypocomplementemia (consumption). However, **IgA nephropathy** is typically associated with **normal serum complement levels**, likely due to the weak complement-fixing activity of IgA as compared to IgG and IgM.

IgA nephropathy is characterized as recurrent gross hematuria that typically occurs **spontaneously** (as in this patient) or within 5-7 days of an upper respiratory or pharyngeal infection (synpharyngitic hematuria). When IgA nephropathy is accompanied by extrarenal symptoms (eg, abdominal pain, arthralgias, skin purpura), the syndrome is called Henoch-Schönlein purpura.

**(Choices A, C, and D)** Nephrotic syndromes typically cause *heavy proteinuria with low albumin levels* and edema, rather than hematuria and red blood cell casts; etiologies include diabetic nephropathy, membranous nephropathy, and minimal change disease. Diabetic nephropathy typically takes >5 years to develop in type 1 diabetes (although it can be present at the time of diagnosis in type 2).

**(Choice E)** PSGN presents with nephritic syndrome 2-4 weeks after infection with group A *Streptococcus* (postpharyngitic hematuria). Over 90% of patients with PSGN develop marked hypocomplementemia.

**Educational objective:**
IgA nephropathy is characterized as recurrent hematuria that occurs spontaneously or within 5-7 days of an upper respiratory or pharyngeal infection (synpharyngitic hematuria). Unlike other causes of immune complex–mediated nephritic syndromes (eg, poststreptococcal glomerulonephritis), IgA nephropathy is associated with normal serum complement levels.

| Pathology | Renal, Urinary Systems & Electrolytes | IgA nephropathy |
|---|---|---|
| Subject | System | Topic |

Copyright © UWorld. All rights reserved.

A 55-year-old woman comes to the physician with swelling around her ankles and face that has progressively worsened over the last 1–2 months. The patient has 2+ bilateral pitting edema in the lower extremities, trace edema in the upper extremities, and periorbital edema. Cardiopulmonary examination is normal. Laboratory evaluation shows a serum creatinine level of 2.0 mg/dL and an albumin level of 2.8 g/dL. Urinalysis reveals 3+ proteinuria and no hematuria or casts. A kidney biopsy is performed; light microscopic findings following staining with hematoxylin and eosin are shown in the image below.

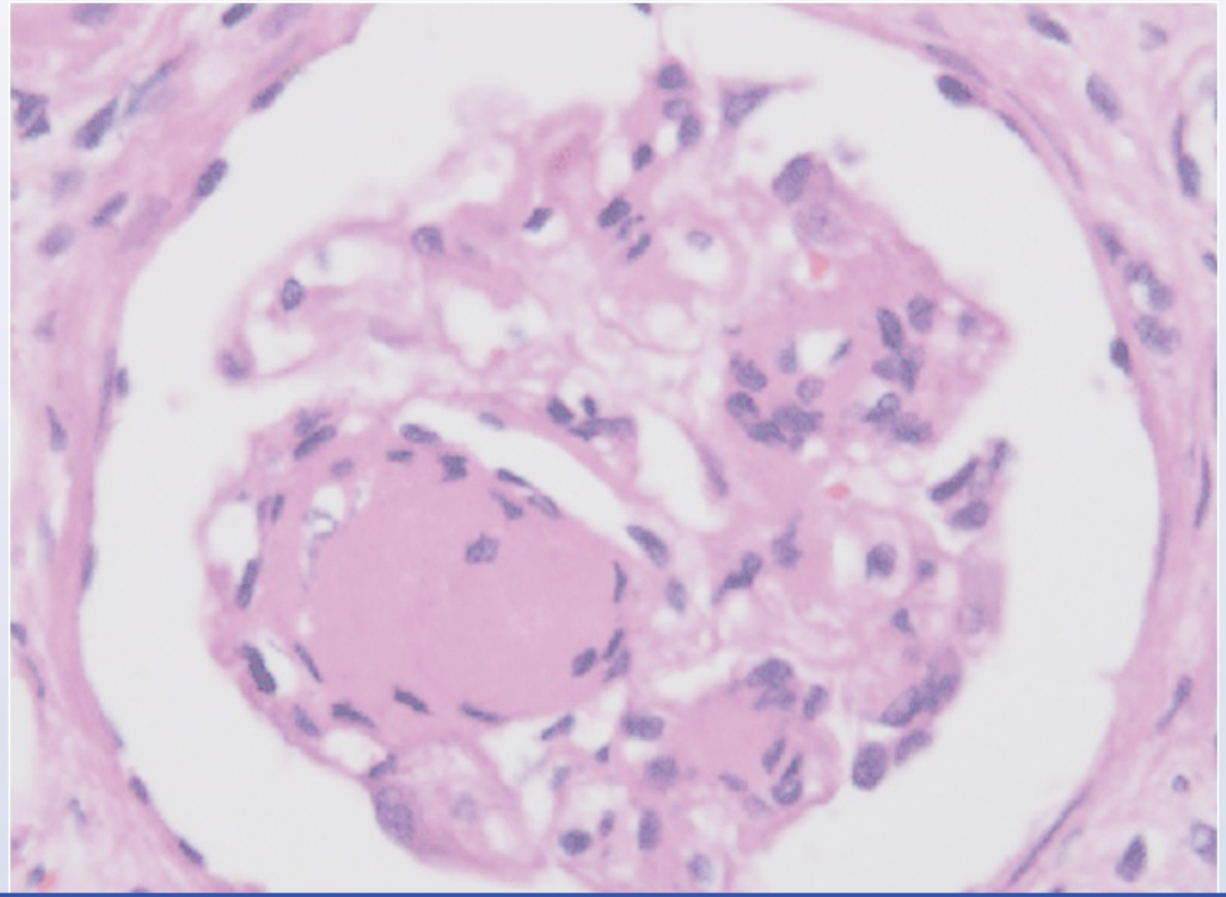

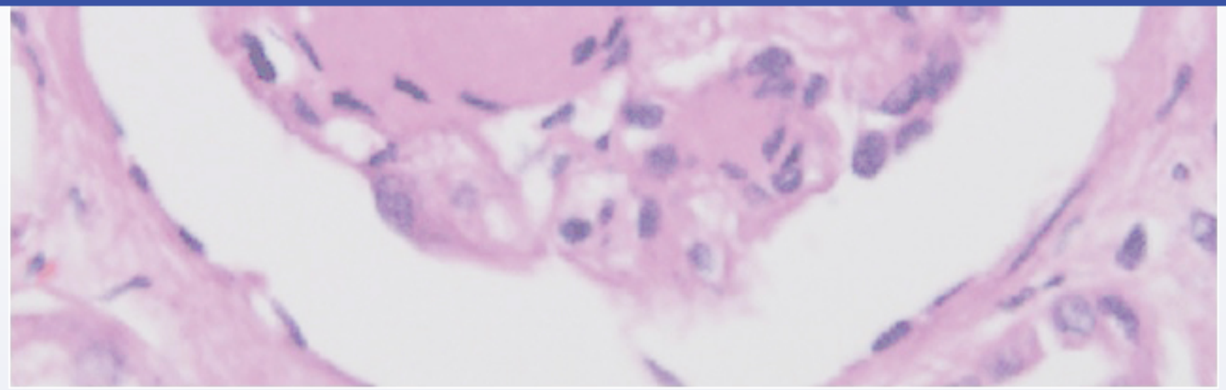

Which of the following is the most likely explanation for this patient's biopsy findings?

- A. Bee sting with severe allergic reaction
- B. Diabetes mellitus
- C. Hepatitis C infection
- D. HIV infection
- E. Lung carcinoma
- F. Recent streptococcal pharyngitis
- G. Systemic lupus erythematosus
- H. Treatment with procainamide

Submit

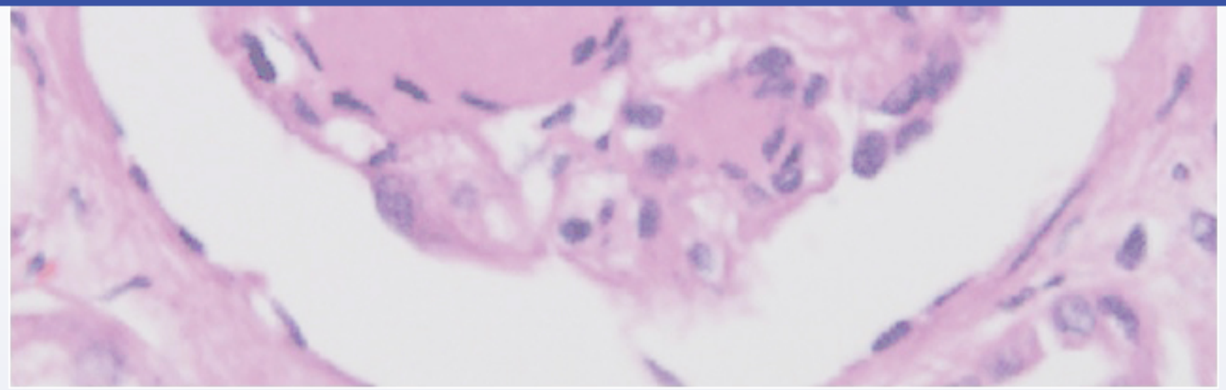

Which of the following is the most likely explanation for this patient's biopsy findings?

- A. Bee sting with severe allergic reaction
- B. Diabetes mellitus
- C. Hepatitis C infection
- D. HIV infection
- E. Lung carcinoma
- F. Recent streptococcal pharyngitis
- G. Systemic lupus erythematosus
- H. Treatment with procainamide

Submit

Settings

1 2 3 4 5 6 7 8 9 10 11 12 13 14 15 16 17 18 19 20 21 22 23 24 25 26 27 28 29 30

Item 3 of 39
Question Id: 884

Mark | Previous | Next | Full Screen | Tutorial | Lab Values | Notes | Calculator | Reverse Color | Text Zoom | Settings

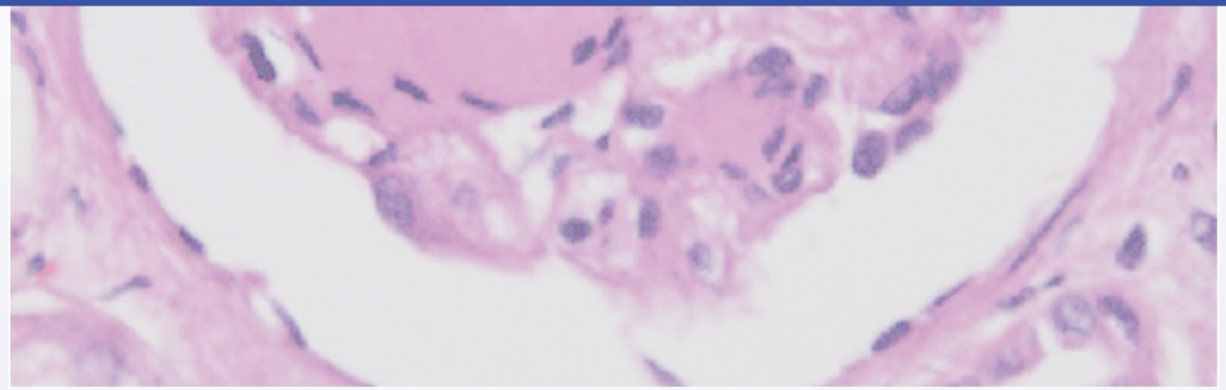

Which of the following is the most likely explanation for this patient's biopsy findings?

- A. Bee sting with severe allergic reaction (0%)
- ✓ B. Diabetes mellitus (73%)
- C. Hepatitis C infection (4%)
- D. HIV infection (5%)
- E. Lung carcinoma (0%)
- F. Recent streptococcal pharyngitis (4%)
- G. Systemic lupus erythematosus (9%)
- H. Treatment with procainamide (1%)

Omitted
Correct answer

73%
Answered correctly

19 secs
Time Spent

07/09/2020
Last Updated

Block Time Remaining: 00:00:32
TUTOR

10 | Feedback | Suspend | End Block

1
2
3
4
5
6
7
8
9
10
11
12
13
14
15
16
17
18
19
20
21
22
23
24
25
26
27
28
29
30

D. HIV infection (5%)

E. Lung carcinoma (0%)

F. Recent streptococcal pharyngitis (4%)

G. Systemic lupus erythematosus (9%)

H. Treatment with procainamide (1%)

Omitted
Correct answer
B

73%
Answered correctly

19 secs
Time Spent

07/09/2020
Last Updated

Explanation

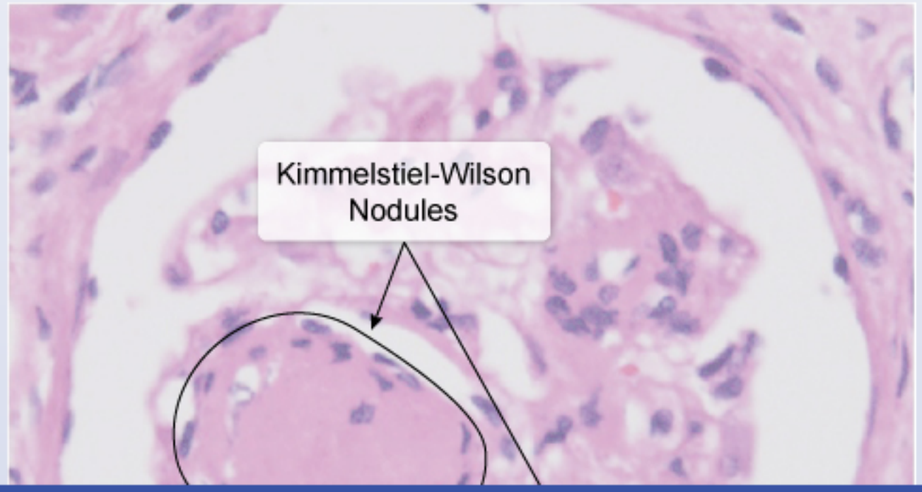

Explanation

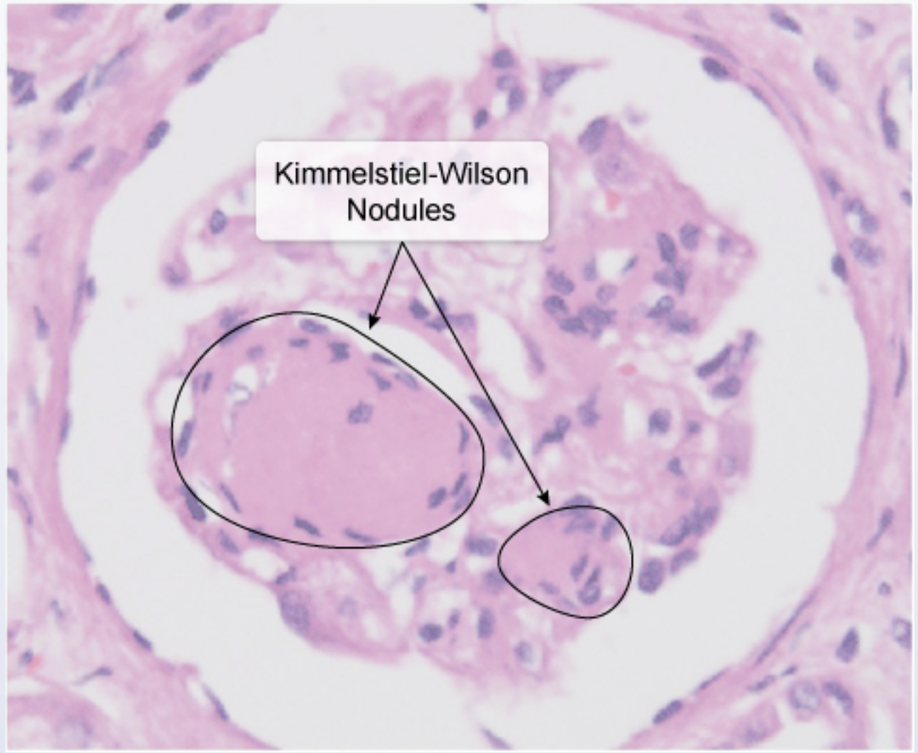


This patient's renal biopsy shows Kimmelstiel-Wilson (KW) nodules, characterized by:

- location in the peripheral mesangium
- ovoid or spherical shape
- lamellated appearance
- eosinophilic (hematoxylin and eosin stain)
- periodic acid-Schiff-positive

KW nodules are diagnostic for **nodular glomerulosclerosis**, which is characterized by **glomerular basement membrane thickening** and

This patient's renal biopsy shows Kimmelstiel-Wilson (KW) nodules, characterized by:

- location in the peripheral mesangium
- ovoid or spherical shape
- lamellated appearance
- eosinophilic (hematoxylin and eosin stain)
- periodic acid-Schiff-positive

KW nodules are diagnostic for **nodular glomerulosclerosis**, which is characterized by **glomerular basement membrane thickening** and **increased mesangial matrix deposition**. Over time, expansion of the mesangium and KW nodule formation compress the glomerular capillaries and cause loss of glomerular function. Patients have progressive proteinuria that can lead to overt **nephrotic syndrome** (eg, peripheral edema, heavy proteinuria, fatty casts), hypertension, and **renal failure**. The urine sediment is typically bland (ie, no red or white cells or casts).

Nodular glomerulosclerosis is most commonly caused by diabetic nephropathy (either type 1 or 2 diabetes mellitus). It indicates irreversible glomerular damage and predicts a rapid decline in kidney function.

Other causes of nephrotic syndrome include the following conditions:

**(Choice A)** Minimal change disease can occur as an immunologic reaction to pollen/dust, insect stings, infection, or immunization. The glomeruli appear normal on light microscopy. Electron microscopy shows fusion and effacement of podocyte foot processes.

**(Choice C)** Membranoproliferative glomerulonephritis is often associated with hepatitis B or C infection. Light microscopy shows hypercellular glomeruli with thickening and splitting of the glomerular basement membrane due to subendothelial immune complex deposition.

**(Choice D)** Focal segmental glomerulosclerosis can be associated with HIV infection, heroin abuse, and severe obesity. Light microscopy shows sclerotic changes in some portions of some glomeruli.

**(Choice E)** Solid tumors (eg, lung, breast, prostate) are associated with membranous glomerulonephritis. Light microscopy shows capillary wall thickening and "membrane spikes" (subepithelial deposits) on silver staining.

By contrast, a predominantly nephritic presentation (eg, hematuria, red cell casts, variable proteinuria) may be caused by the following conditions:

KW nodules are diagnostic for **nodular glomerulosclerosis**, which is characterized by **glomerular basement membrane thickening** and **increased mesangial matrix deposition**. Over time, expansion of the mesangium and KW nodule formation compress the glomerular capillaries and cause loss of glomerular function. Patients have progressive proteinuria that can lead to overt **nephrotic syndrome** (eg, peripheral edema, heavy proteinuria, fatty casts), hypertension, and **renal failure**. The urine sediment is typically bland (ie, no red or white cells or casts).

Nodular glomerulosclerosis is most commonly caused by diabetic nephropathy (either type 1 or 2 diabetes mellitus). It indicates irreversible glomerular damage and predicts a rapid decline in kidney function.

Other causes of nephrotic syndrome include the following conditions:

**(Choice A)** Minimal change disease can occur as an immunologic reaction to pollen/dust, insect stings, infection, or immunization. The glomeruli appear normal on light microscopy. Electron microscopy shows fusion and effacement of podocyte foot processes.

**(Choice C)** Membranoproliferative glomerulonephritis is often associated with hepatitis B or C infection. Light microscopy shows hypercellular glomeruli with thickening and splitting of the glomerular basement membrane due to subendothelial immune complex deposition.

**(Choice D)** Focal segmental glomerulosclerosis can be associated with HIV infection, heroin abuse, and severe obesity. Light microscopy shows sclerotic changes in some portions of some glomeruli.

**(Choice E)** Solid tumors (eg, lung, breast, prostate) are associated with membranous glomerulonephritis. Light microscopy shows capillary wall thickening and "membrane spikes" (subepithelial deposits) on silver staining.

By contrast, a predominantly nephritic presentation (eg, hematuria, red cell casts, variable proteinuria) may be caused by the following conditions:

**(Choice F)** In poststreptococcal glomerulonephritis, light microscopy shows diffuse glomerular hypercellularity due to leukocyte infiltration and mesangial cell proliferation. Immunofluorescence shows IgG and C3 deposits, which can be further visualized on electron microscopy as large subepithelial humps.

**(Choices G and H)** Lupus nephritis most frequently manifests as diffuse proliferative glomerulonephritis. Drug-induced lupus (eg, procainamide, hydralazine, isoniazid) in rare cases can cause similar kidney involvement. Light microscopy shows proliferation of lymphocytes and endothelial cells within the capillary loops. Diffuse wire loop deposits may also be seen.

KW nodules are diagnostic for **nodular glomerulosclerosis**, which is characterized by **glomerular basement membrane thickening** and

Exhibit Display

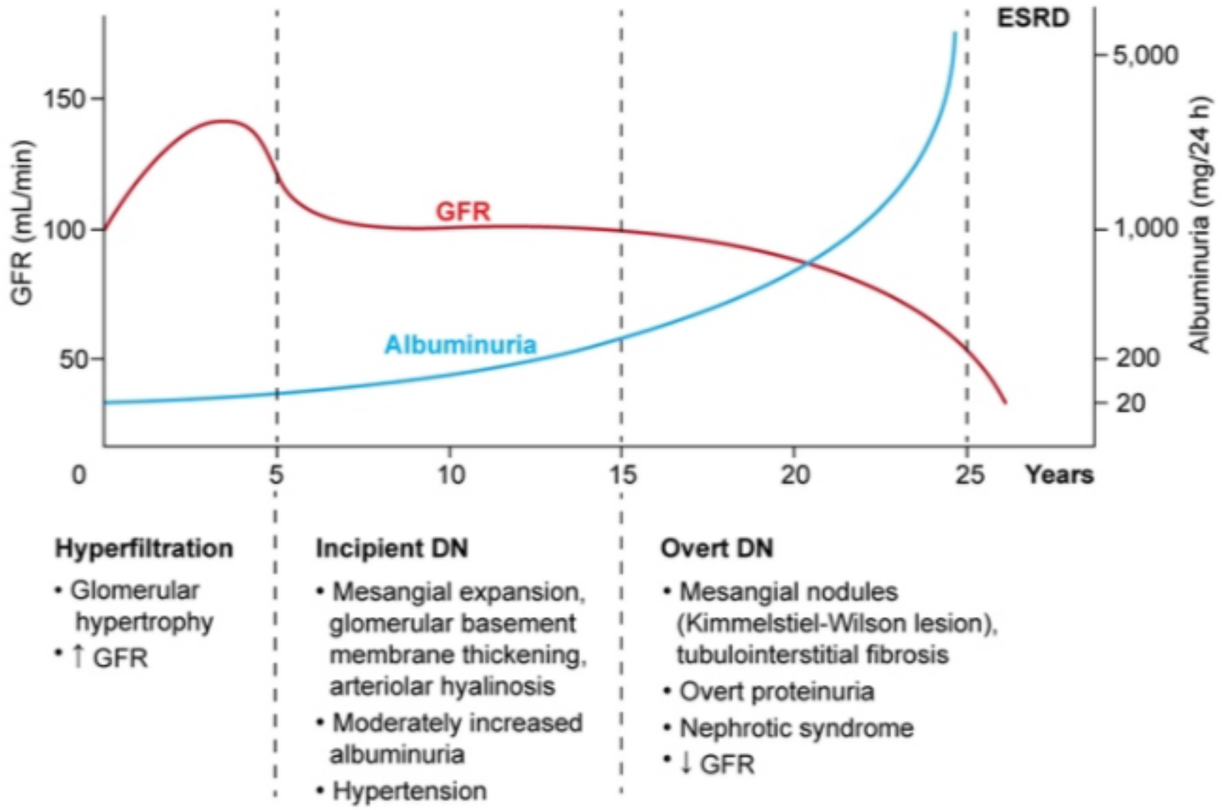


**DN** = diabetic nephropathy; **ESRD** = end-stage renal disease; **GFR** = glomerular filtration rate.
©UWorld

Zoom In | Zoom Out | Reset | Add To New Card | Existing Card

Settings

1
2
3
4
5
6
7
8
9
10
11
12
13
14
15
16
17
18
19
20
21
22
23
24
25
26
27
28
29
30

Item 3 of 39
Question Id: 884

Mark | Previous | Next | Full Screen | Tutorial | Lab Values | Notes | Calculator | Reverse Color | Text Zoom | Settings

KW nodules are diagnostic for **nodular glomerulosclerosis**, which is characterized by **glomerular basement membrane thickening** and

Exhibit Display

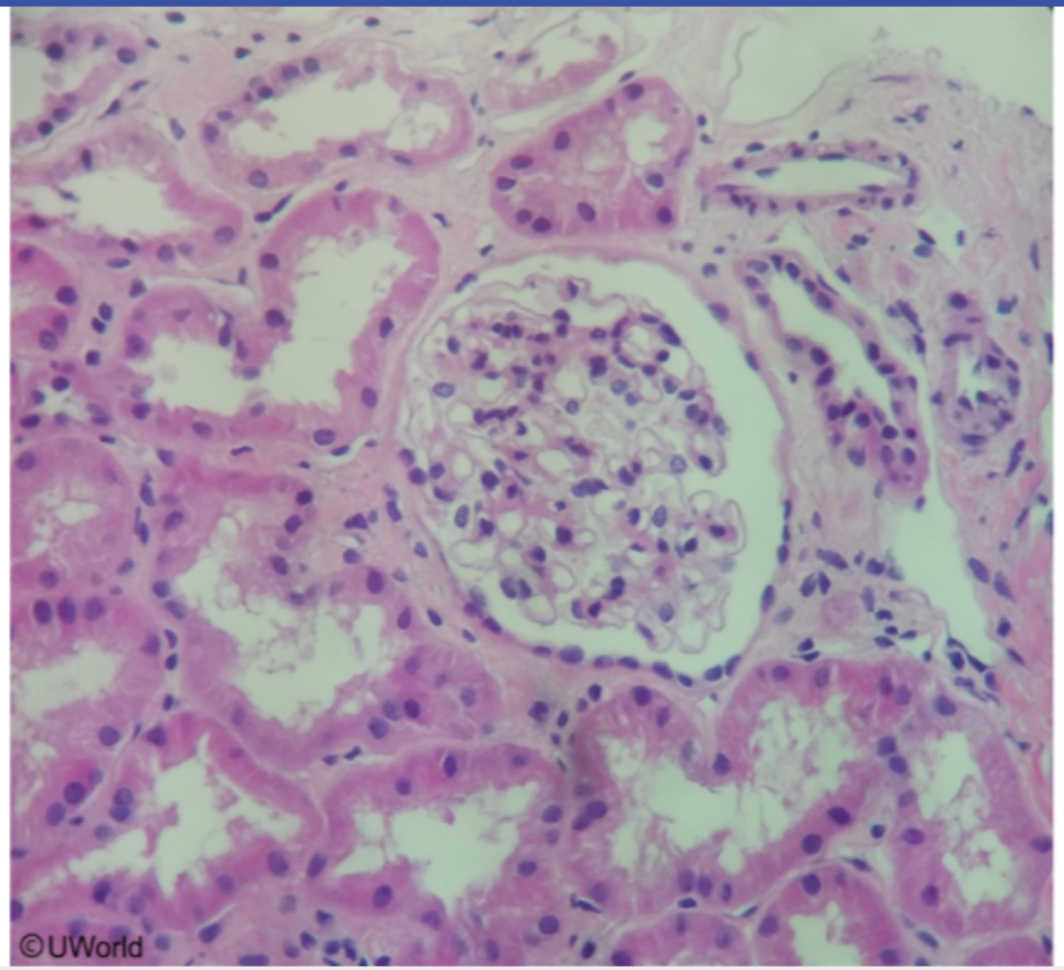


Zoom In | Zoom Out | Reset | Add To New Card | Existing Card

Block Time Remaining: 00:00:32
TUTOR

10 | Feedback | Suspend | End Block

Settings

1
2
3
4
5
6
7
8
9
10
11
12
13
14
15
16
17
18
19
20
21
22
23
24
25
26
27
28
29
30

Item 3 of 39
Question Id: 884

Mark | Previous | Next | Full Screen | Tutorial | Lab Values | Notes | Calculator | Reverse Color | Text Zoom | Settings

KW nodules are diagnostic for **nodular glomerulosclerosis**, which is characterized by **glomerular basement membrane thickening** and

Exhibit Display

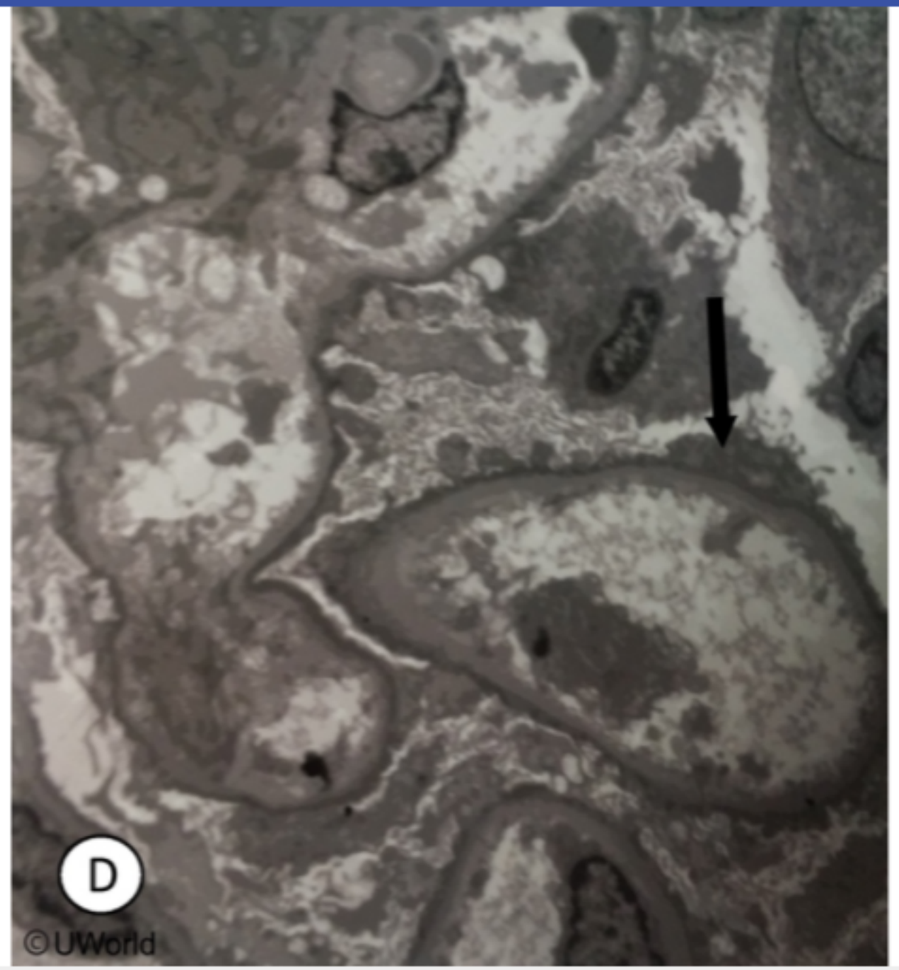


Zoom In | Zoom Out | Reset | Add To New Card | Existing Card

Block Time Remaining: 00:00:32
TUTOR

10 | Feedback | Suspend | End Block

Settings

1
2
3
4
5
6
7
8
9
10
11
12
13
14
15
16
17
18
19
20
21
22
23
24
25
26
27
28
29
30

Item 3 of 39
Question Id: 884

Mark | Previous | Next | Full Screen | Tutorial | Lab Values | Notes | Calculator | Reverse Color | Text Zoom | Settings

KW nodules are diagnostic for **nodular glomerulosclerosis**, which is characterized by **glomerular basement membrane thickening** and

**Exhibit Display**

Membranoproliferative glomerulonephritis, Type I  Membranoproliferative glomerulonephritis, Type I

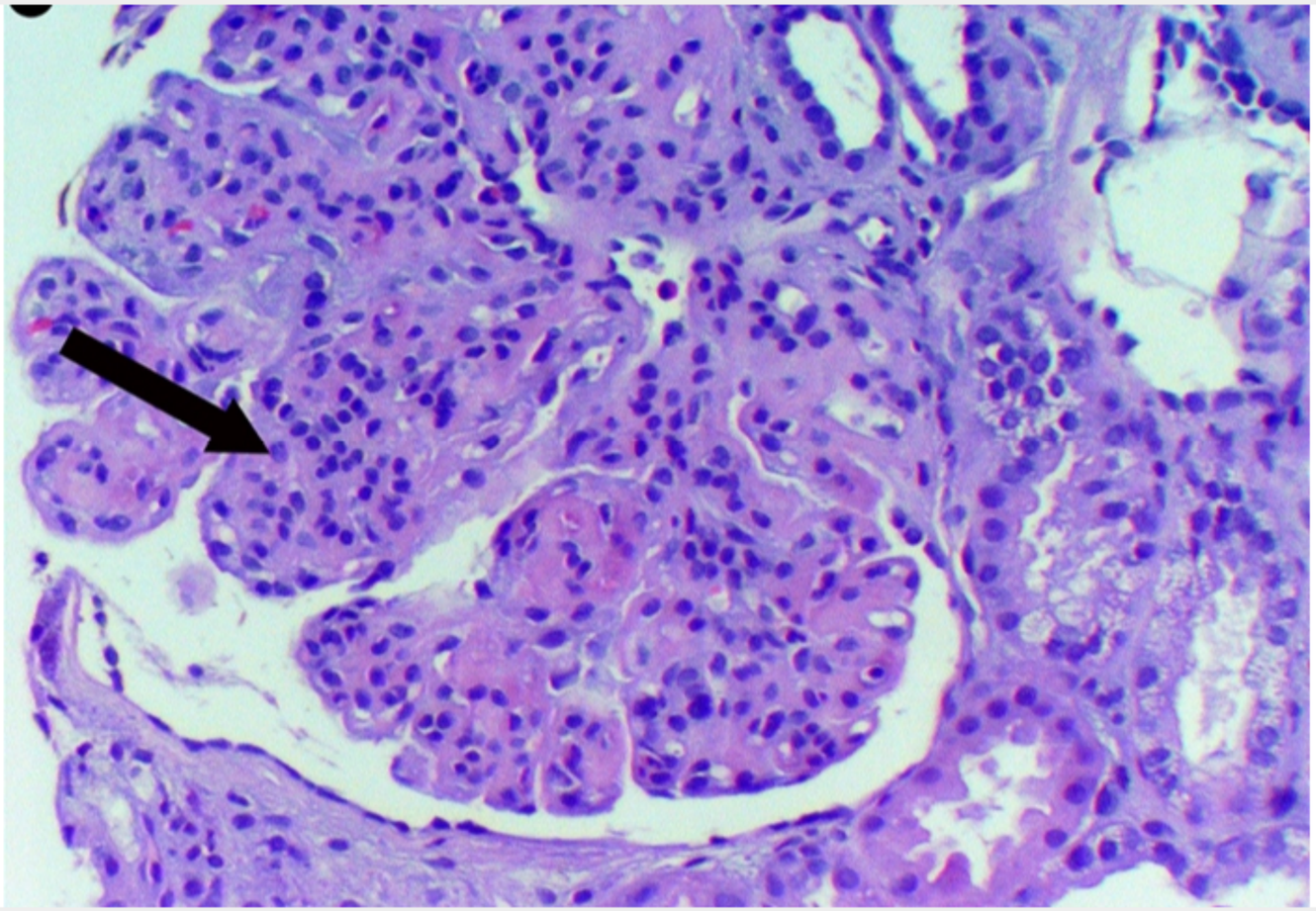

Zoom In | Zoom Out | Reset | Add To New Card | Existing Card

**Block Time Remaining: 00:00:32**
**TUTOR**

10 | Feedback | Suspend | End Block

Settings

1
2
3
4
5
6
7
8
9
10
11
12
13
14
15
16
17
18
19
20
21
22
23
24
25
26
27
28
29
30

Item 3 of 39
Question Id: 884

Mark | Previous | Next | Full Screen | Tutorial | Lab Values | Notes | Calculator | Reverse Color | Text Zoom | Settings

KW nodules are diagnostic for **nodular glomerulosclerosis**, which is characterized by **glomerular basement membrane thickening** and

**Exhibit Display**

Membranoproliferative glomerulonephritis, Type I Membranoproliferative glomerulonephritis, Type I

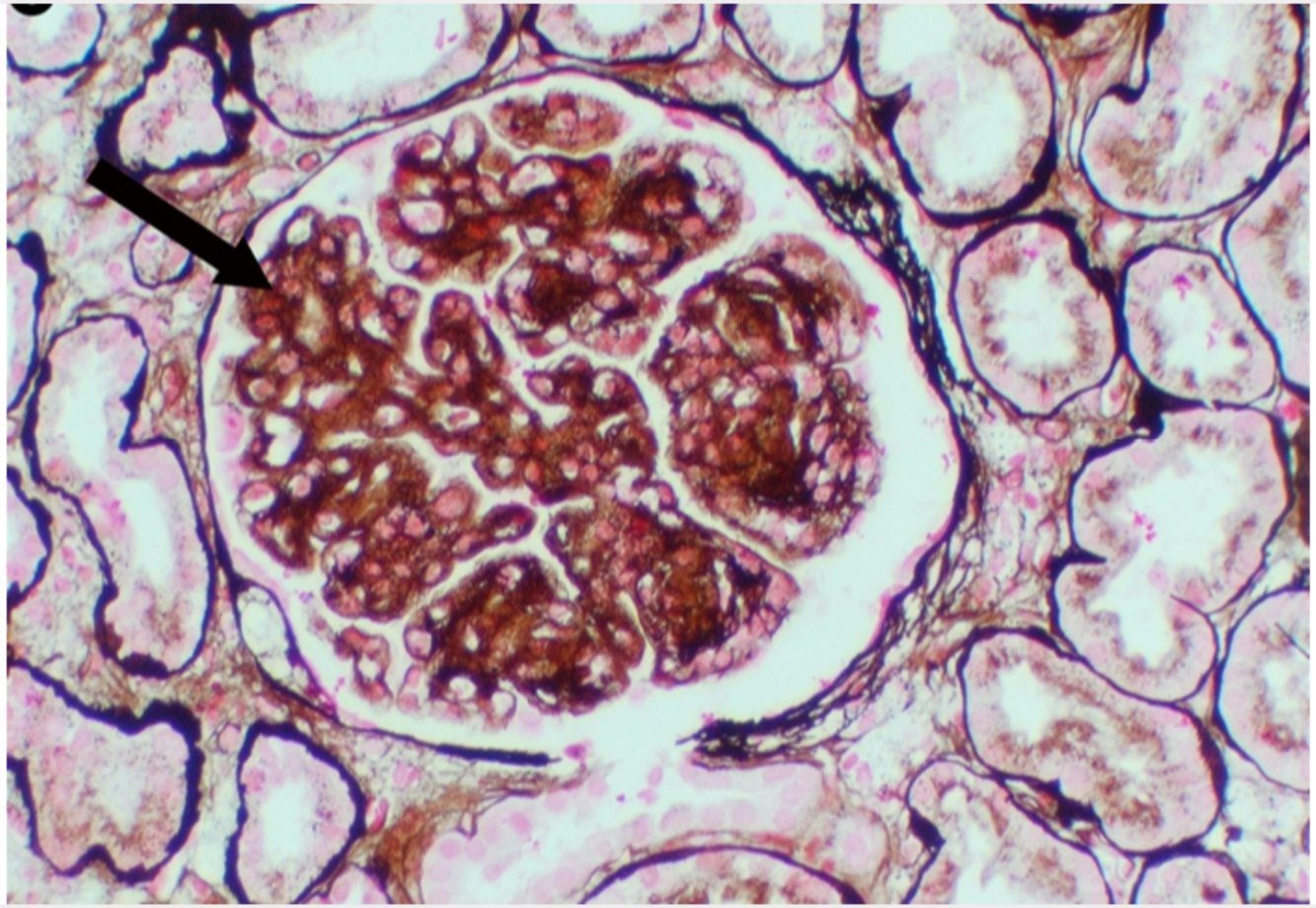

Zoom In | Zoom Out | Reset | Add To New Card | Existing Card

**Block Time Remaining: 00:00:32**
TUTOR

10 | Feedback | Suspend | End Block

Settings

1
2
3
4
5
6
7
8
9
10
11
12
13
14
15
16
17
18
19
20
21
22
23
24
25
26
27
28
29
30

Item 3 of 39
Question Id: 884

Mark | Previous | Next | Full Screen | Tutorial | Lab Values | Notes | Calculator | Reverse Color | Text Zoom | Settings

KW nodules are diagnostic for **nodular glomerulosclerosis**, which is characterized by **glomerular basement membrane thickening** and

**Exhibit Display**

Focal segmental glomerulosclerosis (PAS stain) Focal segmental glomerulosclerosis (Jones silver s

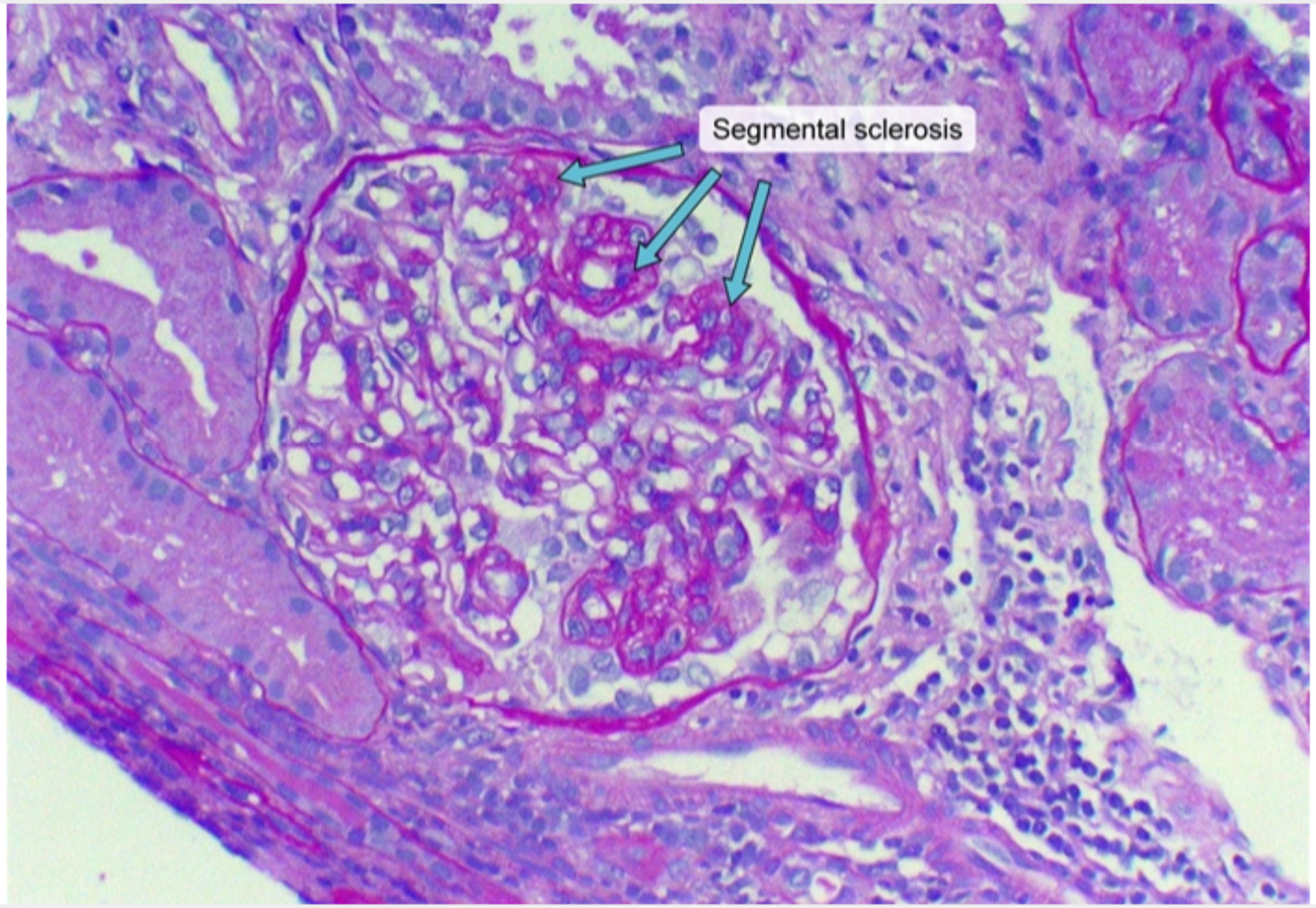


Zoom In | Zoom Out | Reset | Add To New Card | Existing Card

**Block Time Remaining: 00:00:32**
TUTOR

10 | Feedback | Suspend | End Block

Settings

1
2
3
4
5
6
7
8
9
10
11
12
13
14
15
16
17
18
19
20
21
22
23
24
25
26
27
28
29
30

Item 3 of 39
Question Id: 884

Mark | Previous | Next | Full Screen | Tutorial | Lab Values | Notes | Calculator | Reverse Color | Text Zoom | Settings

KW nodules are diagnostic for **nodular glomerulosclerosis**, which is characterized by **glomerular basement membrane thickening** and

**Exhibit Display**

Focal segmental glomerulosclerosis (PAS stain) Focal segmental glomerulosclerosis (Jones silver s

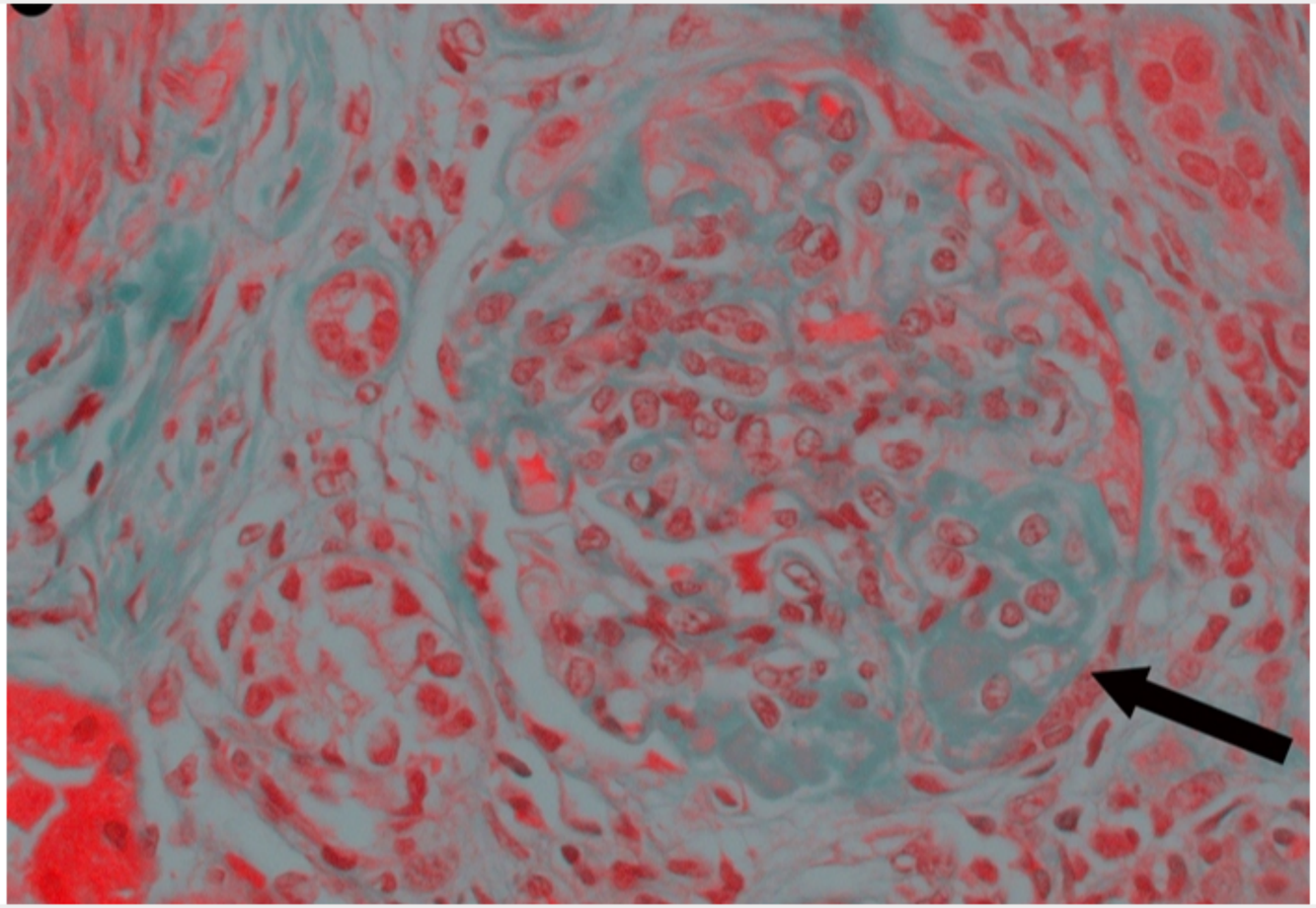

Zoom In | Zoom Out | Reset | Add To New Card | Existing Card

**Block Time Remaining: 00:00:32**
TUTOR

10 | Feedback | Suspend | End Block

Settings

1
2
3
4
5
6
7
8
9
10
11
12
13
14
15
16
17
18
19
20
21
22
23
24
25
26
27
28
29
30

Item 3 of 39
Question Id: 884

Mark | Previous | Next | Full Screen | Tutorial | Lab Values | Notes | Calculator | Reverse Color | Text Zoom | Settings

**(Choice A)** Minimal change disease can occur as an immunologic reaction to pollen/dust, insect stings, infection, or immunization. The

**Exhibit Display**

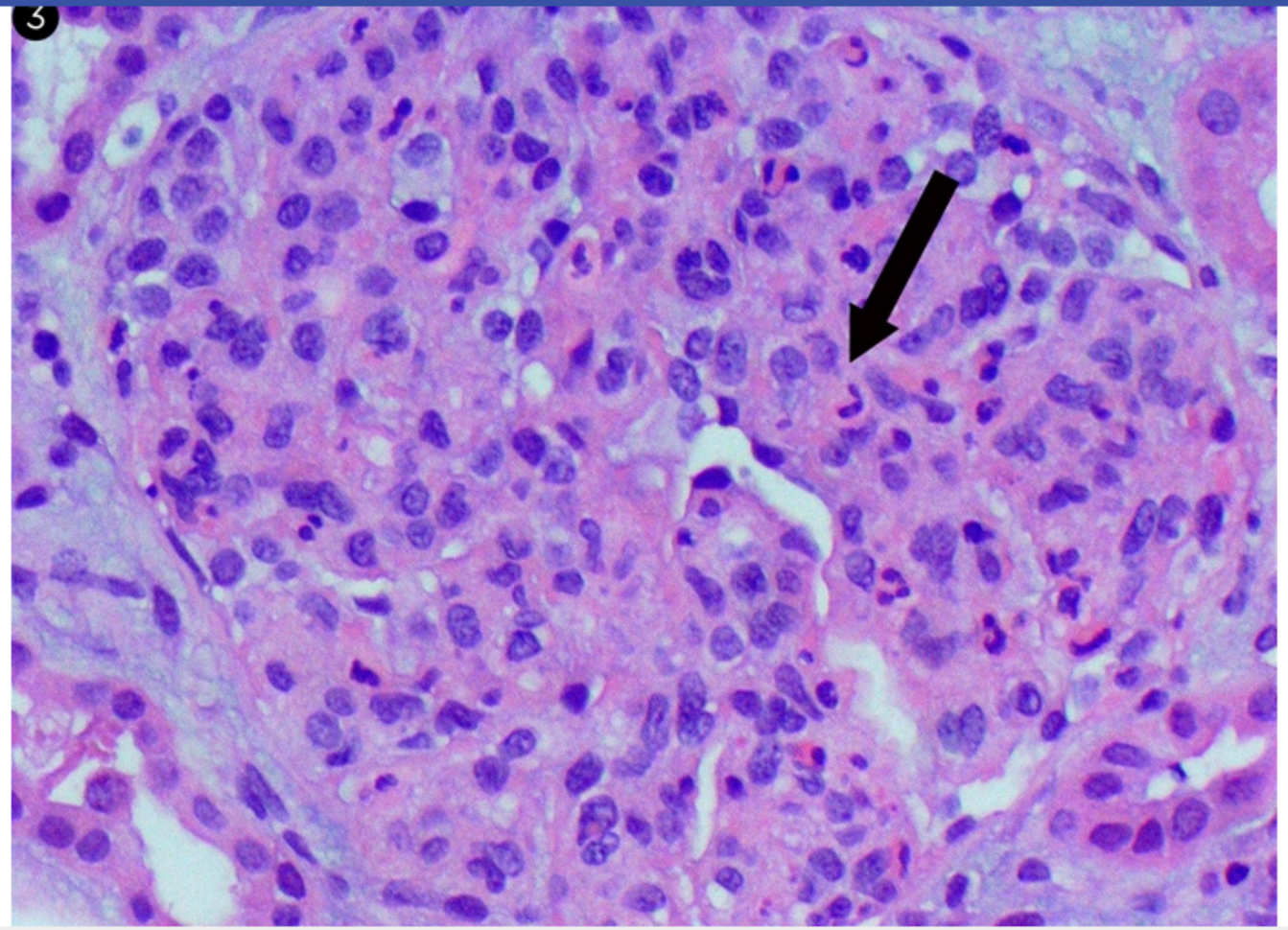


Zoom In | Zoom Out | Reset | Add To New Card | Existing Card

Pathology | Renal, Urinary Systems & Electrolytes | Diabetic nephropathy

**Block Time Remaining: 00:00:32**
TUTOR

10 | Feedback | Suspend | End Block

A 42-year-old man comes to the office due to hematuria, fatigue, and nasal congestion for the last few weeks. He has no chronic medical conditions. Blood pressure is 160/96 mm Hg. Physical examination shows edema around the ankles, hands, and face. Laboratory results reveal blood urea nitrogen of 40 mg/dL and serum creatinine of 3.8 mg/dL. Urinalysis shows moderate proteinuria and a large amount of red blood cells (RBCs) with RBC casts. A kidney biopsy is performed. Light microscopy reveals cellular proliferation, focal necrosis, and crescent formation of most of the glomeruli. On immunofluorescent microscopy, there are no immunoglobulin or complement deposits. Which of the following additional findings is most likely to be present in this patient?

- A. Decreased serum C3 level
- B. Decreased serum C4 level
- C. Serum antiglomerular basement membrane antibodies
- D. Serum antineutrophil cytoplasmic antibodies
- E. Serum antiphospholipid antibodies

Submit

A 42-year-old man comes to the office due to hematuria, fatigue, and nasal congestion for the last few weeks. He has no chronic medical conditions. Blood pressure is 160/96 mm Hg. Physical examination shows edema around the ankles, hands, and face. Laboratory results reveal blood urea nitrogen of 40 mg/dL and serum creatinine of 3.8 mg/dL. Urinalysis shows moderate proteinuria and a large amount of red blood cells (RBCs) with RBC casts. A kidney biopsy is performed. Light microscopy reveals cellular proliferation, focal necrosis, and crescent formation of most of the glomeruli. On immunofluorescent microscopy, there are no immunoglobulin or complement deposits. Which of the following additional findings is most likely to be present in this patient?

- A. Decreased serum C3 level (12%)
- B. Decreased serum C4 level (1%)
- C. Serum antiglomerular basement membrane antibodies (18%)
- ✓ D. Serum antineutrophil cytoplasmic antibodies (64%)
- E. Serum antiphospholipid antibodies (3%)

Omitted
Correct answer
D

64%
Answered correctly

03 mins, 55 secs
Time Spent

05/10/2020
Last Updated

## Explanation

**Crescent formation** on light microscopy is diagnostic of **rapidly progressive (crescentic) glomerulonephritis** (RPGN). This is a syndrome of severe glomerular injury that rapidly progresses to renal failure within weeks to months of onset. RPGN can be caused by several different diseases and is classified based on immunologic findings:

**Crescent formation** on light microscopy is diagnostic of **rapidly progressive (crescentic) glomerulonephritis** (RPGN). This is a syndrome of severe glomerular injury that rapidly progresses to renal failure within weeks to months of onset. RPGN can be caused by several different diseases and is classified based on immunologic findings:

- **Antiglomerular basement membrane (anti-GBM) RPGN:** Linear GBM deposits of IgG and C3 are found on immunofluorescence **(Choice C)**. In some patients, anti-GBM antibodies cross-react with pulmonary alveolar basement membranes, producing pulmonary hemorrhages (Goodpasture syndrome).
- **Immune-complex RPGN:** There is a "lumpy-bumpy" granular pattern of staining for both antibodies (eg, IgG, IgA) and complement on immunofluorescence microscopy. This can be a complication of poststreptococcal glomerulonephritis, systemic lupus erythematosus, IgA nephropathy, or Henoch-Schönlein purpura.
- **Pauci-immune RPGN:** There are **no immunoglobulin or complement deposits** on the basement membrane, as with this patient. Most patients have elevated serum titers of **antineutrophil cytoplasmic antibodies** (ANCA). This condition is often associated with vasculitides (eg, granulomatosis with polyangiitis, microscopic polyangiitis) but can also be idiopathic.

**(Choices A and B)** Serum C3 and C4 levels are usually normal with pauci-immune RPGN. Decreased serum C3 or C4 levels often occur in diseases with prominent immune complex formation, such as poststreptococcal glomerulonephritis, systemic lupus erythematosus (which causes immune-complex RPGN), and membranoproliferative glomerulonephritis.

**(Choice E)** Serum antiphospholipid antibodies are detected in patients with autoimmune disorders such as systemic lupus erythematosus and antiphospholipid syndrome. Antiphospholipid antibodies are associated with venous and arterial thrombosis, not crescent formation.

**Educational objective:**
Pauci-immune rapidly progressive glomerulonephritis frequently occurs as a manifestation of antineutrophil cytoplasmic antibodies (ANCA)-associated vasculitides (eg, granulomatosis with polyangiitis, microscopic polyangiitis). It is characterized by glomerular crescent formation without immunoglobulin or complement deposits.

Pathology | Renal, Urinary Systems & Electrolytes | Granulomatosis with polyangiitis

diseases and is classified based on immunologic findings:

- **Antiglomerular basement membrane (anti-GBM) RPGN:** Linear GBM deposits of IgG and C3 are found on immunofluorescence **(Choice C)**. In some patients, anti-GBM antibodies cross-react with pulmonary alveolar basement membranes, producing pulmonary hemorrhages (Goodpasture syndrome).
- **Immune-complex RPGN:** There is a "lumpy-bumpy" granular pattern of staining for both antibodies (eg, IgG, IgA) and complement on immunofluorescence microscopy. This can be a complication of poststreptococcal glomerulonephritis, systemic lupus erythematosus, IgA nephropathy, or Henoch-Schönlein purpura.
- **Pauci-immune RPGN:** There are **no immunoglobulin or complement deposits** on the basement membrane, as with this patient. Most patients have elevated serum titers of **antineutrophil cytoplasmic antibodies** (ANCA). This condition is often associated with vasculitides (eg, granulomatosis with polyangiitis, microscopic polyangiitis) but can also be idiopathic.

**(Choices A and B)** Serum C3 and C4 levels are usually normal with pauci-immune RPGN. Decreased serum C3 or C4 levels often occur in diseases with prominent immune complex formation, such as poststreptococcal glomerulonephritis, systemic lupus erythematosus (which causes immune-complex RPGN), and membranoproliferative glomerulonephritis.

**(Choice E)** Serum antiphospholipid antibodies are detected in patients with autoimmune disorders such as systemic lupus erythematosus and antiphospholipid syndrome. Antiphospholipid antibodies are associated with venous and arterial thrombosis, not crescent formation.

**Educational objective:**
Pauci-immune rapidly progressive glomerulonephritis frequently occurs as a manifestation of antineutrophil cytoplasmic antibodies (ANCA)-associated vasculitides (eg, granulomatosis with polyangiitis, microscopic polyangiitis). It is characterized by glomerular crescent formation without immunoglobulin or complement deposits.

| Pathology | Renal, Urinary Systems & Electrolytes | Granulomatosis with polyangiitis |
|---|---|---|
| Subject | System | Topic |

Copyright © UWorld. All rights reserved.

A 73-year-old man comes to the emergency department with unstable angina. He undergoes coronary angiography via the femoral approach. A stent is placed in the right coronary artery, and the patient is discharged. He returns to the emergency department 2 days later with blue discoloration of his right toe. He has pain and mild tingling in the affected toe. Medical history is significant for hyperlipidemia and coronary artery disease. On physical examination, the right toe appears cyanotic, and there is livedo reticularis affecting the right thigh. Peripheral pulses in the lower extremities are bilaterally palpable. Serum creatinine is 2.8 mg/dL (preoperatively it was 1.0 mg/dL). Which of the following histopathologic findings would most likely be seen on biopsy of this patient's kidney?

A. Cholesterol clefts in arterial lumen

B. Glomerular crescent formation

C. Hyperplastic arteriolar changes

D. Extensive necrosis of proximal tubular cells

E. Tubular obstruction with urate crystals

Submit

A 73-year-old man comes to the emergency department with unstable angina. He undergoes coronary angiography via the femoral approach. A stent is placed in the right coronary artery, and the patient is discharged. He returns to the emergency department 2 days later with blue discoloration of his right toe. He has pain and mild tingling in the affected toe. Medical history is significant for hyperlipidemia and coronary artery disease. On physical examination, the right toe appears cyanotic, and there is livedo reticularis affecting the right thigh. Peripheral pulses in the lower extremities are bilaterally palpable. Serum creatinine is 2.8 mg/dL (preoperatively it was 1.0 mg/dL). Which of the following histopathologic findings would most likely be seen on biopsy of this patient's kidney?

- ✓ A. Cholesterol clefts in arterial lumen (41%)
- B. Glomerular crescent formation (7%)
- C. Hyperplastic arteriolar changes (9%)
- D. Extensive necrosis of proximal tubular cells (33%)
- E. Tubular obstruction with urate crystals (7%)

Omitted
Correct answer
A

41%
Answered correctly

01 sec
Time Spent

05/01/2020
Last Updated

Explanation

**Sequelae of atheroembolic disease**

Stroke

Settings

1 2 3 4 5 6 7 8 9 10 11 12 13 14 15 16 17 18 19 20 21 22 23 24 25 26 27 28 29 30

Item 5 of 39
Question Id: 810

Mark | Previous | Next | Full Screen | Tutorial | Lab Values | Notes | Calculator | Reverse Color | Text Zoom | Settings

## Sequelae of atheroembolic disease

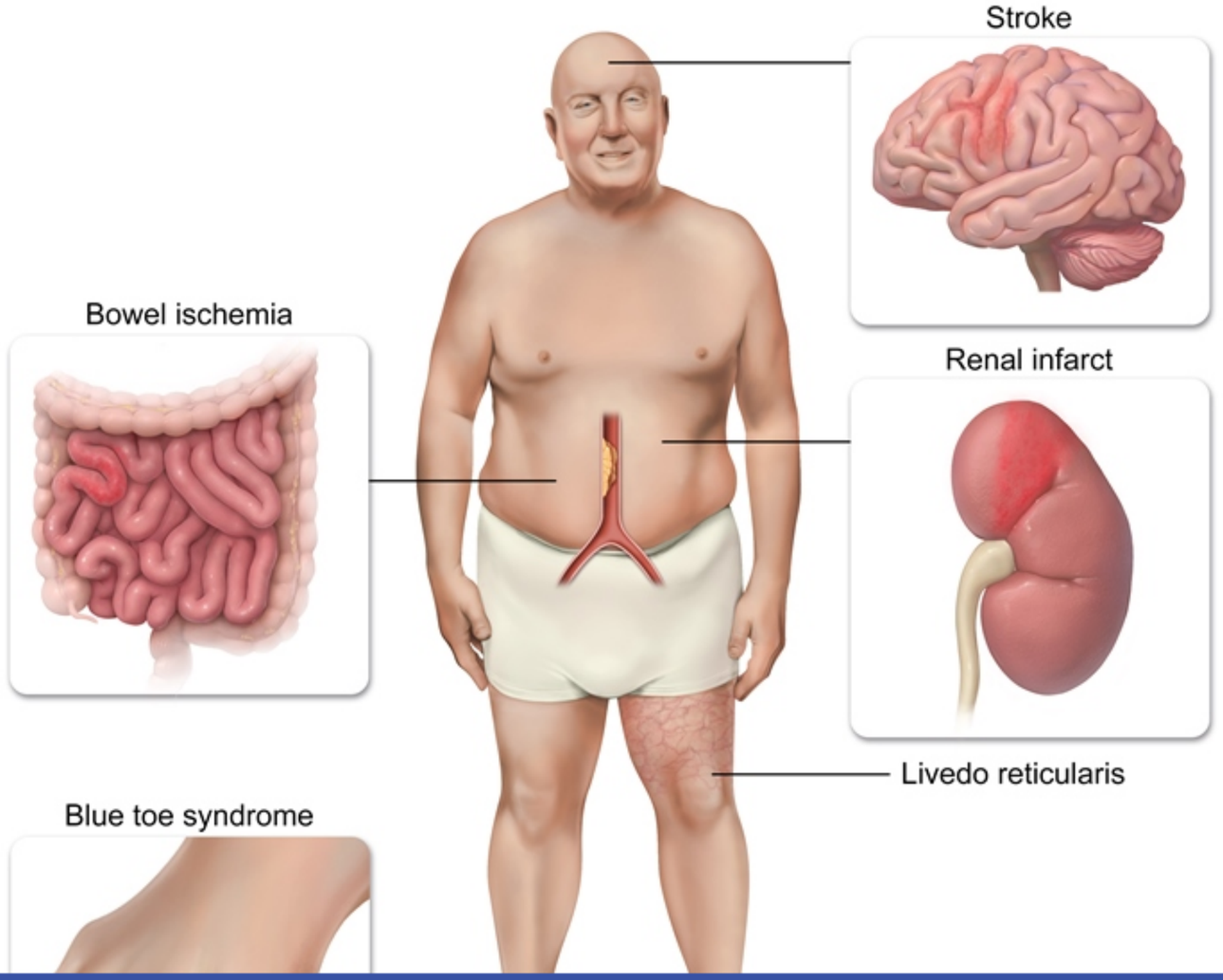


Block Time Remaining: 00:04:28
TUTOR

4 | Feedback | Suspend | End Block

This patient has livedo reticularis, a blue toe, and acute kidney injury following coronary angiography; this presentation is concerning for **atheroembolic disease**. Invasive **vascular procedures** (eg, angiography, angioplasty, aortic surgery) can cause cholesterol-containing debris from atherosclerotic plaques to become dislodged from large arteries (eg, the aorta during cardiac catheterization) and shower microemboli into the circulation. These lodge in small, distal arterioles, resulting in ischemia of the corresponding organs and tissues; symptoms develop within a few days or weeks after the procedure. Skin findings (eg, livedo reticularis, blue toe syndrome) are the most common presenting signs. Pulses typically remain palpable as larger arteries are unaffected.

Signs of **acute kidney injury** (eg, oliguria, azotemia) are common in the setting of postprocedure atheroembolism and are frequently seen in elderly patients with preexisting renal atherosclerosis. Frank infarction with flank pain and hematuria does not occur due to the small size of the emboli. Cholesterol is dissolved during tissue preparation for microscopic evaluation, leaving the **needle-shaped clefts** that partially or completely obstruct the arcuate or interlobular renal arteries. Other organs that may be involved are the gastrointestinal tract and the CNS, including the retinal vessels.

**(Choice B)** Glomerular crescent formation is characteristic of rapidly progressive glomerulonephritis (RPGN). All forms of RPGN have an insidious onset with hematuria, hypertension, and edema.

**(Choice C)** Hyperplastic arteriolar changes (intimal fibroelastosis) are diagnostic of hypertensive nephropathy seen in patients with poorly controlled hypertension.

**(Choice D)** Atheroemboli only partially occlude the renal vessels, therefore acute tubular necrosis (ATN) does not typically occur early in the

emboli. Cholesterol is dissolved during tissue preparation for microscopic evaluation, leaving the **needle-shaped clefts** that partially or completely obstruct the arcuate or interlobular renal arteries. Other organs that may be involved are the gastrointestinal tract and the CNS, including the retinal vessels.

**(Choice B)** Glomerular crescent formation is characteristic of rapidly progressive glomerulonephritis (RPGN). All forms of RPGN have an insidious onset with hematuria, hypertension, and edema.

**(Choice C)** Hyperplastic arteriolar changes (intimal fibroelastosis) are diagnostic of hypertensive nephropathy seen in patients with poorly controlled hypertension.

**(Choice D)** Atheroemboli only partially occlude the renal vessels, therefore acute tubular necrosis (ATN) does not typically occur early in the disease process. Complete vessel occlusion with resultant ATN can occur later (weeks to months) due to an endothelial inflammatory response. However, as opposed to toxin-induced ATN (eg, aminoglycosides), which causes diffuse, extensive proximal tubular injury, ischemic ATN typically causes patchy necrosis of the proximal tubules.

**(Choice E)** Urate nephropathy due to tubular obstruction from urate crystal deposition is usually seen in individuals with acute hyperuricemia (eg, tumor lysis syndrome). The classic presentation is acute renal failure during chemotherapy for a malignancy.

**Educational objective:**
Invasive vascular procedures can be complicated by atheroembolic disease, which may involve the kidneys, gastrointestinal tract, CNS, and the skin. Light microscopy shows a partially or completely obstructed arterial lumen with needle-shaped cholesterol clefts within the atheromatous embolus.

**References**

- Atheroembolic kidney disease.

| Pathology | Renal, Urinary Systems & Electrolytes | Atheroembolism |
|---|---|---|
| Subject | System | Topic |

Copyright © UWorld. All rights reserved.

A 44-year-old woman comes to the emergency department due to acute-onset, severe, right lower quadrant abdominal pain, nausea, vomiting, and hematuria over the last 4 hours. She had a similar episode of acute pain a year ago, but it resolved in a few hours and she did not seek medical intervention. The patient has no other medical conditions and takes no medication. She smokes a pack of cigarettes daily. She is sexually active and has never been pregnant. Temperature is 36.9 C (98.4 F), blood pressure is 140/90 mm Hg, and pulse is 102/min. There is mild tenderness to deep palpation in the right lower quadrant. Laboratory results are as follows:

Serum chemistry

| | |
|---|---|
| Urea nitrogen | 15 mg/dL |
| Creatinine | 1.0 mg/dL |
| Glucose | 90 mg/dL |
| Calcium | 11 mg/dL |
| Phosphorus | 2.5 mg/dL |

Which of the following is the most likely cause of this patient's current condition?

A. Appendicitis
B. Diverticulitis
C. Glomerulonephritis
D. Ovarian torsion
E. Renal cell carcinoma
F. Renal infarction
G. Ureterolithiasis

1 2 3 4 5 6 7 8 9 10 11 12 13 14 15 16 17 18 19 20 21 22 23 24 25 26 27 28 29 30

mild tenderness to deep palpation in the right lower quadrant. Laboratory results are as follows:

Serum chemistry

| | |
|---|---|
| Urea nitrogen | 15 mg/dL |
| Creatinine | 1.0 mg/dL |
| Glucose | 90 mg/dL |
| Calcium | 11 mg/dL |
| Phosphorus | 2.5 mg/dL |

Which of the following is the most likely cause of this patient's current condition?

- A. Appendicitis
- B. Diverticulitis
- C. Glomerulonephritis
- D. Ovarian torsion
- E. Renal cell carcinoma
- F. Renal infarction
- G. Ureterolithiasis

Submit

1 2 3 4 5 6 7 8 9 10 11 12 13 14 15 16 17 18 19 20 21 22 23 24 25 26 27 28 29 30

mild tenderness to deep palpation in the right lower quadrant. Laboratory results are as follows:

Serum chemistry

| | |
|---|---|
| Urea nitrogen | 15 mg/dL |
| Creatinine | 1.0 mg/dL |
| Glucose | 90 mg/dL |
| Calcium | 11 mg/dL |
| Phosphorus | 2.5 mg/dL |

Which of the following is the most likely cause of this patient's current condition?

- A. Appendicitis (3%)
- B. Diverticulitis (1%)
- C. Glomerulonephritis (1%)
- D. Ovarian torsion (5%)
- E. Renal cell carcinoma (9%)
- F. Renal infarction (3%)
- ✓ G. Ureterolithiasis (74%)

Omitted
Correct answer

74%
Answered correctly

03 secs
Time Spent

02/05/2020
Last Updated

| Risk & prevention of kidney stones | | |
|---|---|---|
| **Stone type** | **Risk factors** | **Prevention** |
| **Calcium stones (oxalate, phosphate)** | • Hypercalciuria (eg, hyperparathyroidism)<br>• Hyperoxaluria (eg, malabsorption, low-calcium diet)<br>• Hypocitraturia (eg, distal RTA)<br>• Diet: ↑ sodium, ↑ protein, ↑ oxalate, ↓ calcium | • Reduce sodium, animal protein, oxalate intake<br>• Increase potassium intake; moderate calcium intake<br>• Thiazide diuretics |
| **Uric acid** | • Gout<br>• Myeloproliferative disorders | • Urine alkalinization<br>• Allopurinol |
| **Magnesium ammonium phosphate (struvite)** | • Recurrent upper urinary infection (eg, *Klebsiella*, *Proteus*) | • Stone removal<br>• Suppressive antibiotics |
| **All types** | • Dehydration | • Increase fluid intake |

**RTA** = renal tubular acidosis.

This patient has recurrent **abdominal pain**, vomiting, and **hematuria**. In conjunction with hypercalcemia and hypophosphatemia, this presentation suggests **ureterolithiasis** due to hyperparathyroidism. Most kidney stones are made up of calcium salts and are idiopathic, but conditions that increase calcium excretion increase the risk of stone formation. Primary hyperparathyroidism leads to increased bone resorption, decreased urinary phosphate reabsorption, and increased 1,25-dihydroxyvitamin D formation, all of which result in **hypercalcemia** and **hypophosphatemia**. Despite the increased fractional reabsorption of calcium induced by PTH, net urinary **calcium excretion is elevated** due to the increased filtered calcium load, raising the risk for stone formation.

Pain from ureterolithiasis, which occurs when the stone obstructs renal drainage, typically waxes and wanes. Obstruction at the ureteropelvic junction normally presents with flank or upper abdominal pain, whereas an obstructing stone at the ureterovesical junction usually presents with

This patient has recurrent **abdominal pain**, vomiting, and **hematuria**. In conjunction with hypercalcemia and hypophosphatemia, this presentation suggests **ureterolithiasis** due to hyperparathyroidism. Most kidney stones are made up of calcium salts and are idiopathic, but conditions that increase calcium excretion increase the risk of stone formation. Primary hyperparathyroidism leads to increased bone resorption, decreased urinary phosphate reabsorption, and increased 1,25-dihydroxyvitamin D formation, all of which result in **hypercalcemia** and **hypophosphatemia**. Despite the increased fractional reabsorption of calcium induced by PTH, net urinary **calcium excretion is elevated** due to the increased filtered calcium load, raising the risk for stone formation.

Pain from ureterolithiasis, which occurs when the stone obstructs renal drainage, typically waxes and wanes. Obstruction at the ureteropelvic junction normally presents with flank or upper abdominal pain, whereas an obstructing stone at the ureterovesical junction usually presents with lower abdominal or groin pain. Other common symptoms include hematuria, nausea, and vomiting.

**(Choices A and B)** Appendicitis presents with acute periumbilical or right lower quadrant pain and tenderness, but it would not usually cause recurrent symptoms. Acute diverticulitis can cause recurrent lower abdominal symptoms but is much more common on the left and typically occurs in older (age >60) patients. Neither of these conditions are associated with hematuria or hypercalcemia.

**(Choice C)** Glomerulonephritis is a category of kidney disorders characterized by hematuria, typically with red cell casts. Common associated features include hypertension, oliguria, and acute renal failure. Patients with various nephritic syndromes may have moderate flank pain, but acute, severe lower abdominal pain is not consistent with glomerulonephritis.

**(Choice D)** Ovarian torsion can present with acute, severe lower abdominal or pelvic pain. It can be recurrent but would not cause hematuria.

**(Choice E)** Renal cell cancer can cause hematuria and hypercalcemia; however, pain (if present) typically presents in the flank rather than the lower abdomen.

**(Choice F)** Renal infarction typically occurs due to acute obstruction of the renal arteries (eg, cardiac thromboembolism, aortic dissection). Patients often develop abdominal pain and hematuria but also typically have fever and marked hypertension (due to renin release). In addition, renal infarction is not associated with hypercalcemia or hypophosphatemia.

**Educational objective:**
Most kidney stones are made of calcium salts and are idiopathic, but conditions that increase renal calcium excretion can increase the risk of

lower abdominal or groin pain. Other common symptoms include hematuria, nausea, and vomiting.

**(Choices A and B)** Appendicitis presents with acute periumbilical or right lower quadrant pain and tenderness, but it would not usually cause recurrent symptoms. Acute diverticulitis can cause recurrent lower abdominal symptoms but is much more common on the left and typically occurs in older (age >60) patients. Neither of these conditions are associated with hematuria or hypercalcemia.

**(Choice C)** Glomerulonephritis is a category of kidney disorders characterized by hematuria, typically with red cell casts. Common associated features include hypertension, oliguria, and acute renal failure. Patients with various nephritic syndromes may have moderate flank pain, but acute, severe lower abdominal pain is not consistent with glomerulonephritis.

**(Choice D)** Ovarian torsion can present with acute, severe lower abdominal or pelvic pain. It can be recurrent but would not cause hematuria.

**(Choice E)** Renal cell cancer can cause hematuria and hypercalcemia; however, pain (if present) typically presents in the flank rather than the lower abdomen.

**(Choice F)** Renal infarction typically occurs due to acute obstruction of the renal arteries (eg, cardiac thromboembolism, aortic dissection). Patients often develop abdominal pain and hematuria but also typically have fever and marked hypertension (due to renin release). In addition, renal infarction is not associated with hypercalcemia or hypophosphatemia.

**Educational objective:**
Most kidney stones are made of calcium salts and are idiopathic, but conditions that increase renal calcium excretion can increase the risk of stones. Hyperparathyroidism is a common cause of recurrent kidney stones and is typically associated with mild hypercalcemia and hypophosphatemia.

**References**

- Renal stones and calcifications in patients with primary hyperparathyroidism: associations with biochemical variables.

| Pathology | Renal, Urinary Systems & Electrolytes | Hyperparathyroidism |
|---|---|---|
| Subject | System | Topic |

Copyright © UWorld. All rights reserved.

| | | |
|---|---|---|
| | • Gout | • Urine alkalinization |

## Exhibit Display

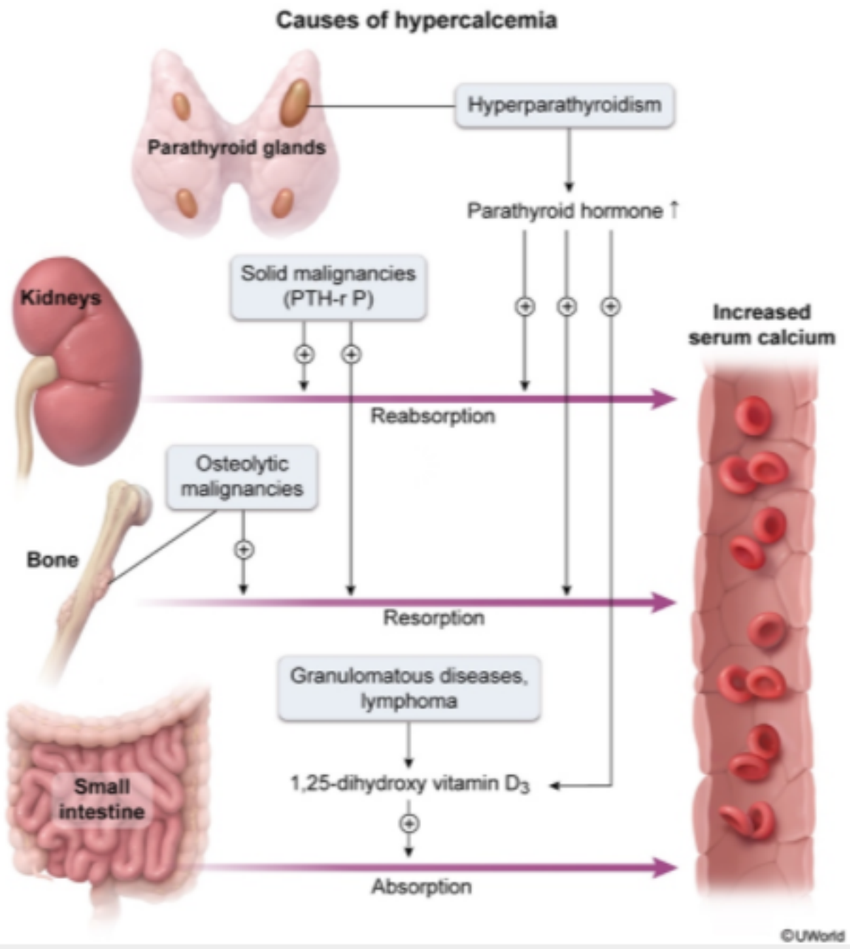


Zoom In | Zoom Out | Reset | Add To New Card | Existing Card

| | | |
|---|---|---|
| | • Gout | • Urine alkalinization |

## Exhibit Display

**Likely locations of ureteral obstruction**

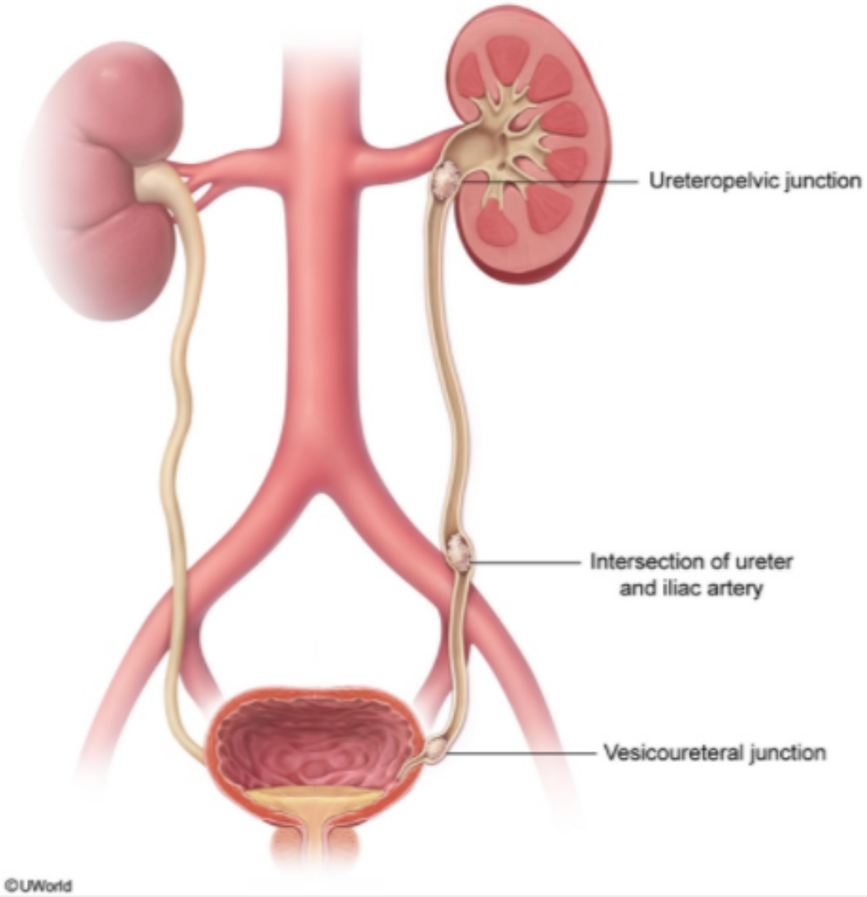


Zoom In | Zoom Out | Reset | Add To New Card | Existing Card

A 72-year-old man comes to the emergency department due to sudden-onset, severe abdominal pain accompanied by nausea. He has a history of coronary artery disease and recently underwent cardiac angiography. The patient is a current smoker with a 30-pack-year history. After initial evaluation, he undergoes emergency laparotomy. A segment of small intestine is resected. On microscopic examination, there are several large-caliber vessels with needle-shaped cholesterol clefts in their lumens, as shown in the image below.

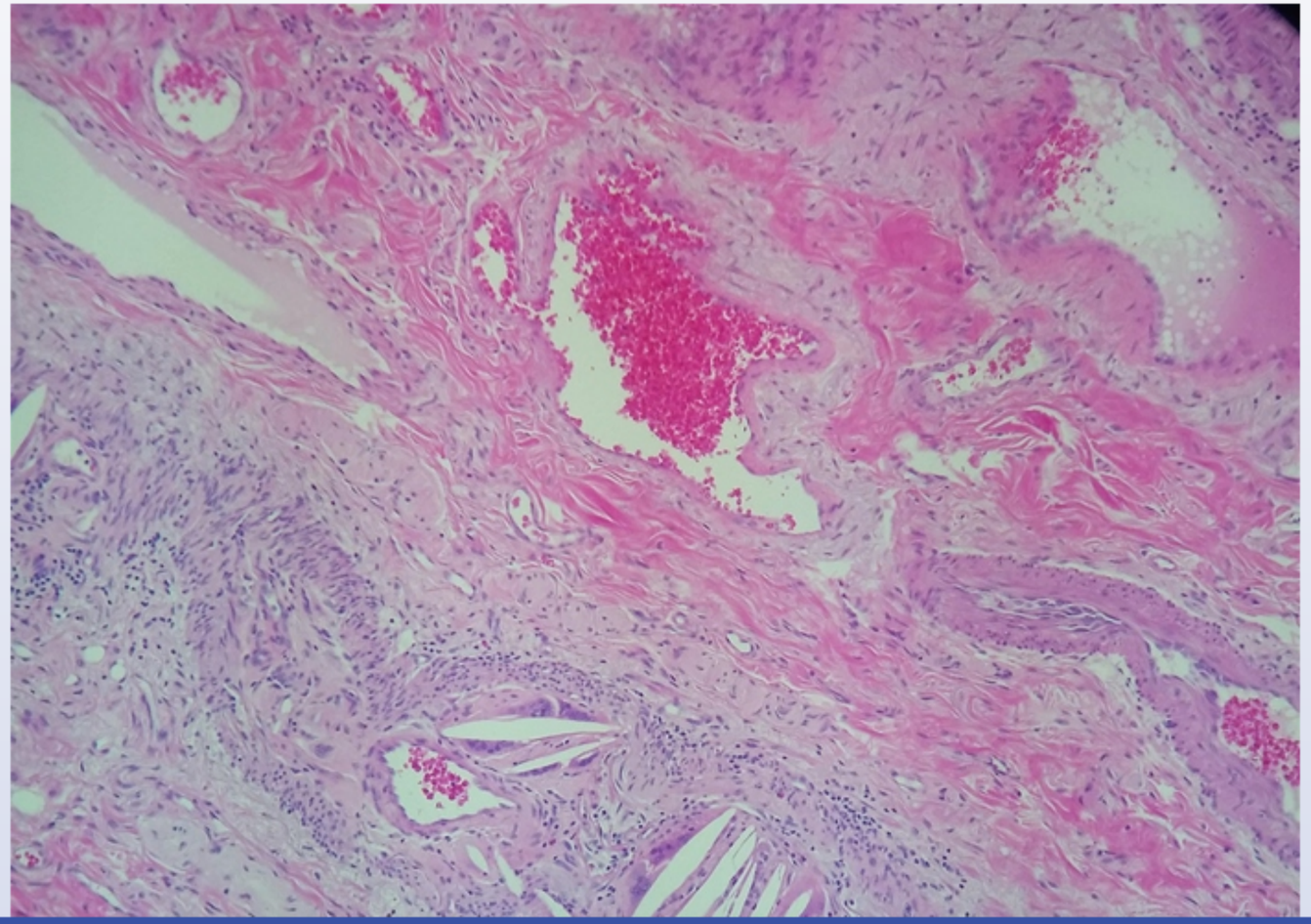

Settings

1
2
3
4
5
6
7
8
9
10
11
12
13
14
15
16
17
18
19
20
21
22
23
24
25
26
27
28
29
30

Item 7 of 39
Question Id: 15250

Mark | Previous | Next | Full Screen | Tutorial | Lab Values | Notes | Calculator | Reverse Color | Text Zoom | Settings

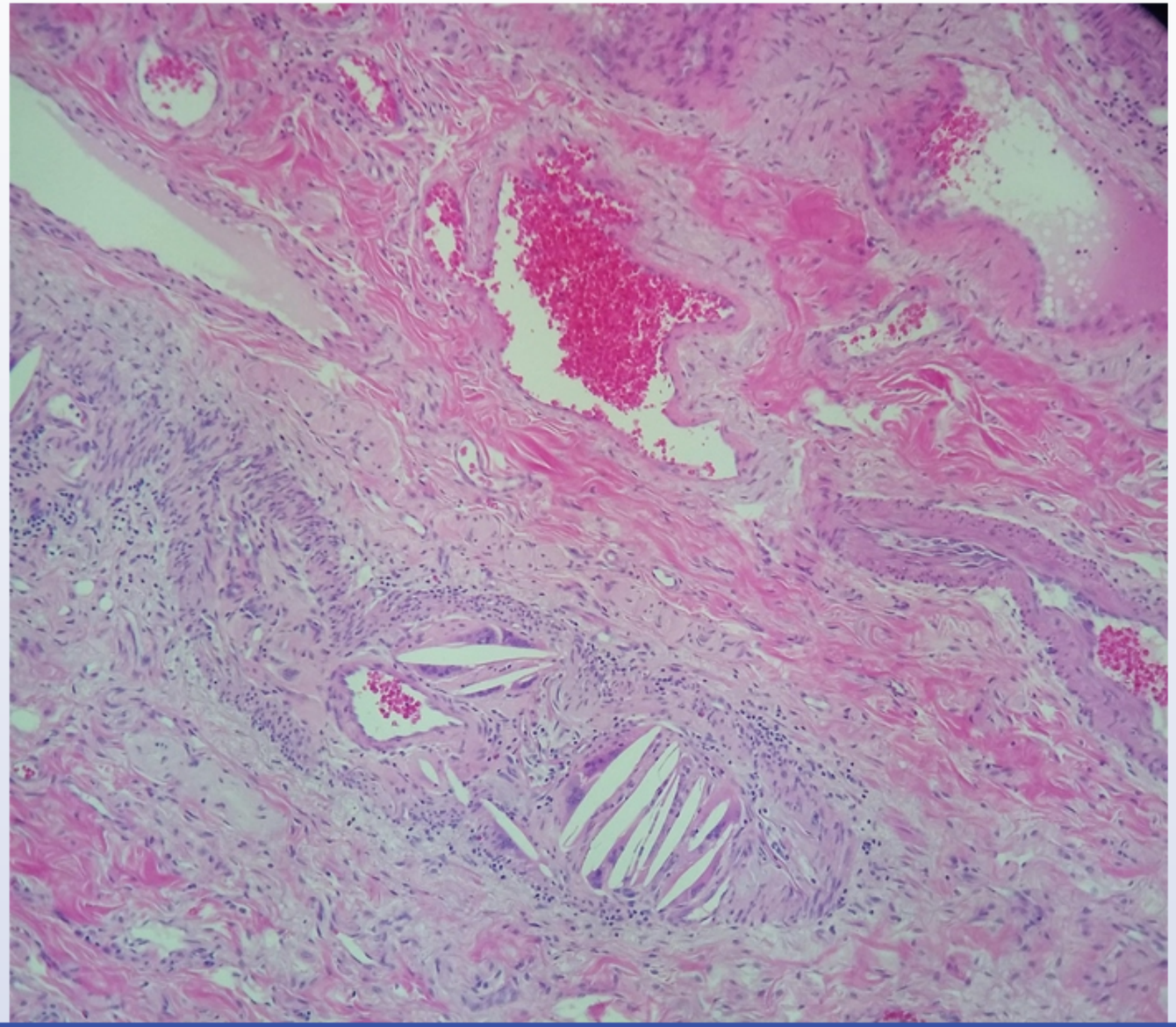

Block Time Remaining: 00:04:34
TUTOR

2 | Feedback | Suspend | End Block

Settings

1 2 3 4 5 6 7 8 9 10 11 12 13 14 15 16 17 18 19 20 21 22 23 24 25 26 27 28 29 30

Item 7 of 39
Question Id: 15250

Mark | Previous | Next | Full Screen | Tutorial | Lab Values | Notes | Calculator | Reverse Color | Text Zoom | Settings

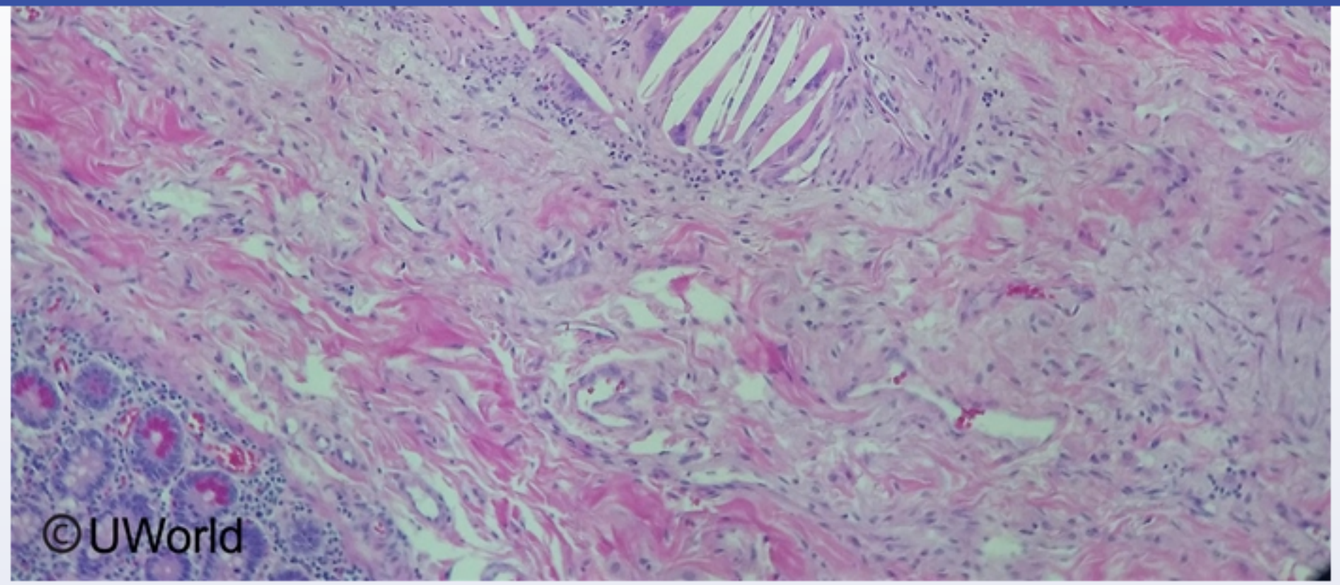


Given these findings, the patient is at highest risk for which of the following complications?

- A. Kidney injury
- B. Myelosuppression
- C. Nephrolithiasis
- D. Pulmonary infarction
- E. Septic arthritis

Submit

Block Time Remaining: 00:04:36
TUTOR

2 | Feedback | Suspend | End Block

1 2 3 4 5 6 7 8 9 10 11 12 13 14 15 16 17 18 19 20 21 22 23 24 25 26 27 28 29 30

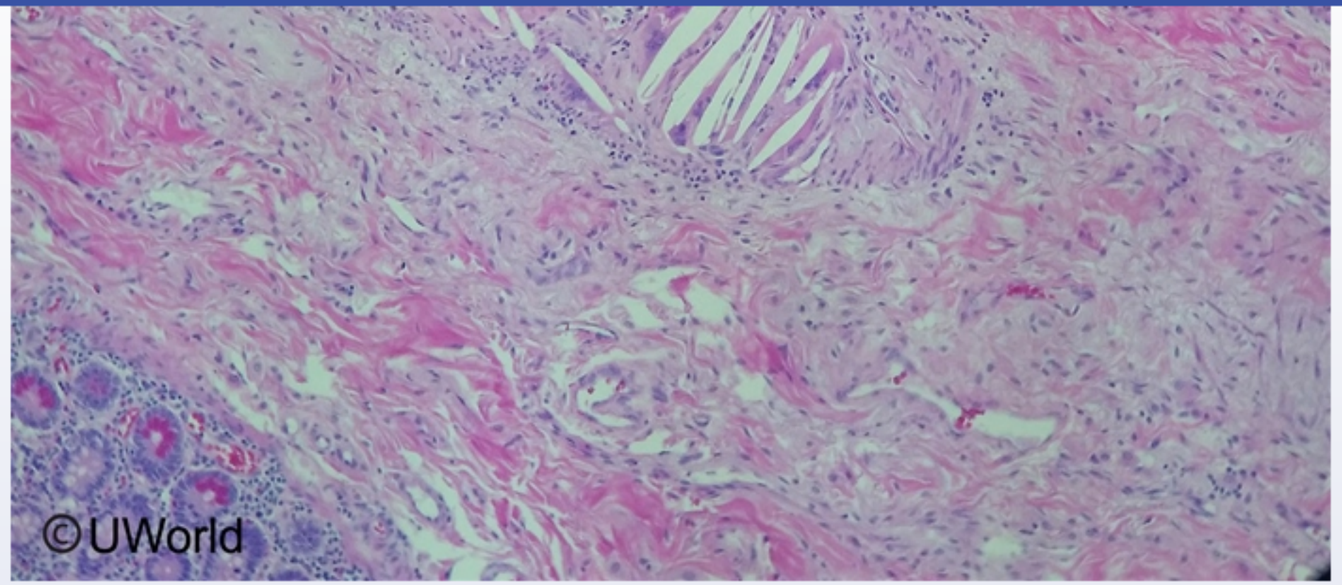


Given these findings, the patient is at highest risk for which of the following complications?

- ✓ A. Kidney injury (65%)
- B. Myelosuppression (0%)
- C. Nephrolithiasis (9%)
- D. Pulmonary infarction (23%)
- E. Septic arthritis (1%)

Omitted
Correct answer

65%
Answered correctly

06 secs
Time Spent

01/28/2020
Last Updated

Settings

1
2
3
4
5
6
7
8
9
10
11
12
13
14
15
16
17
18
19
20
21
22
23
24
25
26
27
28
29
30

Item 7 of 39
Question Id: 15250

Mark | Previous | Next | Full Screen | Tutorial | Lab Values | Notes | Calculator | Reverse Color | Text Zoom | Settings

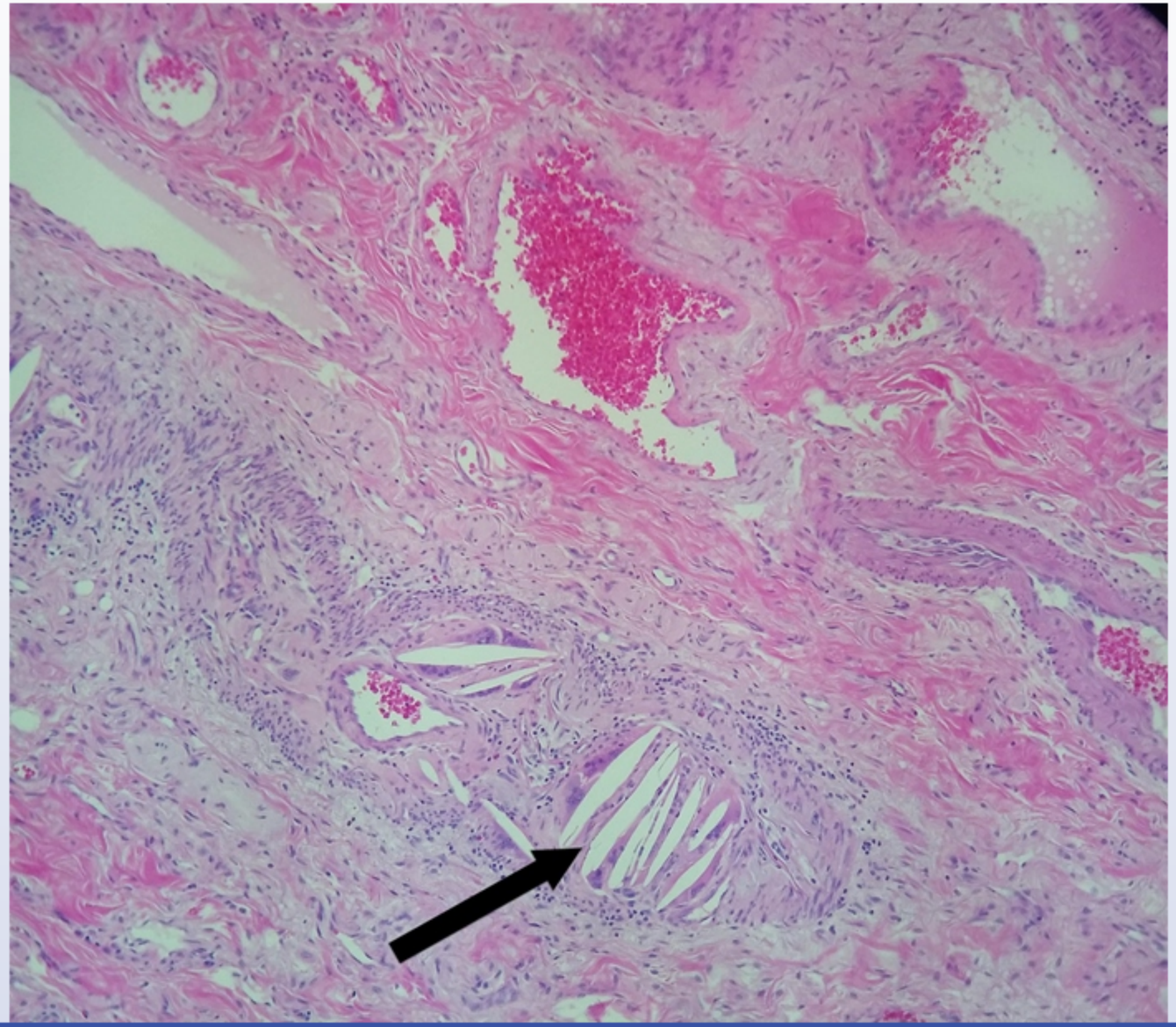

Block Time Remaining: 00:04:37
TUTOR

2 | Feedback | Suspend | End Block

This patient developed acute abdominal pain after recent coronary angiography. Small bowel histology demonstrates **needle-shaped intravascular cholesterol clefts**, a characteristic finding in **atheroembolic disease** (ie, cholesterol crystal embolism). Cholesterol is dissolved during tissue processing, leaving empty clefts on histologic evaluation. Atheroembolic disease typically occurs after an **invasive vascular procedure** (eg, coronary angiography, aortic surgery) in which atherosclerotic plaques on large vessels (eg, aorta) are mechanically dislodged. This leads to showering of cholesterol-rich microemboli into the circulation with resultant obstruction of distal arterioles and tissue ischemia.

Clinical manifestations depend on the location of the embolic scatter. Patients frequently **develop acute kidney injury** due to partial or complete occlusion of the arcuate or interlobular arteries. Other commonly involved organ systems include the skin (eg, blue toe syndrome, livedo reticularis), the gastrointestinal tract (eg, bleeding; intestinal infarction, as in this patient), and the CNS (eg, stroke, amaurosis fugax).

**(Choice B)** Heparin anticoagulants given during angiography can cause heparin-induced thrombocytopenia (HIT), which typically presents with low platelet counts and thrombotic complications. However, the destruction of platelets in HIT is due to immune-mediated platelet aggregation, rather than bone marrow suppression.

**(Choice C)** Gout causes needle-shaped crystals seen on microscopy. However, uric acid crystals are negatively birefringent (not empty clefts) and are located within tophi or synovial fluid. In addition, gout does not cause embolic disease.

**(Choice D)** Pulmonary infarction can also occur in atheroembolic disease; however, this is an extremely rare manifestation and occurs much less commonly than acute kidney injury.

**(Choice E)** Infectious endocarditis also causes embolic showering and can cause both small bowel involvement and septic arthritis. However, endocarditis is more common in drug users, and patients typically develop fever, arthralgias, and night sweats. In addition, bacteria, not cholesterol clefts, would be visualized on microscopic examination.

**Educational objective:**
Atheroembolic disease typically occurs after an invasive vascular procedure due to mechanical dislodgement of atherosclerotic plaque, resulting in the showering of cholesterol-rich microemboli into the circulation. Needle-shaped cholesterol clefts in affected vessels are diagnostic. Commonly involved organs include the kidneys (eg, acute kidney injury), skin (eg, blue toe syndrome, livedo reticularis), gastrointestinal tract (eg, bleeding, infarction), and CNS (eg, stroke, amaurosis fugax).

This leads to showering of cholesterol-rich microemboli into the circulation with resultant obstruction of distal arterioles and tissue ischemia.

Clinical manifestations depend on the location of the embolic scatter. Patients frequently **develop acute kidney injury** due to partial or complete occlusion of the arcuate or interlobular arteries. Other commonly involved organ systems include the skin (eg, blue toe syndrome, livedo reticularis), the gastrointestinal tract (eg, bleeding; intestinal infarction, as in this patient), and the CNS (eg, stroke, amaurosis fugax).

**(Choice B)** Heparin anticoagulants given during angiography can cause heparin-induced thrombocytopenia (HIT), which typically presents with low platelet counts and thrombotic complications. However, the destruction of platelets in HIT is due to immune-mediated platelet aggregation, rather than bone marrow suppression.

**(Choice C)** Gout causes needle-shaped crystals seen on microscopy. However, uric acid crystals are negatively birefringent (not empty clefts) and are located within tophi or synovial fluid. In addition, gout does not cause embolic disease.

**(Choice D)** Pulmonary infarction can also occur in atheroembolic disease; however, this is an extremely rare manifestation and occurs much less commonly than acute kidney injury.

**(Choice E)** Infectious endocarditis also causes embolic showering and can cause both small bowel involvement and septic arthritis. However, endocarditis is more common in drug users, and patients typically develop fever, arthralgias, and night sweats. In addition, bacteria, not cholesterol clefts, would be visualized on microscopic examination.

**Educational objective:**
Atheroembolic disease typically occurs after an invasive vascular procedure due to mechanical dislodgement of atherosclerotic plaque, resulting in the showering of cholesterol-rich microemboli into the circulation. Needle-shaped cholesterol clefts in affected vessels are diagnostic. Commonly involved organs include the kidneys (eg, acute kidney injury), skin (eg, blue toe syndrome, livedo reticularis), gastrointestinal tract (eg, bleeding, infarction), and CNS (eg, stroke, amaurosis fugax).

| Pathology | Renal, Urinary Systems & Electrolytes | Atheroembolism |
|---|---|---|
| Subject | System | Topic |

Copyright © UWorld. All rights reserved.

A 38-year-old man comes to the emergency department because he has been vomiting blood. After appropriate resuscitation measures, he undergoes upper gastrointestinal endoscopy, which reveals a bleeding duodenal ulcer. During hospital day 2, the patient develops decreased urine output. Serum creatinine rises to 3.0 mg/dL from a baseline of 1.2 mg/dL. Renal biopsy shows patchy epithelial necrosis of the tubules, tubulorrhexis, and intratubular casts. On hospital day 8, urine output significantly increases and serum creatinine levels decline. Over the next few days, this patient is at highest risk for which of the following complications?

- A. Hyperphosphatemia
- B. Hypokalemia
- C. Metabolic acidosis
- D. Urinary protein loss
- E. Volume overload

Submit

A 38-year-old man comes to the emergency department because he has been vomiting blood. After appropriate resuscitation measures, he undergoes upper gastrointestinal endoscopy, which reveals a bleeding duodenal ulcer. During hospital day 2, the patient develops decreased urine output. Serum creatinine rises to 3.0 mg/dL from a baseline of 1.2 mg/dL. Renal biopsy shows patchy epithelial necrosis of the tubules, tubulorrhexis, and intratubular casts. On hospital day 8, urine output significantly increases and serum creatinine levels decline. Over the next few days, this patient is at highest risk for which of the following complications?

A. Hyperphosphatemia (6%)
✓ B. Hypokalemia (63%)
C. Metabolic acidosis (15%)
D. Urinary protein loss (11%)
E. Volume overload (2%)

Omitted
Correct answer
B

63%
Answered correctly

02 secs
Time Spent

01/27/2020
Last Updated

Explanation

| Stages of acute tubular necrosis | |
|---|---|
| **Initiation stage**<br>(24-36 hours) | • Tubular injury resulting from:<br>◦ Ischemia (eg, hemorrhage, acute MI, sepsis, shock) |

| Stages of acute tubular necrosis | |
|---|---|
| **Initiation stage**<br>(24-36 hours) | • Tubular injury resulting from:<br>◦ Ischemia (eg, hemorrhage, acute MI, sepsis, shock)<br>◦ Cytotoxins (eg, radiologic contrast agents, aminoglycosides, myoglobin) |
| **Maintenance stage**<br>(1-3 weeks) | • Oliguric renal failure (↓ GFR, ↓ urine output, fluid overload)<br>• ↑ Creatinine/BUN, ↑ potassium, metabolic acidosis |
| **Recovery phase**<br>(months) | • Gradual increase in urine output, leading to high-volume diuresis<br>• Continued impairment of renal tubular function, resulting in electrolyte wasting (↓↓ potassium, magnesium, phosphorus, calcium) |
| **BUN** = blood urea nitrogen; **GFR** = glomerular filtration rate; **MI** = myocardial infarction. | |

This patient developed acute renal failure after gastrointestinal hemorrhage; renal biopsy showing epithelial necrosis of the tubules, tubulorrhexis, and intratubular casts is consistent with **acute tubular necrosis** (ATN). ATN is characterized by tubular injury due to renal ischemia (eg, shock, hemorrhage) or direct cytotoxicity (eg, radiologic contrast agents, aminoglycosides).

The clinical course of ATN can be broken into 3 stages. The **initiation** stage is marked by the inciting event (eg, hemorrhage, as in this patient) and the onset of tubular injury. If significant tubular damage occurs, the **maintenance** stage (oliguric stage) follows in 24-36 hours. During this stage, **urine output decreases** and patients may develop volume overload. Renal tubular dysfunction results in the characteristic low urinary osmolality (<350 mOsm/kg), high urinary sodium (>30 mEq/L), and high urinary fractional sodium excretion (>1%).

In spite of the seemingly profound damage that occurs to nephrons in ATN, tubular epithelial cells have excellent regenerative capacity. If the patient survives the maintenance stage (by conservative management or dialysis), the **recovery** stage follows in 1-3 weeks. Glomerular filtration rate often improves before renal tubular function is restored, so patients can develop **transient polyuria** (sometimes >3 L/day) with significant **electrolyte wasting** because tubular resorptive capacity remains impaired. During this time, patients are at high risk of developing clinically significant electrolyte imbalances, particularly **hypokalemia**, which can be life-threatening. Serum concentrations of magnesium, phosphorus, and calcium may also be low. Most patients recover completely, depending on the magnitude of the initial injury.

This patient developed acute renal failure after gastrointestinal hemorrhage; renal biopsy showing epithelial necrosis of the tubules, tubulorrhexis, and intratubular casts is consistent with **acute tubular necrosis** (ATN). ATN is characterized by tubular injury due to renal ischemia (eg, shock, hemorrhage) or direct cytotoxicity (eg, radiologic contrast agents, aminoglycosides).

The clinical course of ATN can be broken into 3 stages. The **initiation** stage is marked by the inciting event (eg, hemorrhage, as in this patient) and the onset of tubular injury. If significant tubular damage occurs, the **maintenance** stage (oliguric stage) follows in 24-36 hours. During this stage, **urine output decreases** and patients may develop volume overload. Renal tubular dysfunction results in the characteristic low urinary osmolality (<350 mOsm/kg), high urinary sodium (>30 mEq/L), and high urinary fractional sodium excretion (>1%).

In spite of the seemingly profound damage that occurs to nephrons in ATN, tubular epithelial cells have excellent regenerative capacity. If the patient survives the maintenance stage (by conservative management or dialysis), the **recovery** stage follows in 1-3 weeks. Glomerular filtration rate often improves before renal tubular function is restored, so patients can develop **transient polyuria** (sometimes >3 L/day) with significant **electrolyte wasting** because tubular resorptive capacity remains impaired. During this time, patients are at high risk of developing clinically significant electrolyte imbalances, particularly **hypokalemia**, which can be life-threatening. Serum concentrations of magnesium, phosphorus, and calcium may also be low. Most patients recover completely, depending on the magnitude of the initial injury.

**(Choices A, C, and E)** Hyperphosphatemia, anion gap metabolic acidosis, and volume overload occur in the maintenance stage of ATN. This patient's spontaneous diuresis and falling creatinine are more consistent with the recovery phase.

**(Choice D)** Protein-losing nephropathies (eg, nephrotic syndrome) occur due to significant glomerular damage. Because the destruction in ATN is largely tubular, protein loss is unexpected. Patients with nephrotic syndrome typically develop progressive renal dysfunction, which would not be expected to improve after 8 days.

**Educational objective:**
Acute tubular necrosis is characterized by tubular injury due to renal ischemia or direct cytotoxicity. The course of the disease can be broken into 3 stages: initiation (initial insult), maintenance (oliguric renal failure), and recovery. During the recovery period, glomerular filtration rate improves prior to restoration of renal tubular resorptive capacity, so transient polyuria and electrolyte wasting (eg, hypokalemia) can occur.

The clinical course of ATN can be broken into 3 stages. The **initiation** stage is marked by the inciting event (eg, hemorrhage, as in this patient) and the onset of tubular injury. If significant tubular damage occurs, the **maintenance** stage (oliguric stage) follows in 24-36 hours. During this stage, **urine output decreases** and patients may develop volume overload. Renal tubular dysfunction results in the characteristic low urinary osmolality (<350 mOsm/kg), high urinary sodium (>30 mEq/L), and high urinary fractional sodium excretion (>1%).

In spite of the seemingly profound damage that occurs to nephrons in ATN, tubular epithelial cells have excellent regenerative capacity. If the patient survives the maintenance stage (by conservative management or dialysis), the **recovery** stage follows in 1-3 weeks. Glomerular filtration rate often improves before renal tubular function is restored, so patients can develop **transient polyuria** (sometimes >3 L/day) with significant **electrolyte wasting** because tubular resorptive capacity remains impaired. During this time, patients are at high risk of developing clinically significant electrolyte imbalances, particularly **hypokalemia**, which can be life-threatening. Serum concentrations of magnesium, phosphorus, and calcium may also be low. Most patients recover completely, depending on the magnitude of the initial injury.

**(Choices A, C, and E)** Hyperphosphatemia, anion gap metabolic acidosis, and volume overload occur in the maintenance stage of ATN. This patient's spontaneous diuresis and falling creatinine are more consistent with the recovery phase.

**(Choice D)** Protein-losing nephropathies (eg, nephrotic syndrome) occur due to significant glomerular damage. Because the destruction in ATN is largely tubular, protein loss is unexpected. Patients with nephrotic syndrome typically develop progressive renal dysfunction, which would not be expected to improve after 8 days.

**Educational objective:**
Acute tubular necrosis is characterized by tubular injury due to renal ischemia or direct cytotoxicity. The course of the disease can be broken into 3 stages: initiation (initial insult), maintenance (oliguric renal failure), and recovery. During the recovery period, glomerular filtration rate improves prior to restoration of renal tubular resorptive capacity, so transient polyuria and electrolyte wasting (eg, hypokalemia) can occur.

| Pathology | Renal, Urinary Systems & Electrolytes | Acute kidney injury |
|---|---|---|
| Subject | System | Topic |

Copyright © UWorld. All rights reserved.

A 34-year-old man is being evaluated for acute hematuria and oliguria. He has no chronic medical conditions and takes no medications on a regular basis. Blood pressure is 170/100 mm Hg. Blood urea nitrogen is 38 mg/dL and serum creatinine is 4.5 mg/dL. The patient undergoes kidney biopsy. The following microscopic changes are seen after silver staining to highlight the glomerular tuft:

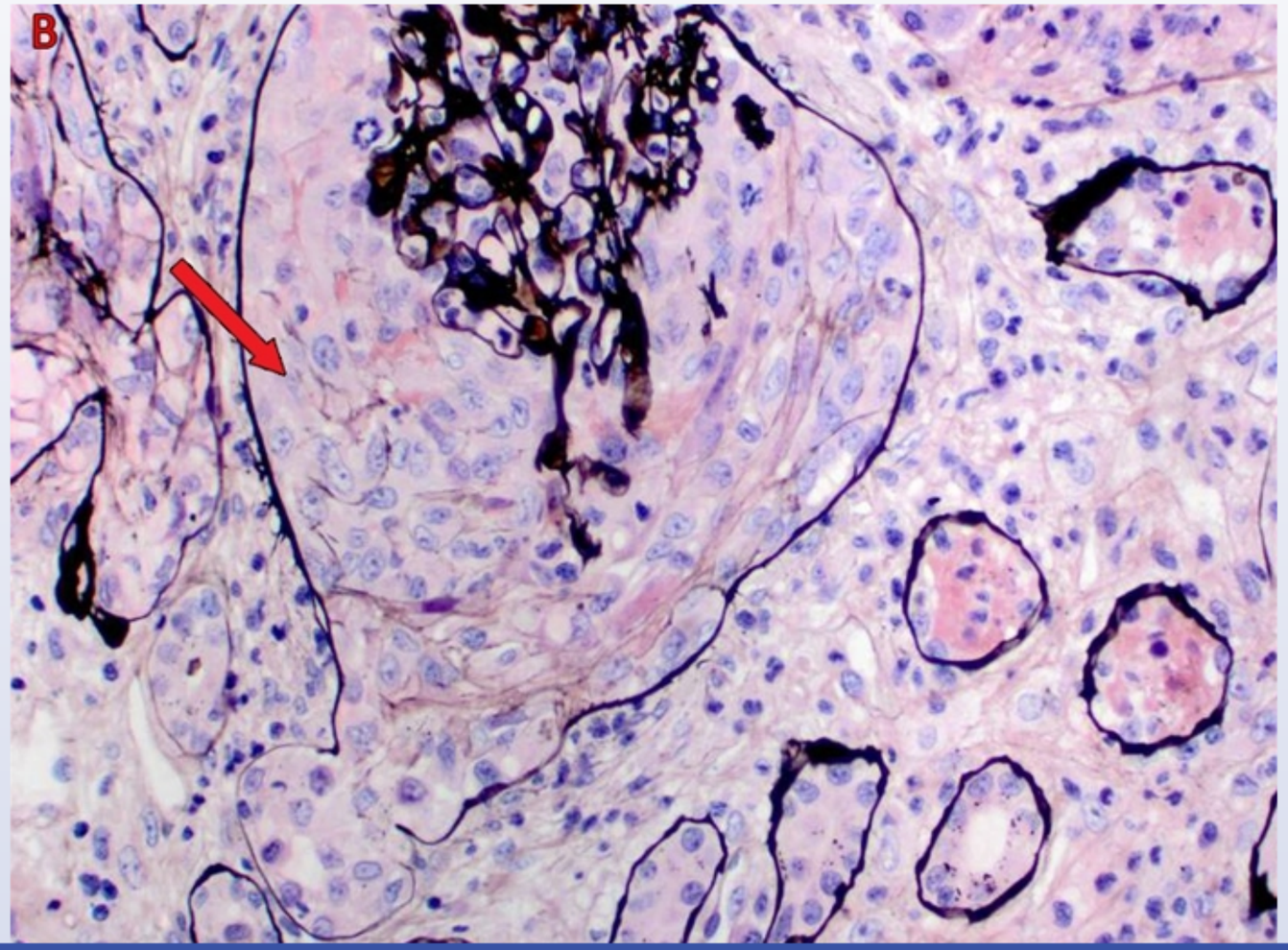

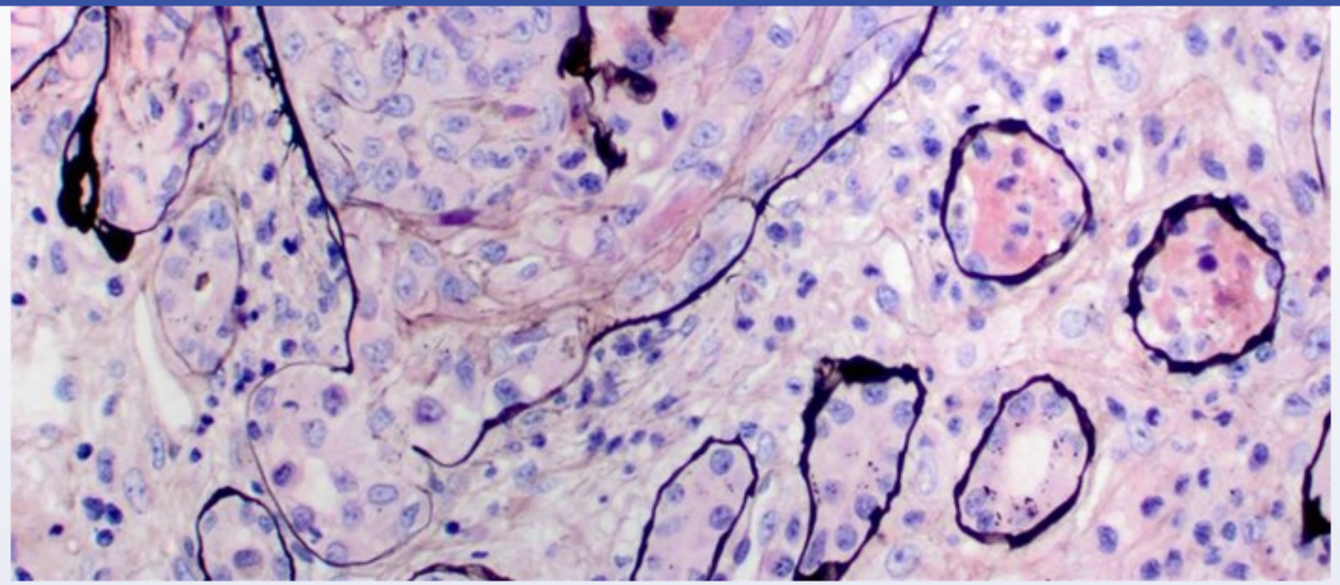

The area marked with an arrow is likely to have abnormal deposition of which of the following substances?

- A. Amyloid
- B. Fibrin
- C. IgE
- D. Lipid
- E. Myoglobin

Submit

1 2 3 4 5 6 7 8 9 10 11 12 13 14 15 16 17 18 19 20 21 22 23 24 25 26 27 28 29 30

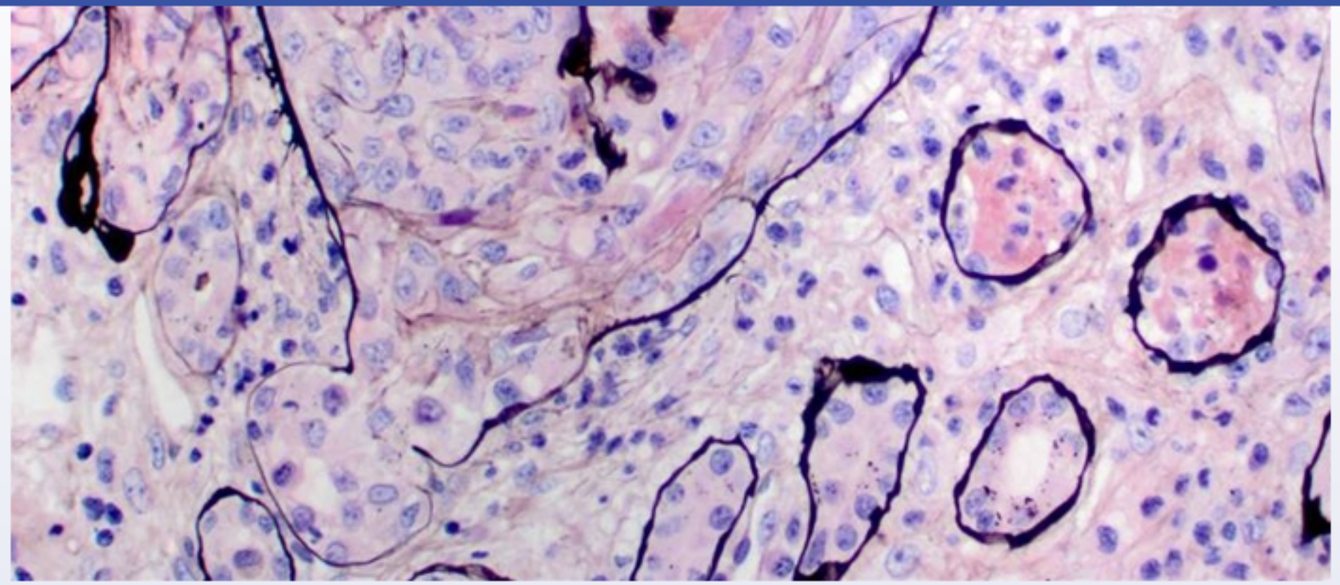

The area marked with an arrow is likely to have abnormal deposition of which of the following substances?

- A. Amyloid (22%)
- ✓ B. Fibrin (63%)
- C. IgE (4%)
- D. Lipid (2%)
- E. Myoglobin (6%)

Omitted
Correct answer

63%
Answered correctly

04 secs
Time Spent

06/28/2020
Last Updated

# Pathogenesis of crescent formation in rapidly progressive glomerulonephritis

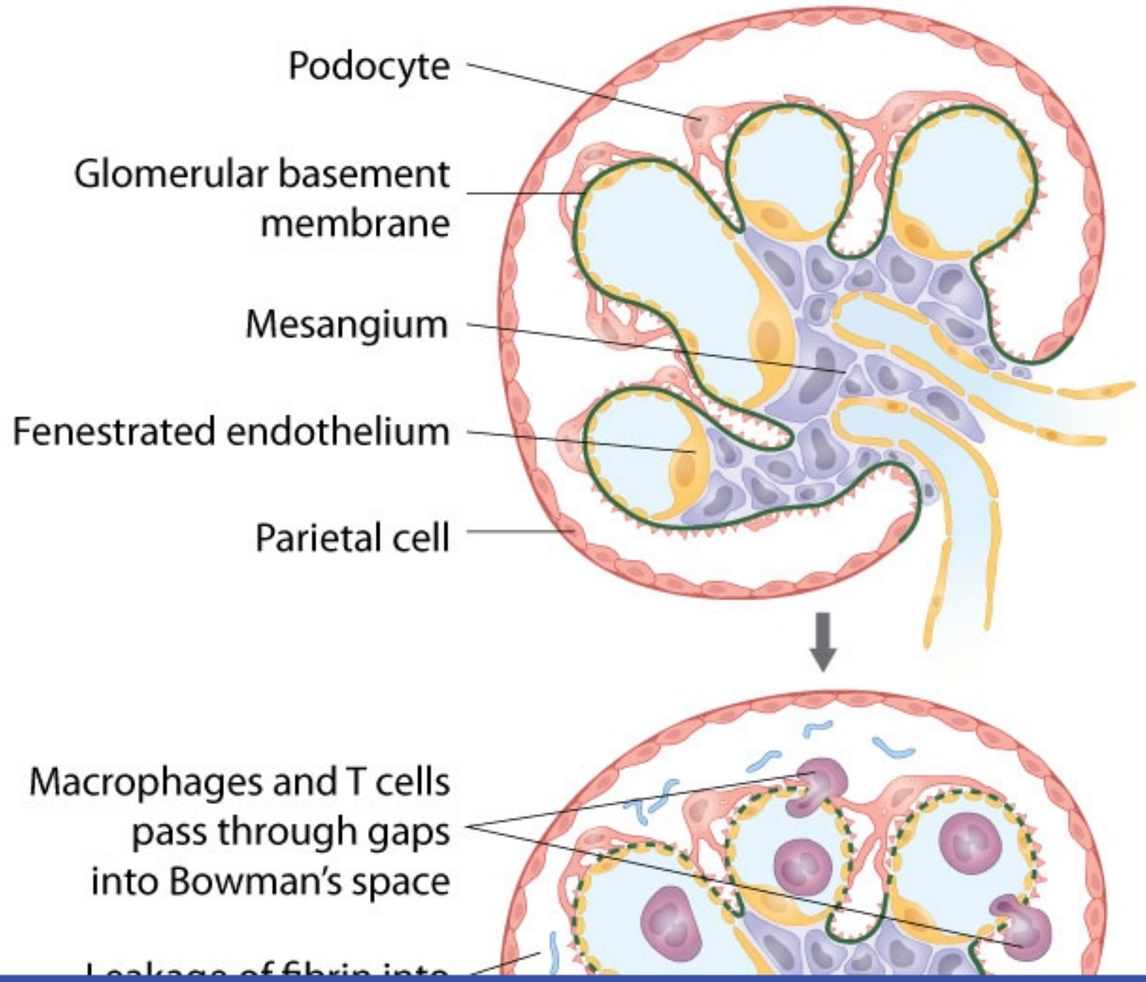

1 2 3 4 5 6 7 8 9 10 11 12 13 14 15 16 17 18 19 20 21 22 23 24 25 26 27 28 29 30

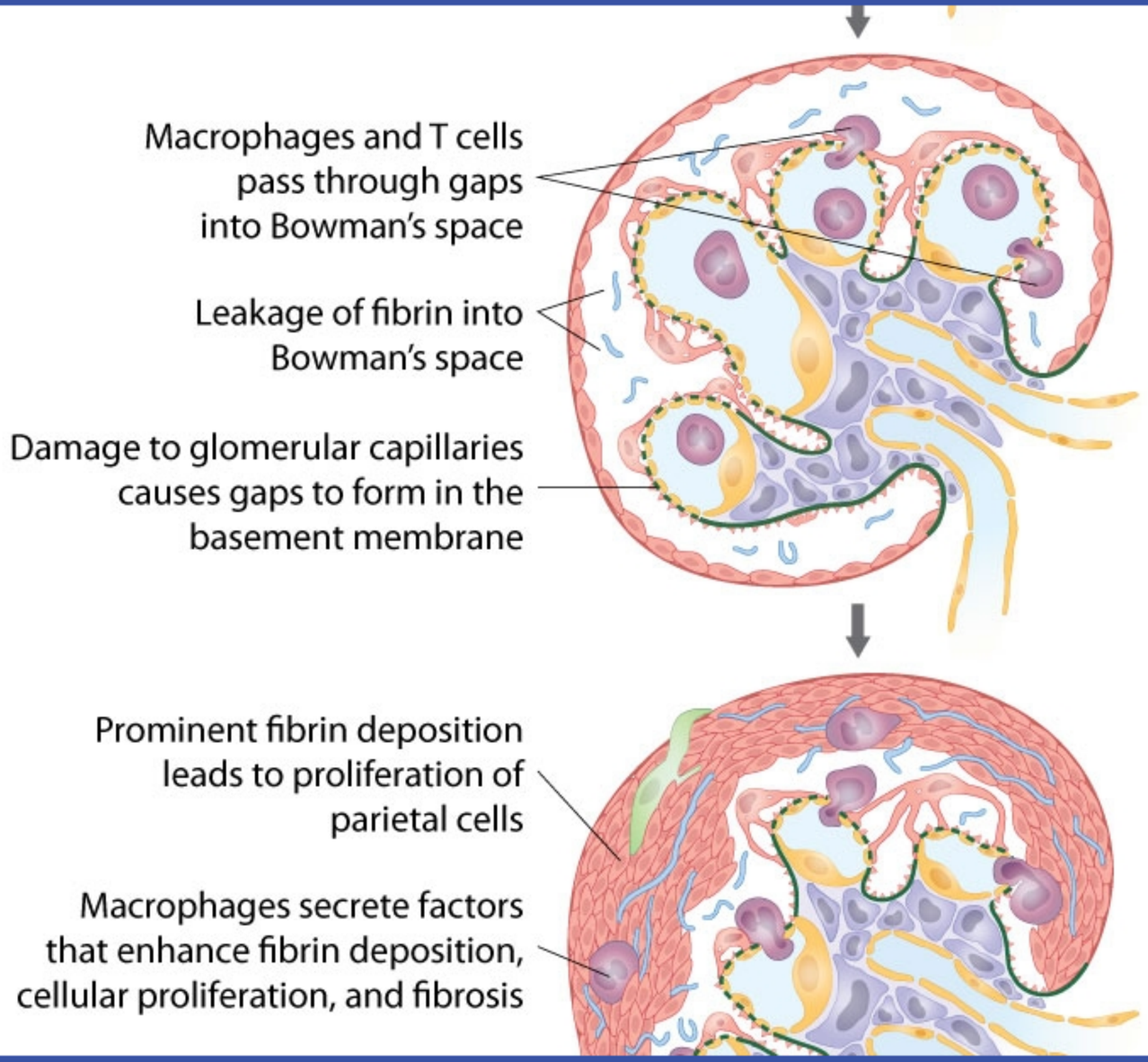

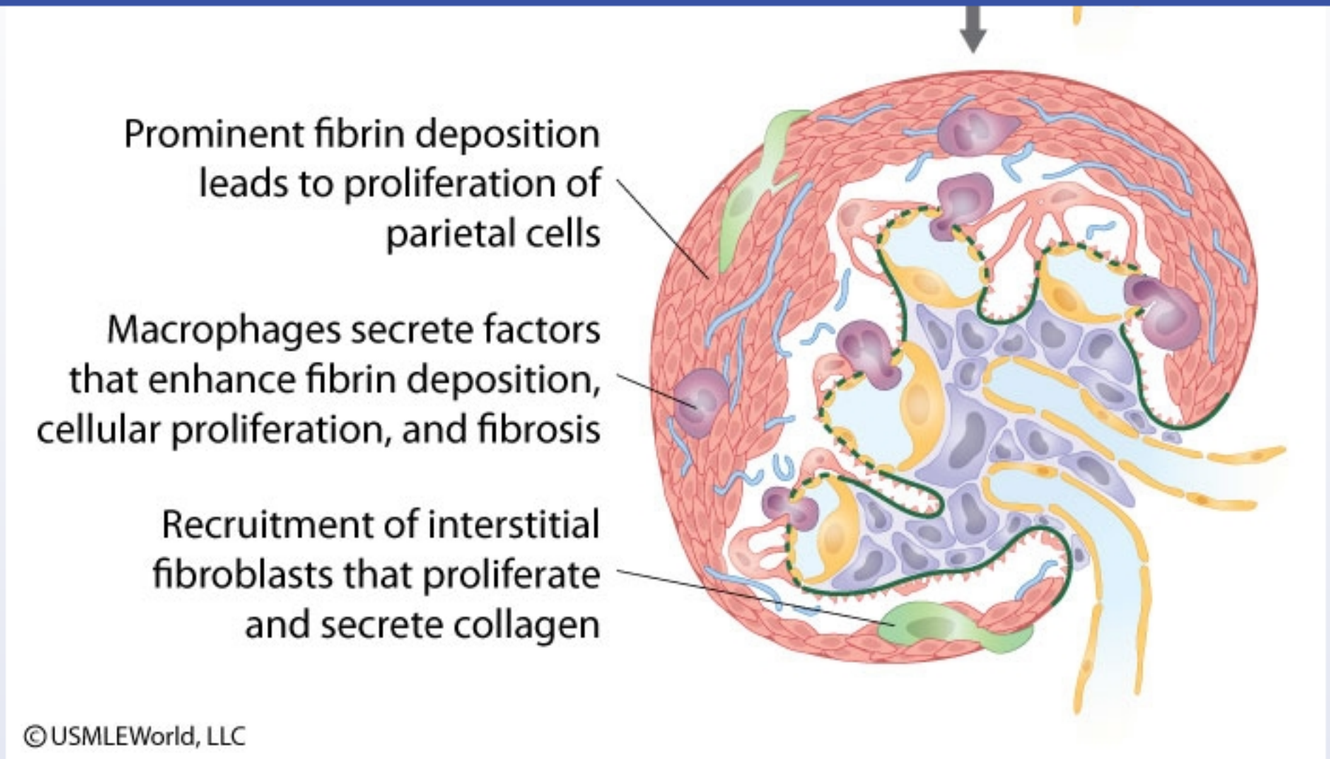


This patient with acute renal failure and hematuria has a glomerular crescent noted on light microscopy. Glomerular crescents, defined as >2 layers of **proliferating cells within the Bowman space**, form in response to immune or inflammatory-mediated injury to glomerular capillaries. Disruption of the glomerular basement membrane allows gaps to form within the capillary, resulting in an influx of coagulation factors (eg, tissue factor, fibrinogen) and inflammatory cells (eg, lymphocytes, macrophages) into the Bowman space. Initiation of the coagulation cascade promotes the deposition of **large quantities of fibrin**, while inflammatory cells proliferate and release growth factors and inflammatory cytokines that recruit fibroblasts and stimulate parietal cell proliferation. This eventually results in progressive glomerular hypercellularity, fibrosis, and irreversible renal injury.

Crescent formation is diagnostic of **rapidly progressive glomerulonephritis** (RPGN), a syndrome of severe renal injury that can occur in a number of disease processes (eg, anti-glomerular basement antibody [Goodpasture] disease, granulomatosis with polyangiitis). Like other

This patient with acute renal failure and hematuria has a glomerular crescent noted on light microscopy. Glomerular crescents, defined as >2 layers of **proliferating cells within the Bowman space**, form in response to immune or inflammatory-mediated injury to glomerular capillaries. Disruption of the glomerular basement membrane allows gaps to form within the capillary, resulting in an influx of coagulation factors (eg, tissue factor, fibrinogen) and inflammatory cells (eg, lymphocytes, macrophages) into the Bowman space. Initiation of the coagulation cascade promotes the deposition of **large quantities of fibrin**, while inflammatory cells proliferate and release growth factors and inflammatory cytokines that recruit fibroblasts and stimulate parietal cell proliferation. This eventually results in progressive glomerular hypercellularity, fibrosis, and irreversible renal injury.

Crescent formation is diagnostic of **rapidly progressive glomerulonephritis** (RPGN), a syndrome of severe renal injury that can occur in a number of disease processes (eg, anti-glomerular basement antibody [Goodpasture] disease, granulomatosis with polyangiitis). Like other nephritic syndromes, it typically presents with hematuria, hypertension, and progressive renal failure; however, renal decompensation and progression to end-stage renal disease occur particularly quickly (weeks to months) in RPGN.

**(Choice A)** Amyloid is visualized as amorphous mesangial deposits on light microscopy or, when stained with Congo red, as apple-green, birefringent deposits under polarized light. It is associated with nephrotic syndrome (heavy proteinuria, hyperlipidemia), not with nephritic syndrome as seen in this patient.

**(Choice C)** Goodpasture disease can cause RPGN and is characterized by antibodies against the glomerular basement membrane. However, these antibodies are usually IgG, or occasionally IgM or IgA. IgE mediates immediate hypersensitivity reactions, and participates in host defenses against some parasites, but it does not participate in the pathogenesis of RPGN.

**(Choice D)** The clear cells seen in renal cell carcinoma (RCC) have a high lipid content, which is responsible for the yellow tinge noted on gross histology. RCC can cause hematuria and hypertension but does not cause crescent formation or renal failure.

**(Choice E)** Myoglobinuria is seen in rhabdomyolysis; urine dipstick is positive for blood, but red blood cells are absent on urinalysis. Myoglobin is toxic to renal tubular cells and induces acute tubular necrosis, not glomerular injury and crescent formation.

**Educational objective:**
Crescent formation on light microscopy is diagnostic for rapidly progressive glomerulonephritis. Crescents consist of glomerular parietal cells, lymphocytes, and macrophages along with abundant fibrin deposition. Crescents eventually become fibrotic, disrupting glomerular function and

Settings

1 2 3 4 5 6 7 8 9 10 11 12 13 14 15 16 17 18 19 20 21 22 23 24 25 26 27 28 29 30

Item 9 of 39
Question Id: 24

Mark | Previous | Next | Full Screen | Tutorial | Lab Values | Notes | Calculator | Reverse Color | Text Zoom | Settings

This patient with acute renal failure and hematuria has a glomerular crescent noted on light microscopy. Glomerular crescents, defined as >2

Exhibit Display

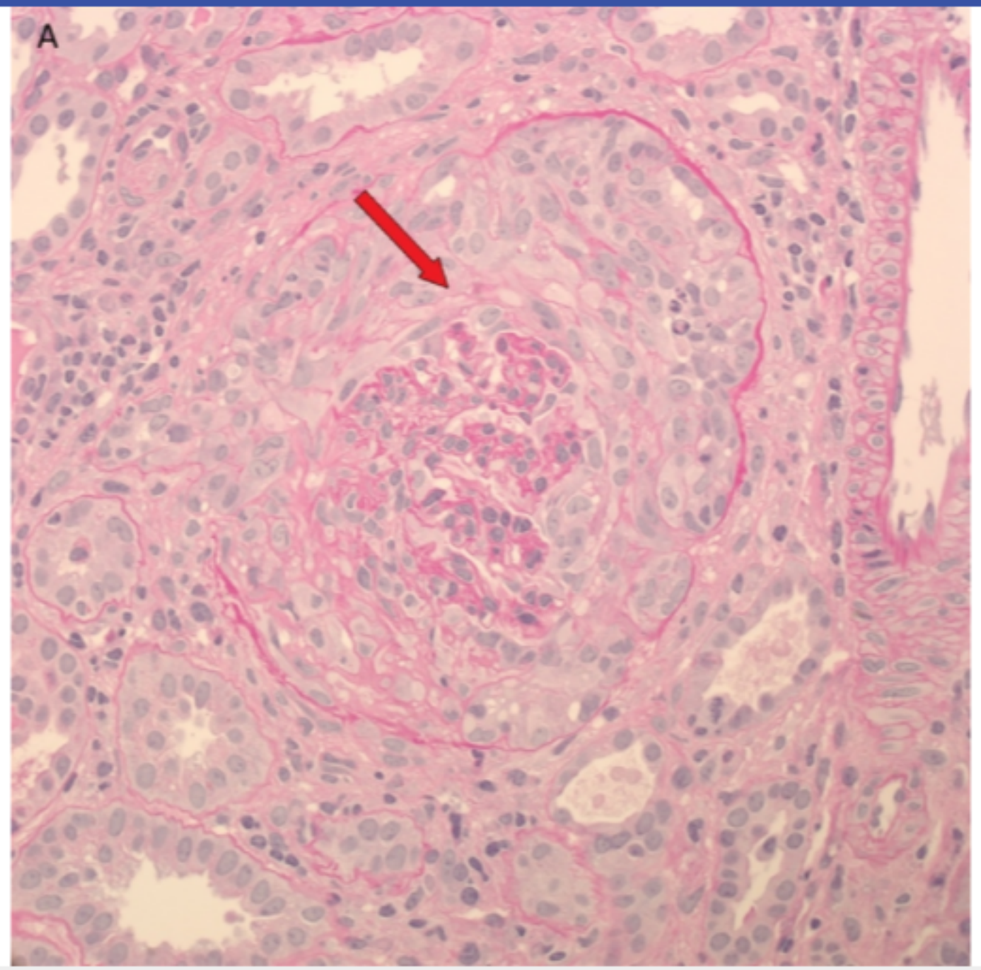


Zoom In | Zoom Out | Reset | Add To New Card | Existing Card

lymphocytes, and macrophages along with abundant fibrin deposition. Crescents eventually become fibrotic, disrupting glomerular function and

Block Time Remaining: 00:04:43
TUTOR

8 | Feedback | Suspend | End Block

1 2 3 4 5 6 7 8 9 10 11 12 13 14 15 16 17 18 19 20 21 22 23 24 25 26 27 28 29 30

This patient with acute renal failure and hematuria has a glomerular crescent noted on light microscopy. Glomerular crescents, defined as >2

Exhibit Display

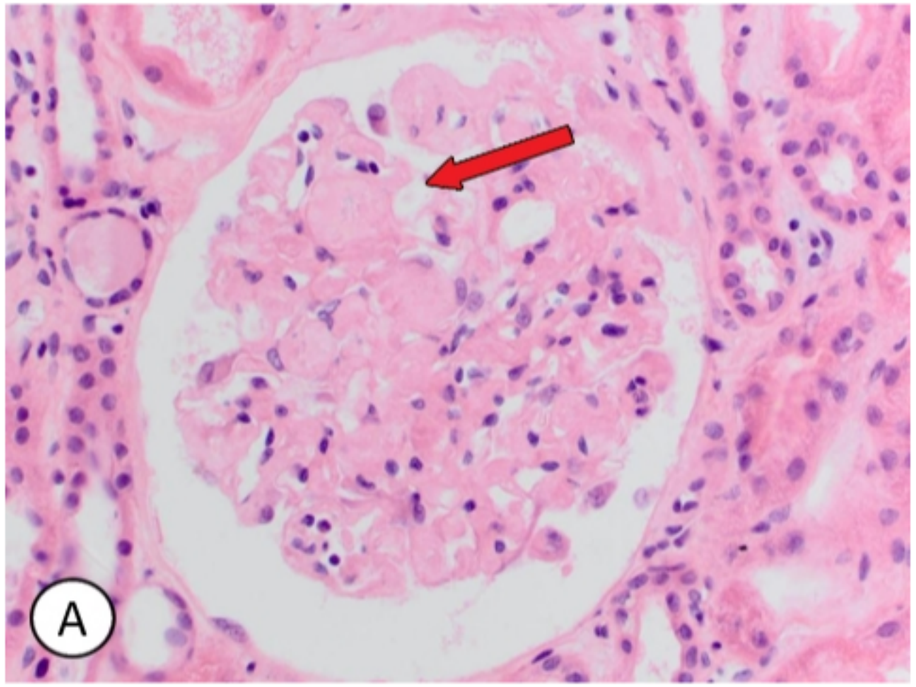


Zoom In | Zoom Out | Reset | Add To New Card | Existing Card

lymphocytes, and macrophages along with abundant fibrin deposition. Crescents eventually become fibrotic, disrupting glomerular function and

injury.

Crescent formation is diagnostic of **rapidly progressive glomerulonephritis** (RPGN), a syndrome of severe renal injury that can occur in a number of disease processes (eg, anti-glomerular basement antibody [Goodpasture] disease, granulomatosis with polyangiitis). Like other nephritic syndromes, it typically presents with hematuria, hypertension, and progressive renal failure; however, renal decompensation and progression to end-stage renal disease occur particularly quickly (weeks to months) in RPGN.

**(Choice A)** Amyloid is visualized as amorphous mesangial deposits on light microscopy or, when stained with Congo red, as apple-green, birefringent deposits under polarized light. It is associated with nephrotic syndrome (heavy proteinuria, hyperlipidemia), not with nephritic syndrome as seen in this patient.

**(Choice C)** Goodpasture disease can cause RPGN and is characterized by antibodies against the glomerular basement membrane. However, these antibodies are usually IgG, or occasionally IgM or IgA. IgE mediates immediate hypersensitivity reactions, and participates in host defenses against some parasites, but it does not participate in the pathogenesis of RPGN.

**(Choice D)** The clear cells seen in renal cell carcinoma (RCC) have a high lipid content, which is responsible for the yellow tinge noted on gross histology. RCC can cause hematuria and hypertension but does not cause crescent formation or renal failure.

**(Choice E)** Myoglobinuria is seen in rhabdomyolysis; urine dipstick is positive for blood, but red blood cells are absent on urinalysis. Myoglobin is toxic to renal tubular cells and induces acute tubular necrosis, not glomerular injury and crescent formation.

**Educational objective:**
Crescent formation on light microscopy is diagnostic for rapidly progressive glomerulonephritis. Crescents consist of glomerular parietal cells, lymphocytes, and macrophages along with abundant fibrin deposition. Crescents eventually become fibrotic, disrupting glomerular function and causing irreversible renal injury.

| Pathology | Renal, Urinary Systems & Electrolytes | Glomerular disorders |
|---|---|---|
| Subject | System | Topic |

Copyright © UWorld. All rights reserved.

1 2 3 4 5 6 7 8 9 10 11 12 13 14 15 16 17 18 19 20 21 22 23 24 25 26 27 28 29 30

injury.

Exhibit Display

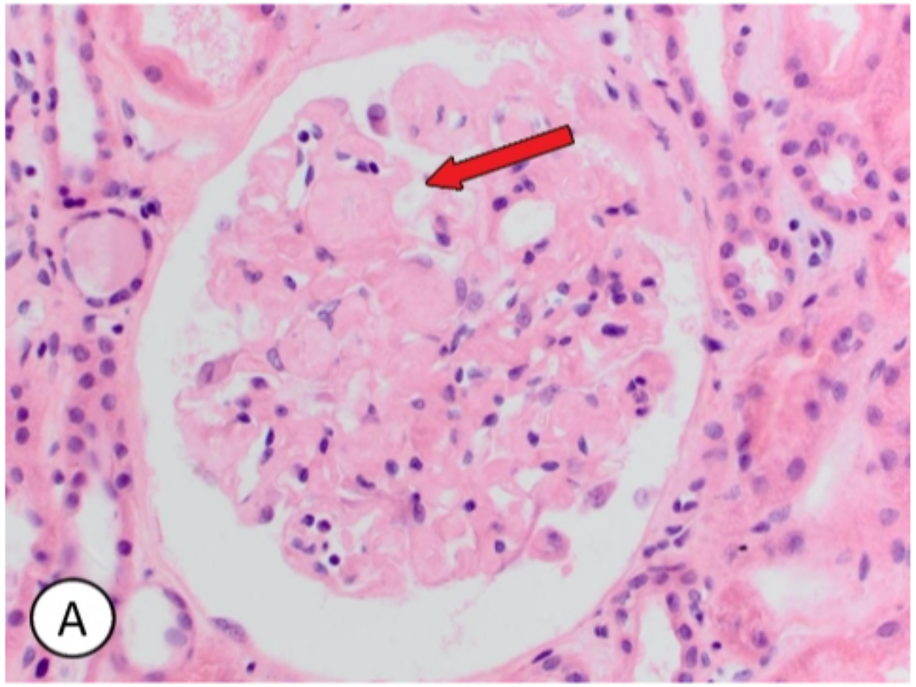


Zoom In | Zoom Out | Reset | Add To New Card | Existing Card

1
2
3
4
5
6
7
8
9
10
11
12
13
14
15
16
17
18
19
20
21
22
23
24
25
26
27
28
29
30

injury.

Exhibit Display

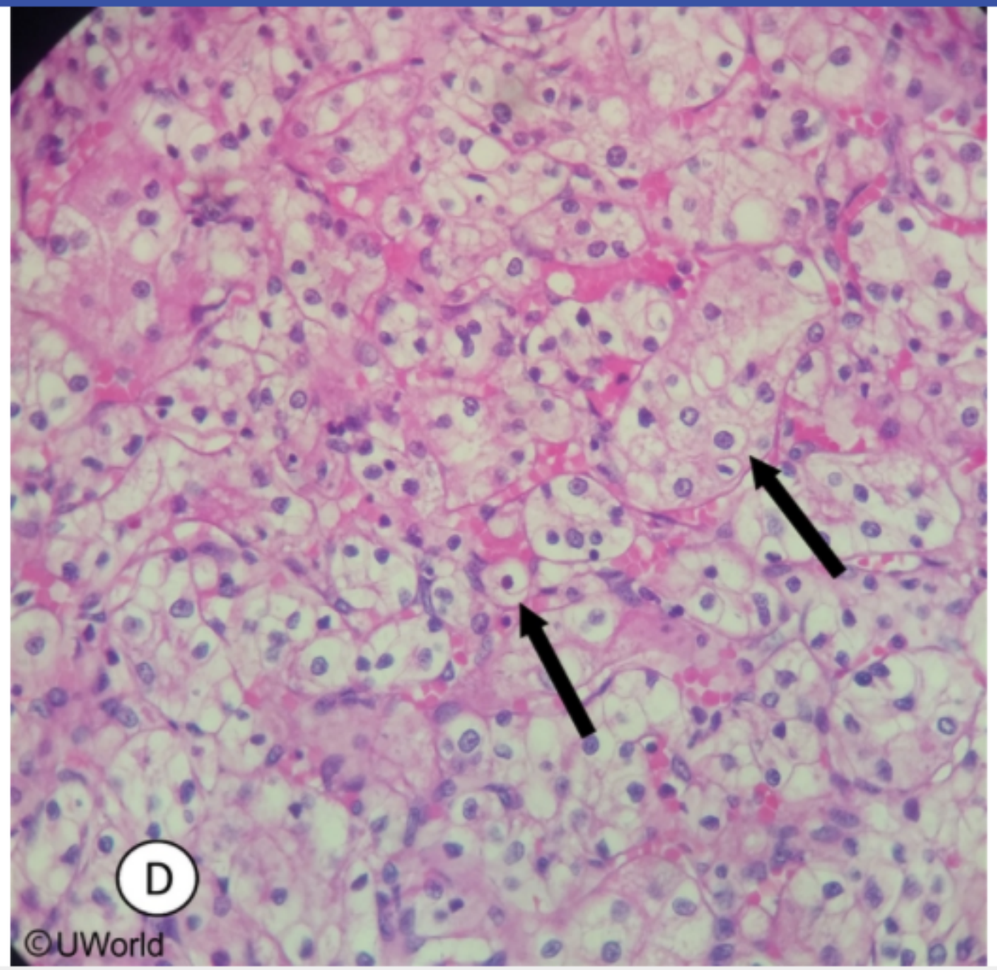


Zoom In | Zoom Out | Reset | Add To New Card | Existing Card

injury.

Exhibit Display

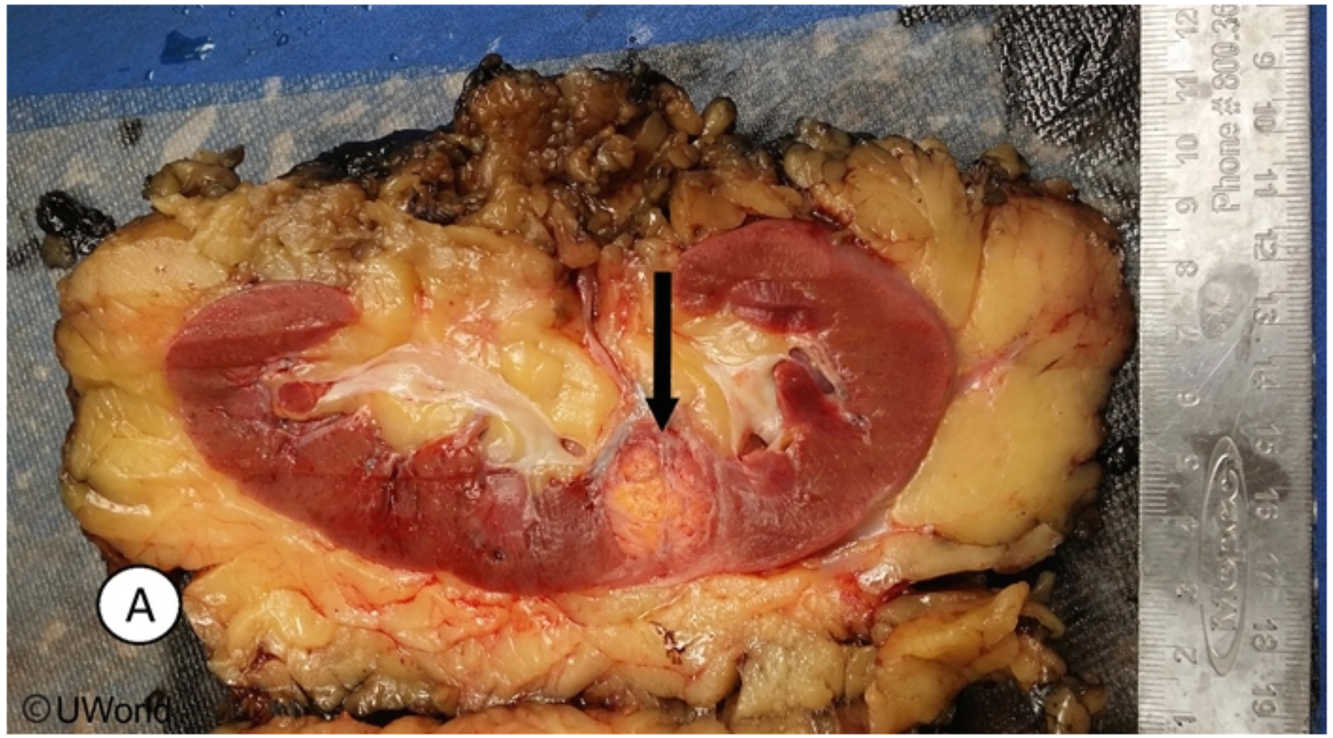


Zoom In | Zoom Out | Reset | Add To New Card | Existing Card

1
2
3
4
5
6
7
8
9
10
11
12
13
14
15
16
17
18
19
20
21
22
23
24
25
26
27
28
29
30

injury.

Exhibit Display

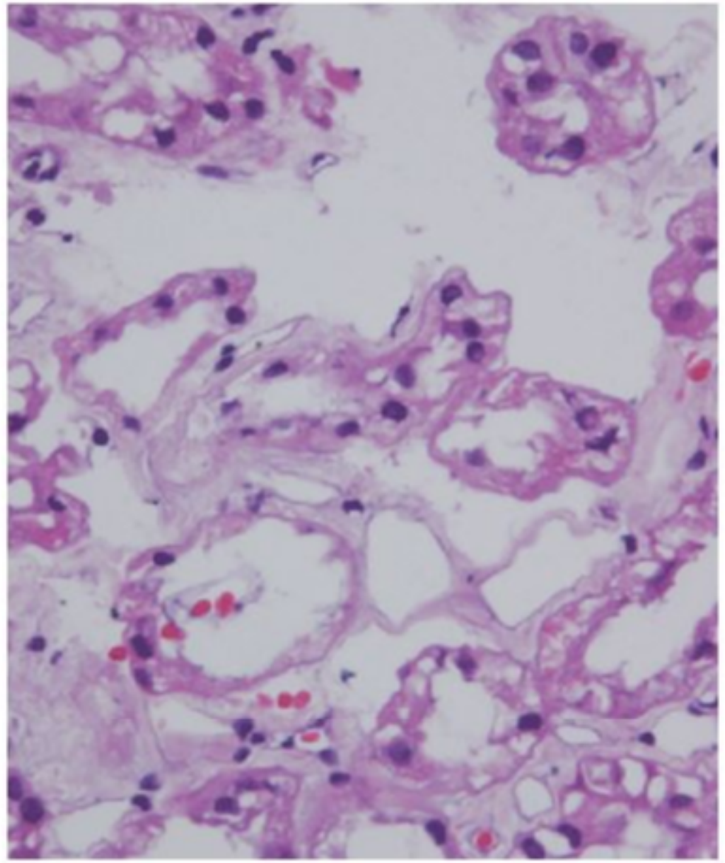

Zoom In | Zoom Out | Reset | Add To New Card | Existing Card

A 64-year-old woman comes to her nephrologist for a regular follow-up appointment. The patient's medical problems include diabetes mellitus for 20 years and stage IV chronic kidney disease with a glomerular filtration rate <30 mL/min. She takes daily insulin and has made lifestyle modifications. Recently, her blood glucose has been well controlled. The patient's other medical problems include hypertension and dyslipidemia, which are controlled with medication. Her BMI is 27 kg/m$^2$. Cardiopulmonary examination is normal. Lower extremity examination shows trace bilateral edema and 2+ pulses. This patient is at greatest risk for which of the following long-term complications of her renal disease?

A. Hypercalcemia

B. Hyperthyroidism

C. Hypoparathyroidism

D. Osteodystrophy

E. Retinal neovascularization

Submit

A 64-year-old woman comes to her nephrologist for a regular follow-up appointment. The patient's medical problems include diabetes mellitus for 20 years and stage IV chronic kidney disease with a glomerular filtration rate <30 mL/min. She takes daily insulin and has made lifestyle modifications. Recently, her blood glucose has been well controlled. The patient's other medical problems include hypertension and dyslipidemia, which are controlled with medication. Her BMI is 27 kg/m$^2$. Cardiopulmonary examination is normal. Lower extremity examination shows trace bilateral edema and 2+ pulses. This patient is at greatest risk for which of the following long-term complications of her renal disease?

- A. Hypercalcemia (8%)
- B. Hyperthyroidism (0%)
- C. Hypoparathyroidism (3%)
- ✓ D. Osteodystrophy (80%)
- E. Retinal neovascularization (7%)

Omitted
Correct answer
D

80%
Answered correctly

02 secs
Time Spent

01/26/2020
Last Updated

Explanation

**Renal osteodystrophy**

**Chronic kidney disease (↓GFR)**

## Renal osteodystrophy

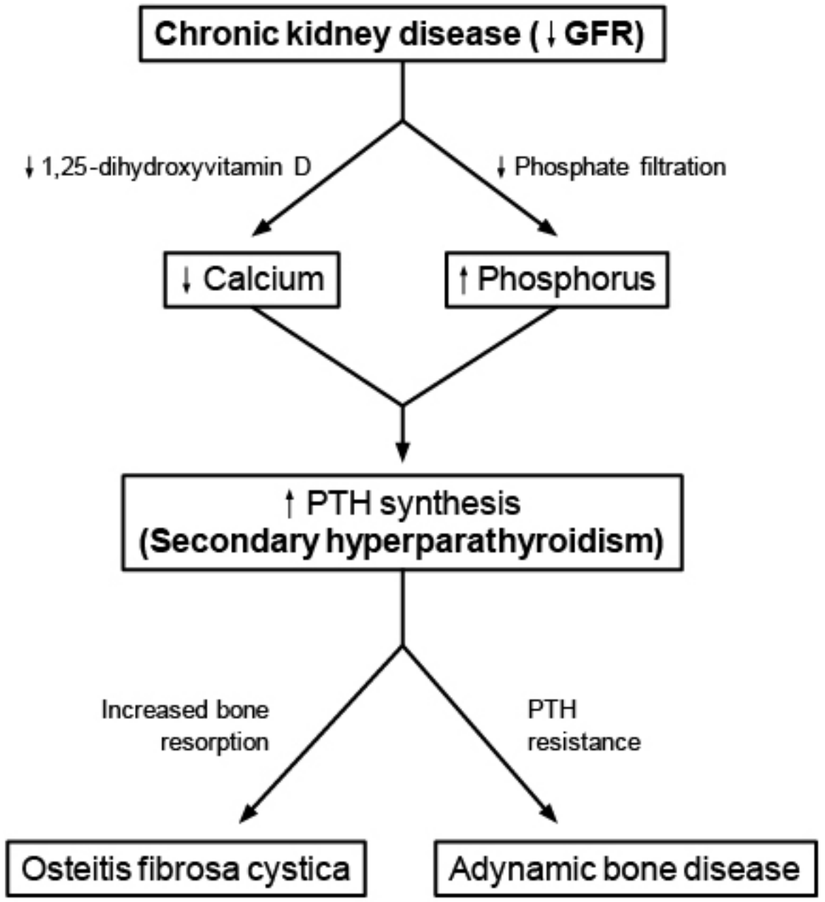


GFR = glomerular filtration rate; PTH = parathyroid hormone.

©UWorld

The abnormal bone pathology seen in **chronic kidney disease** (CKD) is referred to as **renal osteodystrophy**. In CKD, failure of glomerular and tubular function results in hyperphosphatemia and hypocalcemia. The parathyroid gland is sensitive to small changes in serum calcium; as a

©UWorld

The abnormal bone pathology seen in **chronic kidney disease** (CKD) is referred to as **renal osteodystrophy**. In CKD, failure of glomerular and tubular function results in hyperphosphatemia and hypocalcemia. The parathyroid gland is sensitive to small changes in serum calcium; as a result, the hypocalcemia caused by CKD stimulates parathyroid hormone (PTH) production, leading to secondary hyperparathyroidism **(Choice C)**. PTH mobilizes calcium from bones by activating osteoclastic and osteocytic activity. This high-turnover osteodystrophy increases bone resorption more than bone formation, causing **osteopenia** and pathologic bone changes similar to those seen in primary hyperparathyroidism (osteitis fibrosa cystica). Patients can also develop PTH resistance, resulting in low-turnover adynamic bone disease and **osteomalacia**.

Deranged signaling between renal cells and bone osteoblasts and osteoclasts (eg, FGF-23, Klotho) also contributes to the skeletal changes that occur in CKD.

**(Choice A)** CKD generally results in hypocalcemia. However, excessive use of calcium-containing phosphate binders or dialysis solutions high in calcium can cause hypercalcemia in some patients.

**(Choice B)** Renal failure results in accumulation of uremic toxins. Uremia has been shown to decrease peripheral tissue conversion of T4 to T3. This could cause functional hypothyroidism (not hyperthyroidism).

**(Choice E)** Patients with diabetic nephropathy should be screened for diabetic retinopathy. Retinopathy is a complication of diabetes, not chronic renal failure or hemodialysis.

**Educational objective:**
Patients with chronic kidney disease may develop renal osteodystrophy from secondary hyperparathyroidism (caused by hyperphosphatemia and hypocalcemia).

**References**


- Metabolic disorders in patients with chronic kidney failure.
- Treatment of secondary hyperparathyroidism in haemodialysis patients: a randomised clinical trial comparing paricalcitol and alfacalcidol.
- Hyperphosphatemia of chronic kidney disease.

A 68-year-old man comes to the office due to intermittent, painless blood in his urine. He has no other symptoms. The patient uses transdermal testosterone for chronic hypogonadism and erectile dysfunction. He has smoked a pack of cigarettes daily for 40 years; he drinks 2 shots of vodka every day and 2 glasses of wine once a week. He works as an operations manager for a large beverage company and frequently travels to Mexico. Vital signs are within normal limits. Abdominal examination shows no abnormalities. On digital rectal examination, the prostate is smooth with no nodules. Urinalysis is positive for >50 red blood cells/hpf; there are no casts or dysmorphic blood cells. Urine cytology is positive for malignant cells. Renal ultrasonogram reveals normal kidneys. Which of the following is a major risk factor for this patient's current condition?

- A. Alcohol use
- B. Occupation
- C. Testosterone therapy
- D. Tobacco smoking
- E. Travel history

Submit

A 68-year-old man comes to the office due to intermittent, painless blood in his urine. He has no other symptoms. The patient uses transdermal testosterone for chronic hypogonadism and erectile dysfunction. He has smoked a pack of cigarettes daily for 40 years; he drinks 2 shots of vodka every day and 2 glasses of wine once a week. He works as an operations manager for a large beverage company and frequently travels to Mexico. Vital signs are within normal limits. Abdominal examination shows no abnormalities. On digital rectal examination, the prostate is smooth with no nodules. Urinalysis is positive for >50 red blood cells/hpf; there are no casts or dysmorphic blood cells. Urine cytology is positive for malignant cells. Renal ultrasonogram reveals normal kidneys. Which of the following is a major risk factor for this patient's current condition?

A. Alcohol use (2%)
B. Occupation (2%)
C. Testosterone therapy (2%)
✓ D. Tobacco smoking (89%)
E. Travel history (3%)

Omitted
Correct answer
D

89%
Answered correctly

02 secs
Time Spent

06/17/2020
Last Updated

Explanation

| Specific cancer risk factors | | | |
|---|---|---|---|
| | • Tobacco smoke | | • Tobacco smoke |

| Specific cancer risk factors | | | |
|---|---|---|---|
| **Pancreas** | • Tobacco smoke<br>• Obesity | **Renal** | • Tobacco smoke<br>• Obesity<br>• Hypertension |
| **Gastric** | • Dietary nitrates<br>• Alcohol & tobacco use<br>• *Helicobacter pylori* | **Bladder** | • Tobacco smoke<br>• Occupational exposures (rubber, plastics, aromatic amine-containing dyes, textiles, leather) |
| **Liver** | • Hepatitis B & C<br>• Liver cirrhosis (any cause)<br>• Hemochromatosis<br>• Aflatoxin | **Breast** | • Early menarche<br>• Late menopause<br>• Nulliparity<br>• *BRCA* mutations |
| **Colorectal** | • Hereditary CRC syndromes<br>• Inflammatory bowel disease<br>• Obesity<br>• Charred or fried foods | **Prostate** | • Increasing age<br>• African-American |

CRC = colorectal cancer.

This patient has intermittent, **painless hematuria**. His positive urine cytology and negative imaging of the upper urinary tract suggest a **urothelial (transitional cell) cancer** in the **bladder**. The lesions in urothelial cancer can be visualized on cystoscopy as erythematous flat, nodular, or papillary lesions. On biopsy, the malignant cells are pleomorphic with hyperchromatic nuclei, an increased nucleus/cytoplasm ratio, disrupted orientation and polarity (in relation to the basal membrane), and frequent mitotic figures. Depth of invasion is important for staging; invasion into the muscular layer is associated with a poor prognosis.

Urothelial cancer is most common in patients age >60, with men affected more than women. Major risk factors include **cigarette smoking** and

CRC = colorectal cancer.

This patient has intermittent, **painless hematuria**. His positive urine cytology and negative imaging of the upper urinary tract suggest a **urothelial (transitional cell) cancer** in the **bladder**. The lesions in urothelial cancer can be visualized on cystoscopy as erythematous flat, nodular, or papillary lesions. On biopsy, the malignant cells are pleomorphic with hyperchromatic nuclei, an increased nucleus/cytoplasm ratio, disrupted orientation and polarity (in relation to the basal membrane), and frequent mitotic figures. Depth of invasion is important for staging; invasion into the muscular layer is associated with a poor prognosis.

Urothelial cancer is most common in patients age >60, with men affected more than women. Major risk factors include **cigarette smoking** and occupational exposure to rubber, plastics, or aromatic amine-containing dyes (eg, used in textile and leather processing). Cyclophosphamide therapy (eg, for lymphoma, autoimmune disorders) also increases the risk.

**(Choice A)** Heavy alcohol intake is associated with increased risk of squamous cell carcinoma of the upper gastrointestinal tract (mouth, throat, esophagus) and hepatocellular carcinoma. The risk for bladder cancer is not significantly increased.

**(Choice B)** The carcinogens implicated in urothelial cancer are not commonly encountered in the food and beverage industry.

**(Choice C)** Testosterone therapy increases the risk for prostate cancer, which is often asymptomatic or discovered on evaluation for lower urinary tract voiding symptoms (eg, decreased force of stream, nocturia). Painless hematuria without voiding symptoms is more suggestive of bladder cancer.

**(Choice E)** *Schistosoma haematobium* is a trematode endemic to Africa and the Middle East that causes chronic infection in the bladder and increases the risk for a variety of bladder malignancies (including transitional cell and squamous cell carcinoma). This organism is not common in Mexico.

**Educational objective:**
Major risk factors for urothelial cancer of the bladder include age >60, cigarette smoking, and occupational exposure to rubber, plastics, or aromatic amine-containing dyes. Cyclophosphamide therapy also increases the risk.

**References**

- Epidemiology and risk factors of urothelial bladder cancer.

1
2
3
4
5
6
7
8
9
10
11
12
13
14
15
16
17
18
19
20
21
22
23
24
25
26
27
28
29
30

the muscular layer is associated with a poor prognosis.

Urothelial cancer is most common in patients age >60, with men affected more than women. Major risk factors include **cigarette smoking** and occupational exposure to rubber, plastics, or aromatic amine-containing dyes (eg, used in textile and leather processing). Cyclophosphamide therapy (eg, for lymphoma, autoimmune disorders) also increases the risk.

**(Choice A)** Heavy alcohol intake is associated with increased risk of squamous cell carcinoma of the upper gastrointestinal tract (mouth, throat, esophagus) and hepatocellular carcinoma. The risk for bladder cancer is not significantly increased.

**(Choice B)** The carcinogens implicated in urothelial cancer are not commonly encountered in the food and beverage industry.

**(Choice C)** Testosterone therapy increases the risk for prostate cancer, which is often asymptomatic or discovered on evaluation for lower urinary tract voiding symptoms (eg, decreased force of stream, nocturia). Painless hematuria without voiding symptoms is more suggestive of bladder cancer.

**(Choice E)** *Schistosoma haematobium* is a trematode endemic to Africa and the Middle East that causes chronic infection in the bladder and increases the risk for a variety of bladder malignancies (including transitional cell and squamous cell carcinoma). This organism is not common in Mexico.

**Educational objective:**
Major risk factors for urothelial cancer of the bladder include age >60, cigarette smoking, and occupational exposure to rubber, plastics, or aromatic amine-containing dyes. Cyclophosphamide therapy also increases the risk.

**References**

- Epidemiology and risk factors of urothelial bladder cancer.

| Pathology | Renal, Urinary Systems & Electrolytes | Bladder cancer |
|---|---|---|
| Subject | System | Topic |

Copyright © UWorld. All rights reserved.

A 67-year-old man comes to the office due to generalized weakness, easy fatigability, anorexia, and intermittent nausea for the past several months. He also says that he is "itching and scratching a lot." Physical examination shows bilateral lower extremity pitting edema and skin excoriations. Laboratory results show a serum creatinine level of 3.4 mg/dL and a blood urea nitrogen level of 48 mg/dL. A renal biopsy is performed. Light microscopy of the tissue sample shows widespread narrowing of the renal arterioles with deposition of homogeneous, glassy material in the subendothelial space that stains pink with periodic acid-Schiff (PAS) stain. This patient most likely has which of the following underlying conditions?

- A. Atheroembolic renal disease
- B. Diabetes mellitus
- C. Malignant hypertension
- D. Multiple myeloma
- E. Rapidly progressive glomerulonephritis

Submit

A 67-year-old man comes to the office due to generalized weakness, easy fatigability, anorexia, and intermittent nausea for the past several months. He also says that he is "itching and scratching a lot." Physical examination shows bilateral lower extremity pitting edema and skin excoriations. Laboratory results show a serum creatinine level of 3.4 mg/dL and a blood urea nitrogen level of 48 mg/dL. A renal biopsy is performed. Light microscopy of the tissue sample shows widespread narrowing of the renal arterioles with deposition of homogeneous, glassy material in the subendothelial space that stains pink with periodic acid-Schiff (PAS) stain. This patient most likely has which of the following underlying conditions?

A. Atheroembolic renal disease (4%)

✓ B. Diabetes mellitus (52%)

C. Malignant hypertension (12%)

D. Multiple myeloma (16%)

E. Rapidly progressive glomerulonephritis (13%)

Omitted
Correct answer
B

52%
Answered correctly

02 secs
Time Spent

06/03/2020
Last Updated

Explanation

This patient's symptoms (eg, fatigue, weakness, itching) are most likely due to accumulation of uremia toxins secondary to progressive **chronic kidney disease**. His renal biopsy shows deposition of eosinophilic hyaline material in the intima and media of small arteries and arterioles, which is characteristic of **hyaline arteriolosclerosis**. It is typically seen in patients with untreated or poorly controlled **hypertension** (HTN) or **diabetes mellitus**. Chronic/repetitive endothelial injury caused by hemodynamic stress (in HTN) or hyperglycemia causes leakage of plasma constituents

This patient's symptoms (eg, fatigue, weakness, itching) are most likely due to accumulation of uremia toxins secondary to progressive **chronic kidney disease**. His renal biopsy shows deposition of eosinophilic hyaline material in the intima and media of small arteries and arterioles, which is characteristic of **hyaline arteriolosclerosis**. It is typically seen in patients with untreated or poorly controlled **hypertension** (HTN) or **diabetes mellitus**. Chronic/repetitive endothelial injury caused by hemodynamic stress (in HTN) or hyperglycemia causes leakage of plasma constituents across the vascular endothelium and stimulates smooth muscle cell (SMC) proliferation and excessive extracellular matrix production. In diabetics, development of hyaline arteriolosclerosis is related not only to the duration of the disease but also to the degree of any concomitant hypertension.

**(Choice A)** Atheroembolic renal disease typically occurs after manipulation of the aorta (eg, abdominal aortic aneurysm repair) in adults with widespread atherosclerosis. Atheroemboli with cholesterol clefts are seen within the arterial lumen.

**(Choice C)** Malignant hypertension (extreme or rapidly developing hypertension) causes fibrinoid necrosis and hyperplastic arteriolosclerosis. Fibrinoid necrosis is characterized by localized destruction of the vascular wall with a circumferential ring of pink, amorphous material surrounding the lumen. Hyperplastic arteriolosclerosis consists of onion-like, concentric thickening of the walls of arterioles due to laminated layers of SMCs with intervening basement membrane reduplication (onion skinning). This patient's lack of concentric SMC thickening and absence of vascular necrosis are more suggestive of hyaline arteriolosclerosis.

**(Choice D)** Nephropathy in multiple myeloma is most often due to excess excretion of free light chains (Bence Jones proteins) that precipitate with Tamm-Horsfall protein to form obstructing tubular casts (cast nephropathy). These casts are seen as amorphous hyaline material in the tubular lumen.

**(Choice E)** Rapidly progressive glomerulonephritis (RPGN), including the idiopathic variety, may occur in the absence of a systemic vasculitic syndrome. Therefore, a patient with RPGN need not have renal arteriolar lesions.

**Educational objective:**
Homogeneous deposition of eosinophilic hyaline material in the intima and media of small arteries and arterioles characterizes hyaline arteriolosclerosis. This is typically produced by untreated or poorly controlled hypertension and/or diabetes.

Pathology | Renal, Urinary Systems & Electrolytes | Hypertensive nephropathy

**mellitus**. Chronic/repetitive endothelial injury caused by hemodynamic stress (in HTN) or hyperglycemia causes leakage of plasma constituents across the vascular endothelium and stimulates smooth muscle cell (SMC) proliferation and excessive extracellular matrix production. In diabetics, development of hyaline arteriolosclerosis is related not only to the duration of the disease but also to the degree of any concomitant hypertension.

**(Choice A)** Atheroembolic renal disease typically occurs after manipulation of the aorta (eg, abdominal aortic aneurysm repair) in adults with widespread atherosclerosis. Atheroemboli with cholesterol clefts are seen within the arterial lumen.

**(Choice C)** Malignant hypertension (extreme or rapidly developing hypertension) causes fibrinoid necrosis and hyperplastic arteriolosclerosis. Fibrinoid necrosis is characterized by localized destruction of the vascular wall with a circumferential ring of pink, amorphous material surrounding the lumen. Hyperplastic arteriolosclerosis consists of onion-like, concentric thickening of the walls of arterioles due to laminated layers of SMCs with intervening basement membrane reduplication (onion skinning). This patient's lack of concentric SMC thickening and absence of vascular necrosis are more suggestive of hyaline arteriolosclerosis.

**(Choice D)** Nephropathy in multiple myeloma is most often due to excess excretion of free light chains (Bence Jones proteins) that precipitate with Tamm-Horsfall protein to form obstructing tubular casts (cast nephropathy). These casts are seen as amorphous hyaline material in the tubular lumen.

**(Choice E)** Rapidly progressive glomerulonephritis (RPGN), including the idiopathic variety, may occur in the absence of a systemic vasculitic syndrome. Therefore, a patient with RPGN need not have renal arteriolar lesions.

**Educational objective:**
Homogeneous deposition of eosinophilic hyaline material in the intima and media of small arteries and arterioles characterizes hyaline arteriolosclerosis. This is typically produced by untreated or poorly controlled hypertension and/or diabetes.

| Pathology | Renal, Urinary Systems & Electrolytes | Hypertensive nephropathy |
|---|---|---|
| Subject | System | Topic |

Copyright © UWorld. All rights reserved.

Settings

1 2 3 4 5 6 7 8 9 10 11 12 13 14 15 16 17 18 19 20 21 22 23 24 25 26 27 28 29 30

Item 12 of 39
Question Id: 455

Mark | Previous | Next | Full Screen | Tutorial | Lab Values | Notes | Calculator | Reverse Color | Text Zoom | Settings

mellitus. Chronic/repetitive endothelial injury caused by hemodynamic stress (in HTN) or hyperglycemia causes leakage of plasma constituents

Exhibit Display

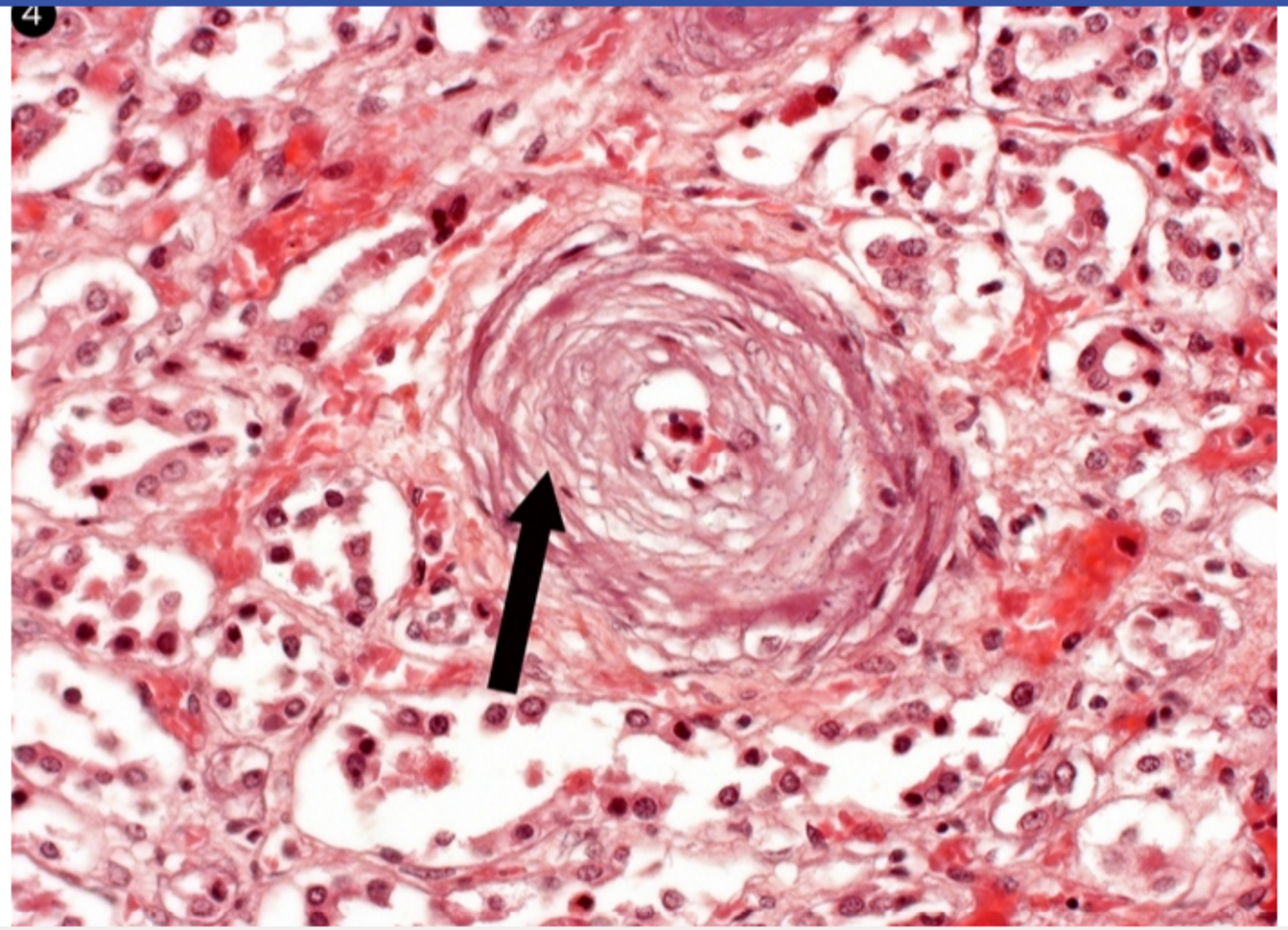

Zoom In | Zoom Out | Reset | Add To New Card | Existing Card

Block Time Remaining: 00:04:49
TUTOR

3 | Feedback | Suspend | End Block

A newborn undergoes an abdominal ultrasound that shows kidneys of normal size, structure, and location. The patient does not appear to be in distress and physical examination reveals no abnormalities. If this patient were to be diagnosed with renal disease later in life, it would most likely be which of the following?

- A. Autosomal recessive polycystic renal disease
- B. Autosomal dominant polycystic renal disease
- C. Cystic renal dysplasia
- D. Horseshoe kidney
- E. Potter syndrome

Submit

A newborn undergoes an abdominal ultrasound that shows kidneys of normal size, structure, and location. The patient does not appear to be in distress and physical examination reveals no abnormalities. If this patient were to be diagnosed with renal disease later in life, it would most likely be which of the following?

- A. Autosomal recessive polycystic renal disease (10%)
- ✓ B. Autosomal dominant polycystic renal disease (80%)
- C. Cystic renal dysplasia (7%)
- D. Horseshoe kidney (1%)
- E. Potter syndrome (0%)

Omitted
Correct answer
B

80%
Answered correctly

02 secs
Time Spent

03/11/2020
Last Updated

Explanation

| Autosomal dominant polycystic kidney disease | |
|---|---|
| Pathologic | • Mutations in PKD-1 or PKD-2 cause tubular cell proliferation and fluid secretion<br>• Cyst formation occurs at any point in the nephron, but < 5% of nephrons are affected |

| Autosomal dominant polycystic kidney disease | |
|---|---|
| **Pathologic features** | • Mutations in PKD-1 or PKD-2 cause tubular cell proliferation and fluid secretion<br>• Cyst formation occurs at any point in the nephron, but < 5% of nephrons are affected<br>• Microscopic cysts present at birth progressively enlarge over the decades<br>• Enlarged cysts compress the renal parenchyma, causing atrophy and fibrosis |
| **Clinical features** | • Frequently clinically silent, with 50% of patients going undiagnosed<br>• Symptoms are variable and include flank pain, hematuria, and hypertension<br>• Renal failure slowly progresses over 10-20 years, with end-stage renal disease often occurring by age 70<br>• Extrarenal manifestations include liver cysts and cerebral aneurysms |

©USMLEWorld, LLC

Autosomal dominant polycystic kidney disease (ADPKD), like many autosomal dominant diseases, manifests later in life. Microscopic cysts are present at birth but are too small to be detected by abdominal ultrasound. Over the years, the cysts enlarge, compression of the renal parenchyma occurs, and patients become symptomatic.

**(Choice A)** Autosomal recessive polycystic kidney disease (ARPKD) presents at birth or during the first year of life with bilateral flank masses. Cysts are formed by dilated distal tubules and collecting ducts. Abdominal ultrasonography demonstrates enlarged kidneys at birth and also shows cysts if they are >1 cm in diameter.

**(Choice C)** Multicystic kidney dysplasia is characterized by the presence of multiple cysts of varying size in the kidney and the *absence of a*

Autosomal dominant polycystic kidney disease (ADPKD), like many autosomal dominant diseases, manifests later in life. Microscopic cysts are present at birth but are too small to be detected by abdominal ultrasound. Over the years, the cysts enlarge, compression of the renal parenchyma occurs, and patients become symptomatic.

**(Choice A)** Autosomal recessive polycystic kidney disease (ARPKD) presents at birth or during the first year of life with bilateral flank masses. Cysts are formed by dilated distal tubules and collecting ducts. Abdominal ultrasonography demonstrates enlarged kidneys at birth and also shows cysts if they are >1 cm in diameter.

**(Choice C)** Multicystic kidney dysplasia is characterized by the presence of multiple cysts of varying size in the kidney and the *absence of a normal pelvocaliceal system*. The condition is associated with ureteral or ureteropelvic atresia, with the affected kidney essentially rendered nonfunctional. Abdominal ultrasound of the fetus or newborn is diagnostic.

**(Choice D)** The abnormal fusion of kidneys at their poles (usually, the lower poles) is called horseshoe kidney. The isthmus of renal tissue is anterior to the great vessels and is easily detected on abdominal ultrasound.

**(Choice E)** A number of fetal renal abnormalities (eg, bilateral renal agenesis, ARPKD) can cause a decrease in fetal urine production and oligohydramnios. The combination of abnormalities that ensues, called Potter syndrome, includes pulmonary hypoplasia, Potter facies (flattened nose, recessed chin, prominent epicanthal folds, and low-set ears), limb defects, and cardiovascular abnormalities. Renal defects that lead to Potter syndrome are usually profound and would be easily seen on ultrasound.

**Educational objective:**
Autosomal dominant polycystic kidney disease manifests in patients 40-50 years old with enlarged kidneys, hypertension, and renal failure. In newborns, the kidneys are of normal size, and the cysts are too small to be detected on abdominal ultrasonography. As the cysts enlarge, they compress the renal parenchyma and cause symptoms.

**References**

- Polycystic kidney disease: inheritance, pathophysiology, prognosis, and treatment.

| Pathology | Renal, Urinary Systems & Electrolytes | Polycystic kidney disease |
|---|---|---|
| Subject | System | Topic |

parenchyma occurs, and patients become symptomatic.

**(Choice A)** Autosomal recessive polycystic kidney disease (ARPKD) presents at birth or during the first year of life with bilateral flank masses. Cysts are formed by dilated distal tubules and collecting ducts. Abdominal ultrasonography demonstrates enlarged kidneys at birth and also shows cysts if they are >1 cm in diameter.

**(Choice C)** Multicystic kidney dysplasia is characterized by the presence of multiple cysts of varying size in the kidney and the *absence of a normal pelvocaliceal system*. The condition is associated with ureteral or ureteropelvic atresia, with the affected kidney essentially rendered nonfunctional. Abdominal ultrasound of the fetus or newborn is diagnostic.

**(Choice D)** The abnormal fusion of kidneys at their poles (usually, the lower poles) is called horseshoe kidney. The isthmus of renal tissue is anterior to the great vessels and is easily detected on abdominal ultrasound.

**(Choice E)** A number of fetal renal abnormalities (eg, bilateral renal agenesis, ARPKD) can cause a decrease in fetal urine production and oligohydramnios. The combination of abnormalities that ensues, called Potter syndrome, includes pulmonary hypoplasia, Potter facies (flattened nose, recessed chin, prominent epicanthal folds, and low-set ears), limb defects, and cardiovascular abnormalities. Renal defects that lead to Potter syndrome are usually profound and would be easily seen on ultrasound.

**Educational objective:**

Autosomal dominant polycystic kidney disease manifests in patients 40-50 years old with enlarged kidneys, hypertension, and renal failure. In newborns, the kidneys are of normal size, and the cysts are too small to be detected on abdominal ultrasonography. As the cysts enlarge, they compress the renal parenchyma and cause symptoms.

**References**

- Polycystic kidney disease: inheritance, pathophysiology, prognosis, and treatment.

| Pathology | Renal, Urinary Systems & Electrolytes | Polycystic kidney disease |
|---|---|---|
| Subject | System | Topic |

Copyright © UWorld. All rights reserved.

Settings

1 2 3 4 5 6 7 8 9 10 11 12 13 14 15 16 17 18 19 20 21 22 23 24 25 26 27 28 29 30

Item 13 of 39
Question Id: 1052

Mark | Previous | Next | Full Screen | Tutorial | Lab Values | Notes | Calculator | Reverse Color | Text Zoom | Settings

parenchyma occurs, and patients become symptomatic.

Exhibit Display

Zoom In | Zoom Out | Reset | Add To New Card | Existing Card

Block Time Remaining: 00:04:51
TUTOR

2 | Feedback | Suspend | End Block

The following vignette applies to the next **2** items. The items in the set must be answered in sequential order. Once you click **Proceed to Next Item**, you will not be able to add or change an answer.

A 54-year-old previously healthy man comes to the office due to several weeks of leg swelling. He has had no fever, chest pain, or dyspnea. The patient has a 40-pack-year smoking history but does not use alcohol or illicit drugs. He is afebrile and vital signs are within normal limits. On physical examination, there is symmetric pitting edema of the lower extremities bilaterally. The abdomen is soft and nondistended. A mobile left flank mass can be palpated. There are several vertically oriented tortuous veins on the lower abdominal wall.

**Item 1 of 2**

Which of the following structures is most likely obstructed in this patient?

- A. Femoral veins
- B. Iliac veins
- C. Inferior vena cava
- D. Portal vein
- E. Saphenous veins

Submit

1 2 3 4 5 6 7 8 9 10 11 12 13 14 15 16 17 18 19 20 21 22 23 24 25 26 27 28 29 30

The following vignette applies to the next **2** items. The items in the set must be answered in sequential order. Once you click **Proceed to Next Item**, you will not be able to add or change an answer.

A 54-year-old previously healthy man comes to the office due to several weeks of leg swelling. He has had no fever, chest pain, or dyspnea. The patient has a 40-pack-year smoking history but does not use alcohol or illicit drugs. He is afebrile and vital signs are within normal limits. On physical examination, there is symmetric pitting edema of the lower extremities bilaterally. The abdomen is soft and nondistended. A mobile left flank mass can be palpated. There are several vertically oriented tortuous veins on the lower abdominal wall.

**Item 1 of 2**

Which of the following structures is most likely obstructed in this patient?

A. Femoral veins (3%)

B. Iliac veins (17%)

✓ C. Inferior vena cava (37%)

D. Portal vein (38%)

E. Saphenous veins (2%)

Omitted
Correct answer
C

37%
Answered correctly

02 secs
Time Spent

01/27/2020
Last Updated

Explanation

Settings

1
2
3
4
5
6
7
8
9
10
11
12
13
14
15
16
17
18
19
20
21
22
23
24
25
26
27
28
29
30

Item 14 of 39
Question Id: 7226

Mark

Previous | Next | Full Screen | Tutorial | Lab Values | Notes | Calculator | Reverse Color | Text Zoom | Settings

## Renal cell carcinoma & IVC obstruction

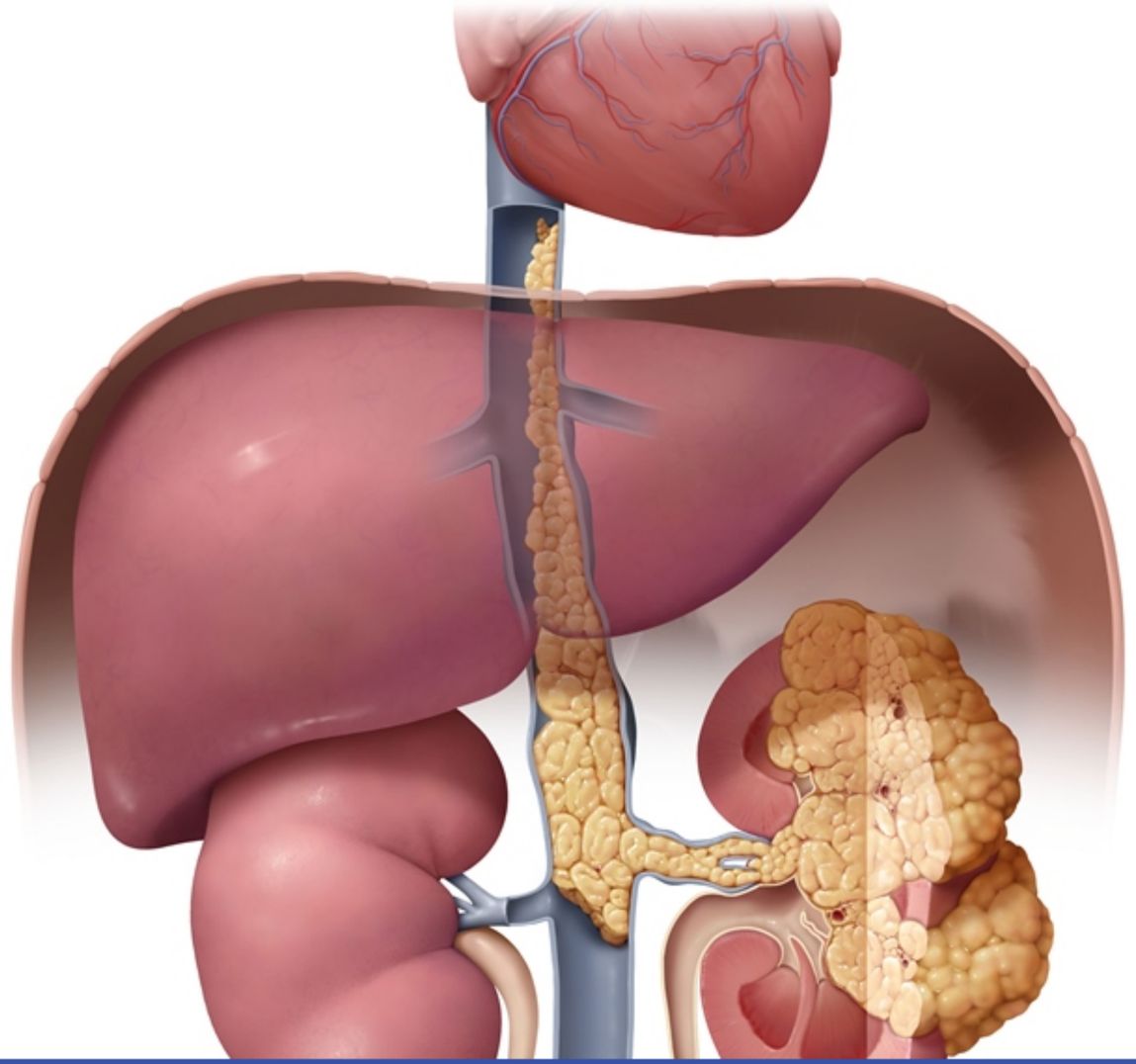

Block Time Remaining: 00:04:53
TUTOR

2 | Feedback | Suspend | End Block

1 2 3 4 5 6 7 8 9 10 11 12 13 14 15 16 17 18 19 20 21 22 23 24 25 26 27 28 29 30

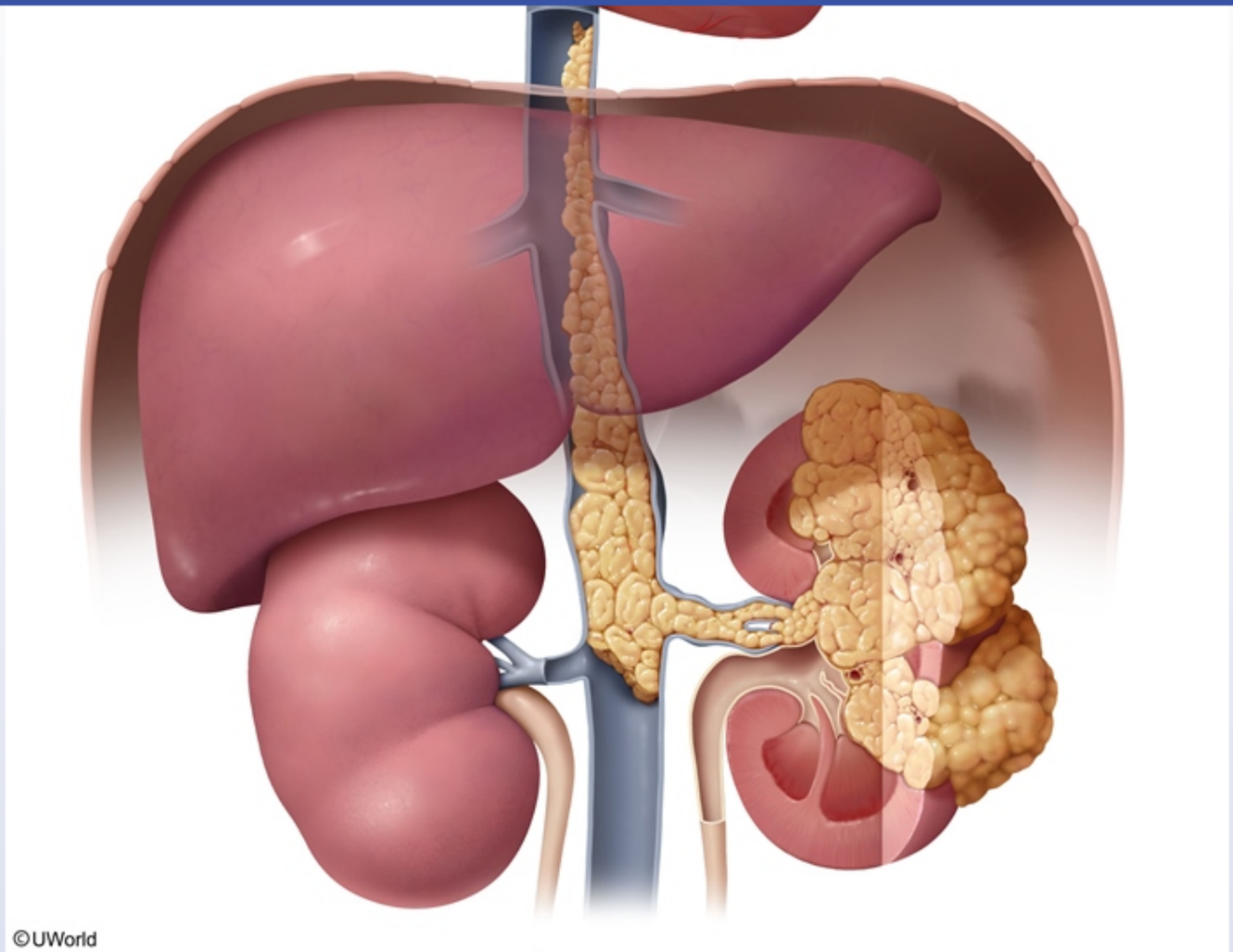


This patient's symmetric bilateral lower extremity pitting edema and tortuous abdominal veins are concerning for an **inferior vena cava (IVC) obstruction**, which, in the setting of a left-sided flank mass, suggests **renal cell carcinoma** (RCC) with extension into the IVC. RCC accounts for >90% of all malignancies arising in the kidney and is highly associated with smoking. Patients with RCC classically have a triad of flank pain,

This patient's symmetric bilateral lower extremity pitting edema and tortuous abdominal veins are concerning for an **inferior vena cava (IVC) obstruction**, which, in the setting of a left-sided flank mass, suggests **renal cell carcinoma** (RCC) with extension into the IVC. RCC accounts for >90% of all malignancies arising in the kidney and is highly associated with smoking. Patients with RCC classically have a triad of flank pain, palpable mass, and hematuria, although many remain asymptomatic until the disease is advanced.

RCC is a highly vascular tumor that **invades the renal vein** in up to 25% of cases. IVC obstruction can occur due to intraluminal extension and thrombus formation, rather than mass effect from the tumor itself. The obstruction can occur acutely or gradually over time. In chronic cases, collateral venous circulation may develop based on the site of the obstruction. Prominent abdominal wall **collateral veins**, as in this patient, suggest obstruction of the upper segment of the IVC.

**(Choices A, B, and E)** The femoral, iliac, and saphenous veins are too low in the legs to produce significant abdominal wall collateral veins if obstructed. Obstruction of these veins would be more likely to cause varices on the legs, thighs, and hips. In addition, unilateral (rather than bilateral) lower extremity edema would be expected.

**(Choice D)** Obstruction of the portal vein is most commonly associated with severe hepatic cirrhosis. Affected patients have shunting of blood through portocaval anastomoses, leading to hemorrhoids, esophageal varices, and caput medusae about the umbilicus. They may also have ascites.

**Educational objective:**
Renal cell carcinoma tends to invade the renal vein; inferior vena cava obstruction can occur by intraluminal extension of the tumor. Obstruction of the inferior vena cava produces symmetric bilateral lower extremity edema, often associated with prominent development of venous collaterals in the abdominal wall.

**References**

- Important surgical considerations in the management of renal cell carcinoma (RCC) with inferior vena cava (IVC) tumour thrombus.

| Pathology | Renal, Urinary Systems & Electrolytes | Renal cell carcinoma |
|---|---|---|
| Subject | System | Topic |

Copyright © UWorld. All rights reserved.

**Item 2 of 2**

Further evaluation of the patient reveals microscopic hematuria. Laboratory results are as follows:

| | |
|---|---|
| Leukocytes | 9,000/mm$^3$ |
| Hemoglobin | 19.2 g/dL |
| Platelets | 230,000/mm$^3$ |

Which of the following is the most likely cause of this patient's hematologic findings?

- A. Arteriovenous malformation
- B. Excess erythropoietin production
- C. Extramedullary hematopoiesis
- D. Myeloproliferative disorder
- E. Reduced plasma volume

Submit

**Item 2 of 2**

Further evaluation of the patient reveals microscopic hematuria. Laboratory results are as follows:

| | |
|---|---|
| Leukocytes | 9,000/mm$^3$ |
| Hemoglobin | 19.2 g/dL |
| Platelets | 230,000/mm$^3$ |

Which of the following is the most likely cause of this patient's hematologic findings?

A. Arteriovenous malformation (1%)
✓ B. Excess erythropoietin production (78%)
C. Extramedullary hematopoiesis (5%)
D. Myeloproliferative disorder (8%)
E. Reduced plasma volume (5%)

Omitted
Correct answer
B

78%
Answered correctly

02 secs
Time Spent

01/27/2020
Last Updated

Explanation

This patient most likely has **renal cell carcinoma** with an elevated hemoglobin level suggestive of erythrocytosis. Renal cell carcinoma causes a

## Explanation

This patient most likely has **renal cell carcinoma** with an elevated hemoglobin level suggestive of erythrocytosis. Renal cell carcinoma causes a variety of paraneoplastic syndromes. **Erythrocytosis** is an uncommon but classic finding and is the result of excessive erythropoietin production by the renal cell tumor. Hypercalcemia may also occur due to overproduction of parathyroid hormone–related peptide or from lytic bone metastases.

**(Choice A)** Arteriovenous malformations have been associated with high-output cardiac failure, local bony hypertrophy, and local tissue compression and distortion. These lesions are typically congenital although they may not become clinically evident until puberty.

**(Choice C)** When intramedullary hematopoiesis is insufficient, blood cell formation can sometimes occur in extramedullary sites such as the liver, spleen, and thymus, resulting in enlargement of these organs. Extramedullary hematopoiesis typically occurs in the setting of myelofibrosis.

**(Choice D)** Myeloproliferative disorders such as polycythemia vera typically cause increases in all cell lines (leukocytosis and thrombocytosis would also be expected).

**(Choice E)** Reduced plasma volume can cause a pseudo-elevation in hemoglobin/hematocrit levels. However, hemoconcentration typically causes this pseudo-elevation in all cell lines. In addition, there is no other indication of a reduced plasma volume, and in this clinical setting, erythropoietin overproduction from a renal tumor is more likely.

**Educational objective:**
Renal cell carcinoma causes a variety of paraneoplastic syndromes including erythrocytosis (due to excessive erythropoietin production) and hypercalcemia (due to parathyroid hormone–related peptide).

| Pathology | Renal, Urinary Systems & Electrolytes | Renal cell carcinoma |
|---|---|---|
| Subject | System | Topic |

Copyright © UWorld. All rights reserved.

A 60-year-old woman comes to the emergency department due to left flank pain and hematuria. Medical history is significant for recurrent urinary tract infections and hypothyroidism. Blood pressure is 130/80 mm Hg and pulse is 80/min. Physical examination shows left flank tenderness. CT scan of the abdomen is shown below:

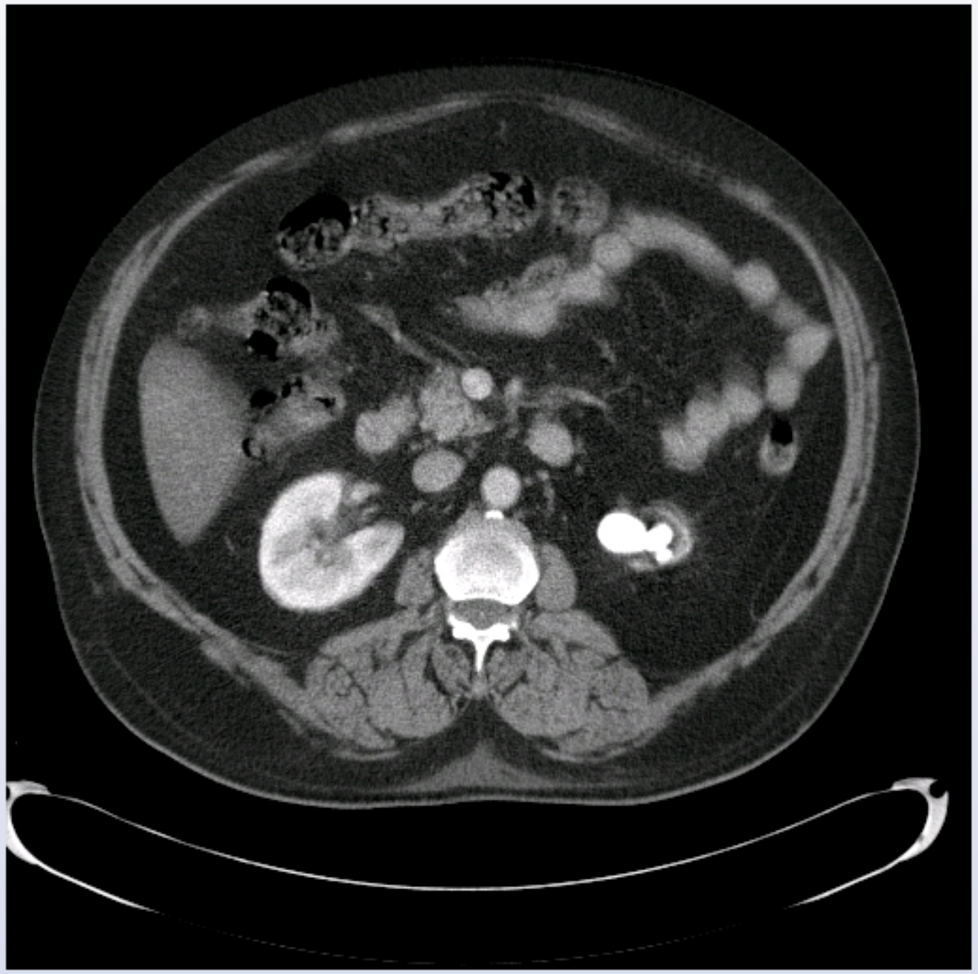

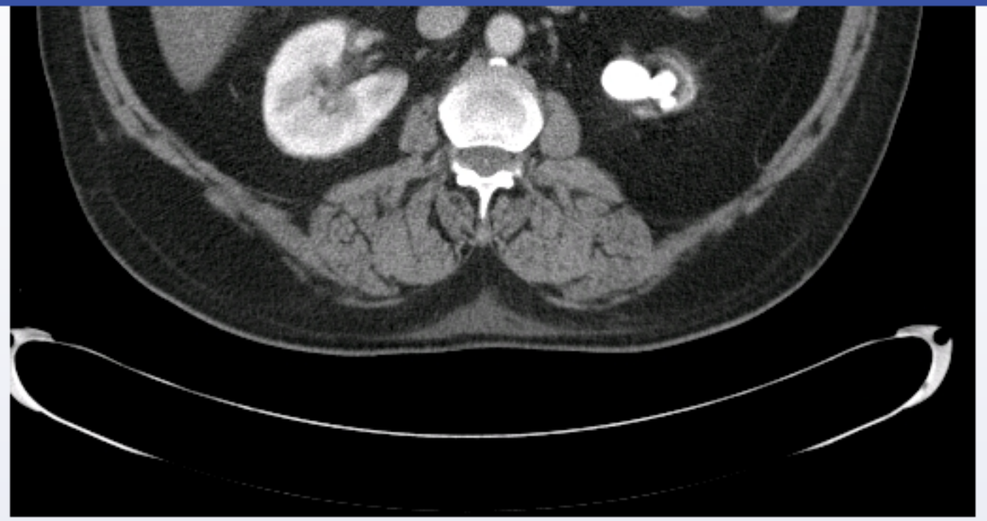

Urinalysis for this patient would most likely show which of the following?

- A. 4+ protein
- B. Numerous eosinophils
- C. pH 8.0
- D. Red blood cell casts
- E. Specific gravity 1.002
- F. Uric acid crystals

Submit

1 2 3 4 5 6 7 8 9 10 11 12 13 14 15 16 17 18 19 20 21 22 23 24 25 26 27 28 29 30

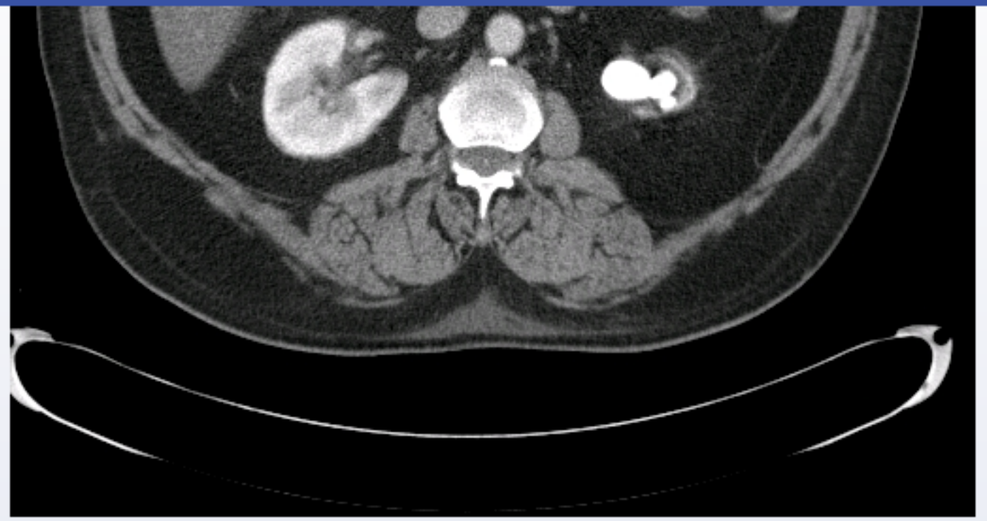

Urinalysis for this patient would most likely show which of the following?

- A. 4+ protein (4%)
- B. Numerous eosinophils (3%)
- ✓ C. pH 8.0 (50%)
- D. Red blood cell casts (21%)
- E. Specific gravity 1.002 (4%)
- F. Uric acid crystals (15%)

Omitted
Correct answer

50%
Answered correctly

04 secs
Time Spent

03/31/2020
Last Updated

Explanation

| Struvite (magnesium ammonium phosphate) stones | |
|---|---|
| **Risk factors** | • Recurrent upper urinary tract infection<br>• Urease-producing organisms (eg, *Klebsiella*, *Proteus*) |
| **Pathogenesis** | • Hydrolysis of urea to yield ammonia:<br>Urea $\rightarrow 2\ NH_3 + CO_2$<br>$NH_3 + H_2O \rightarrow NH_4^+ + OH^-$<br>• Increased urine pH<br>• Precipitation of magnesium ammonium phosphate salts |
| **Clinical features** | • Large staghorn calculi<br>• Fever, mild flank pain due to infection<br>• Obstruction of collecting system & atrophy of renal parenchyma |

This patient's imaging shows an atrophic left kidney associated with a large, hyperdense mass filling the renal pelvis. These findings are consistent with a chronic staghorn calculus, a type of kidney stone that occurs in patients with recurrent upper urinary tract infection caused by **urease-producing organisms** (eg, *Proteus*, *Klebsiella*). Hydrolysis of urea yields **ammonia**, which **alkalinizes the urine** (ie, pH >7) and facilitates precipitation of struvite crystals (magnesium ammonium phosphate).

Because of the large quantities of urea excreted in urine, struvite stones can **grow rapidly** into a branched staghorn calculus that **fills the renal calyces and pelvis**. Symptoms are usually related to the underlying infection (eg, fever, mild costovertebral pain, hematuria); renal colic (ie, severe flank/groin pain) is uncommon because large stones are unable to pass into the ureter and cause acute obstruction. Over time, the affected **kidney can atrophy** due to recurrent infection and chronic obstructive nephropathy.

**(Choice A)** Trace or weakly positive (eg, 1 or 2+) proteinuria can be seen in a variety of disorders (eg, hematuria due to kidney stones, urinary tract infection) due to disruption of the urothelium; however, a strongly positive result (eg, 3 or 4+) is more specific for glomerular protein loss (eg, amyloidosis, diabetic nephropathy) and is not usually due to stones.

| | |
|---|---|
| | • Obstruction of collecting system & atrophy of renal parenchyma |

This patient's imaging shows an atrophic left kidney associated with a large, hyperdense mass filling the renal pelvis. These findings are consistent with a chronic staghorn calculus, a type of kidney stone that occurs in patients with recurrent upper urinary tract infection caused by **urease-producing organisms** (eg, *Proteus*, *Klebsiella*). Hydrolysis of urea yields **ammonia**, which **alkalinizes the urine** (ie, pH >7) and facilitates precipitation of struvite crystals (magnesium ammonium phosphate).

Because of the large quantities of urea excreted in urine, struvite stones can **grow rapidly** into a branched staghorn calculus that **fills the renal calyces and pelvis**. Symptoms are usually related to the underlying infection (eg, fever, mild costovertebral pain, hematuria); renal colic (ie, severe flank/groin pain) is uncommon because large stones are unable to pass into the ureter and cause acute obstruction. Over time, the affected **kidney can atrophy** due to recurrent infection and chronic obstructive nephropathy.

**(Choice A)** Trace or weakly positive (eg, 1 or 2+) proteinuria can be seen in a variety of disorders (eg, hematuria due to kidney stones, urinary tract infection) due to disruption of the urothelium; however, a strongly positive result (eg, 3 or 4+) is more specific for glomerular protein loss (eg, amyloidosis, diabetic nephropathy) and is not usually due to stones.

**(Choice B)** Eosinophiluria is typically associated with acute interstitial nephritis, which is most commonly triggered by exposure to certain medications (eg, beta-lactam antibiotics, nonsteroidal anti-inflammatory drugs). Patients typically have a rash, fever, and acute kidney injury, but this condition is not associated with staghorn calculi.

**(Choice D)** Red cell casts and dysmorphic red blood cells form when erythrocytes traverse the renal tubules and indicate a glomerular bleeding source (eg, glomerulonephritis). Staghorn calculi can cause hematuria with morphologically normal red cells due to irritation of the urothelium, but do not cause glomerular bleeding.

**(Choice E)** Urine specific gravity correlates with urine concentration and is influenced by hydration status and regulatory hormone (eg, antidiuretic hormone) levels. Kidney stones most commonly form in concentrated urine (eg, >1.015), which results in supersaturation of salts and crystal precipitation. A specific gravity of ≤1.003 indicates dilute urine, and it is unlikely that a patient with an acute stone would have such a low specific gravity.

**(Choice F)** Uric acid stones can occasionally form staghorn calculi but would typically be seen in patients with gout or conditions with rapid cell turnover (eg, myeloproliferative disorders) rather than recurrent urinary tract infection. This patient is much more likely to have a struvite stone.

Settings

1 2 3 4 5 6 7 8 9 10 11 12 13 14 15 16 17 18 19 20 21 22 23 24 25 26 27 28 29 30

Item 16 of 39
Question Id: 15259

Mark | Previous | Next | Full Screen | Tutorial | Lab Values | Notes | Calculator | Reverse Color | Text Zoom | Settings

- Obstruction of collecting system & atrophy of renal parenchyma

Exhibit Display

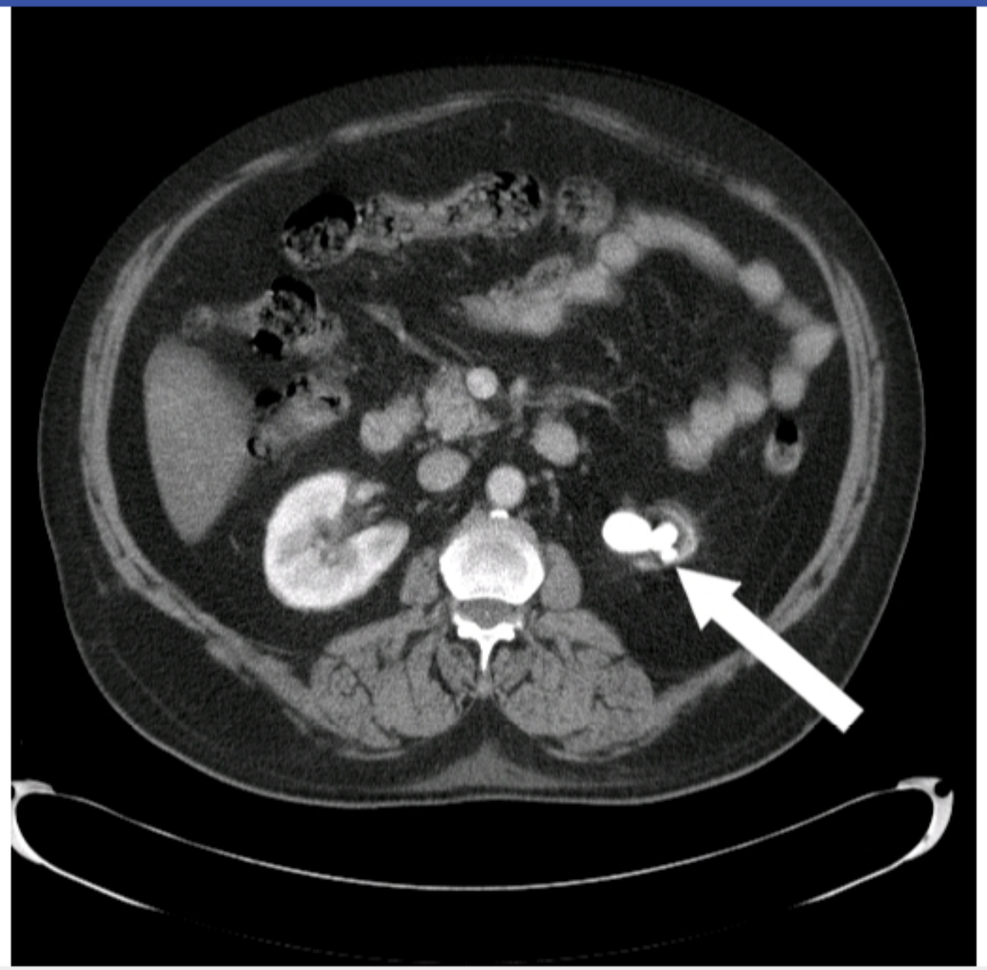

Zoom In | Zoom Out | Reset | Add To New Card | Existing Card

turnover (eg, myeloproliferative disorders) rather than recurrent urinary tract infection. This patient is much more likely to have a struvite stone.

Block Time Remaining: 00:04:59
TUTOR

5 | Feedback | Suspend | End Block

1 2 3 4 5 6 7 8 9 10 11 12 13 14 15 16 17 18 19 20 21 22 23 24 25 26 27 28 29 30

| | |
|---|---|
| | • Obstruction of collecting system & atrophy of renal parenchyma |

**Exhibit Display**

**Triple phosphate**
**(magnesium ammonium phosphate)**



©UWorld

Zoom In | Zoom Out | Reset | Add To New Card | Existing Card

turnover (eg, myeloproliferative disorders) rather than recurrent urinary tract infection. This patient is much more likely to have a struvite stone.

amyloidosis, diabetic nephropathy) and is not usually due to stones.

**(Choice B)** Eosinophiluria is typically associated with acute interstitial nephritis, which is most commonly triggered by exposure to certain medications (eg, beta-lactam antibiotics, nonsteroidal anti-inflammatory drugs). Patients typically have a rash, fever, and acute kidney injury, but this condition is not associated with staghorn calculi.

**(Choice D)** Red cell casts and dysmorphic red blood cells form when erythrocytes traverse the renal tubules and indicate a glomerular bleeding source (eg, glomerulonephritis). Staghorn calculi can cause hematuria with morphologically normal red cells due to irritation of the urothelium, but do not cause glomerular bleeding.

**(Choice E)** Urine specific gravity correlates with urine concentration and is influenced by hydration status and regulatory hormone (eg, antidiuretic hormone) levels. Kidney stones most commonly form in concentrated urine (eg, >1.015), which results in supersaturation of salts and crystal precipitation. A specific gravity of ≤1.003 indicates dilute urine, and it is unlikely that a patient with an acute stone would have such a low specific gravity.

**(Choice F)** Uric acid stones can occasionally form staghorn calculi but would typically be seen in patients with gout or conditions with rapid cell turnover (eg, myeloproliferative disorders) rather than recurrent urinary tract infection. This patient is much more likely to have a struvite stone.

**Educational objective:**
Struvite stones are typically seen in patients with recurrent upper urinary infection by urease-producing organisms (eg, *Proteus*, *Klebsiella*). Hydrolysis of urea yields ammonia, which alkalinizes the urine and facilitates precipitation of magnesium ammonium phosphate. Urinalysis shows hematuria and elevated urine pH.

**References**

- Renal struvite stones—pathogenesis, microbiology, and management strategies.

| Pathology | Renal, Urinary Systems & Electrolytes | Renal calculi |
|---|---|---|
| Subject | System | Topic |

Copyright © UWorld. All rights reserved.

A 68-year-old woman comes to the office due to increasing low back pain. The pain is constant and worsens at night. She has also had a 6.8-kg (15-lb) weight loss over the past 3 months. Medical history is significant for osteoporosis and hypothyroidism. Family history is significant for breast cancer in her mother. She has smoked 1 pack of cigarettes daily for 30 years and drinks 1 or 2 glasses of wine every day. The patient immigrated to the United States from China 30 years ago; she mainly eats food she cooks herself. Vital signs are within normal limits. Physical examination shows point tenderness over the L3 and L4 vertebrae. MRI reveals lytic bone lesions in the corresponding vertebrae and also a right lower pole kidney mass. Histologic examination of the mass is shown below:

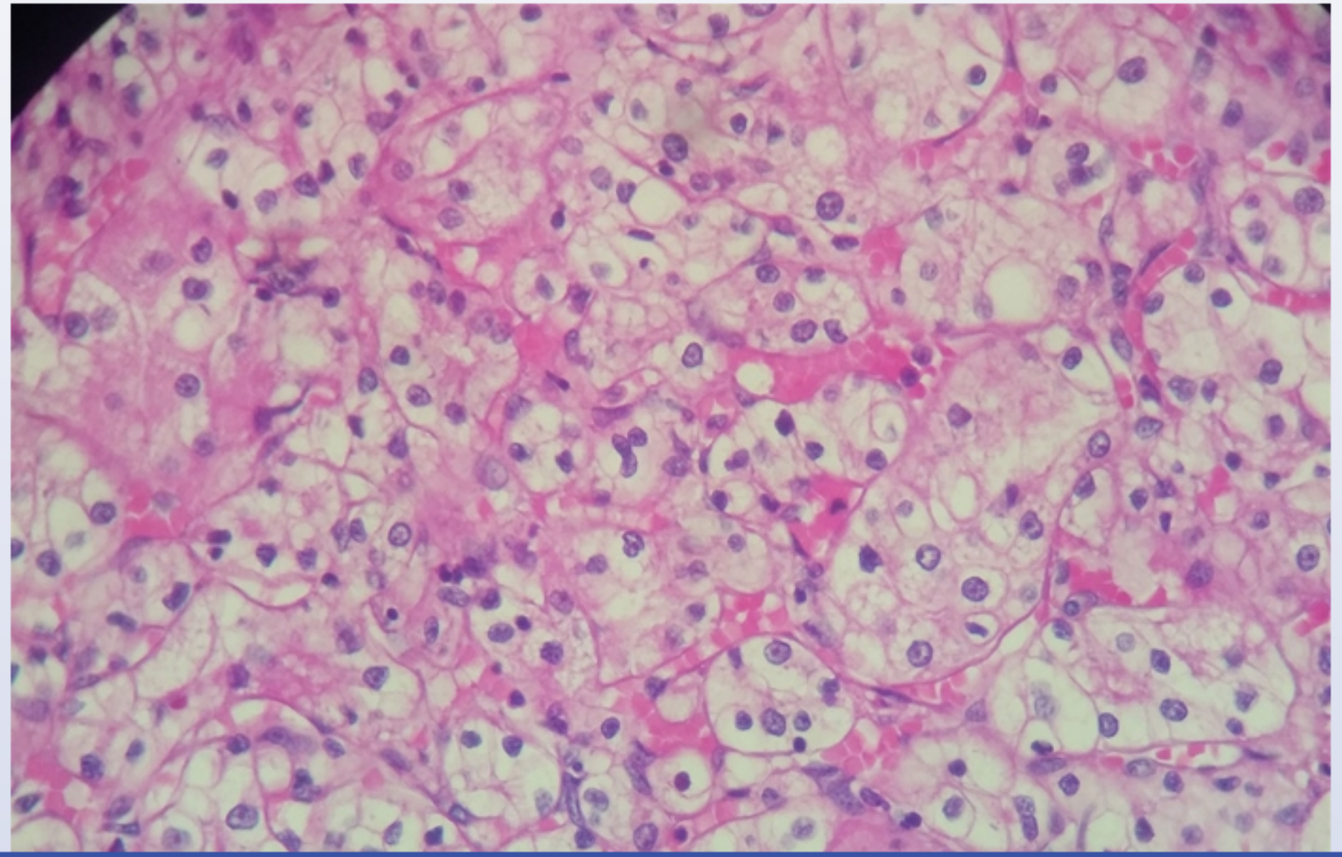

1 2 3 4 5 6 7 8 9 10 11 12 13 14 15 16 17 18 19 20 21 22 23 24 25 26 27 28 29 30

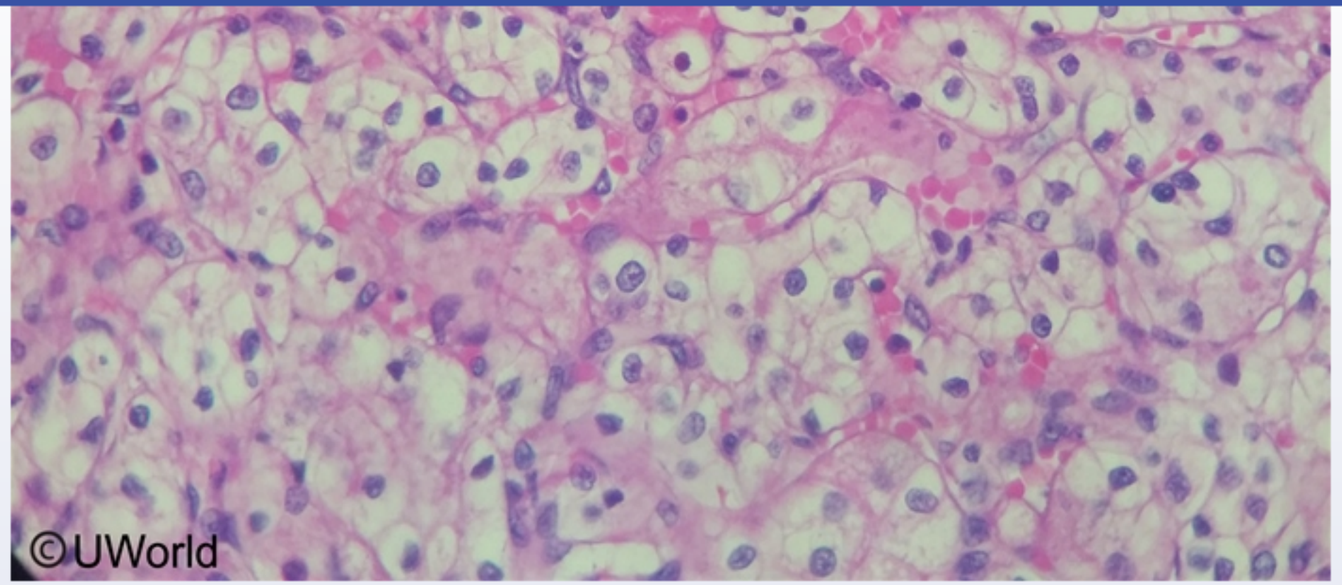


Which of the following is the most important risk factor for this patient's current condition?

- A. Alcohol use
- B. Diet
- C. Ethnicity
- D. Family history
- E. Smoking

Submit

1 2 3 4 5 6 7 8 9 10 11 12 13 14 15 16 17 18 19 20 21 22 23 24 25 26 27 28 29 30

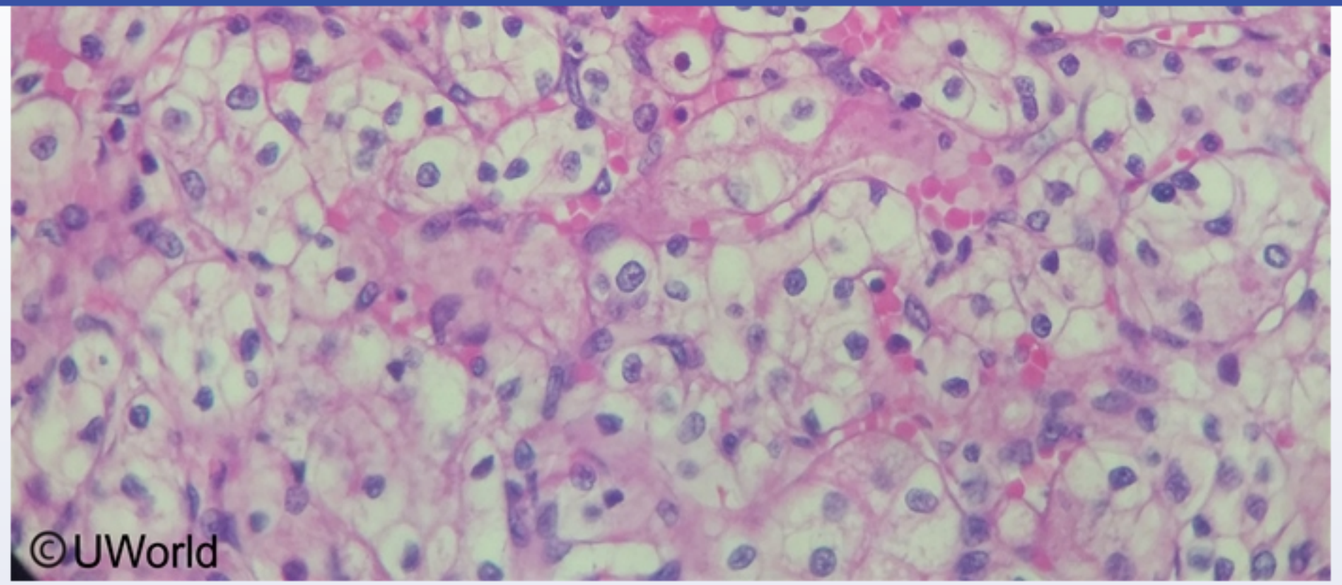


Which of the following is the most important risk factor for this patient's current condition?

A. Alcohol use (1%)

B. Diet (2%)

C. Ethnicity (2%)

D. Family history (8%)

✓ E. Smoking (85%)

Omitted
Correct answer

85%
Answered correctly

05 secs
Time Spent

04/13/2020
Last Updated

Explanation

| Renal cell carcinoma | |
|---|---|
| **Presentation** | • Hematuria, flank pain, palpable abdominal mass<br>• Paraneoplastic syndrome (eg, polycythemia, hypercalcemia) |
| **Risk factors** | • Smoking, hypertension, obesity<br>• Toxin exposure (eg, heavy metal, petroleum by-products) |
| **Gross examination** | • Spherical mass, often with invasion of the renal vein<br>• Golden-yellow tissue (due to high lipid content) |
| **Histology**<br>(Clear cell) | • Cuboidal or polygonal cells with abundant, clear cytoplasm<br>• Branching, "chicken-wire" vasculature |

This patient with back pain, osteolytic bone lesions, and histology demonstrating rounded, **polygonal clear cells** with eccentric nuclei has metastatic **renal cell carcinoma** (RCC). RCC is often asymptomatic until the disease is advanced, and many patients have metastatic disease at the time of diagnosis. Symptoms often include some combination of hematuria, abdominal mass, or flank pain; however, this classic triad occurs in <10% of cases. Systemic symptoms (eg, fever, weight loss, fatigue) and symptoms related to metastases (eg, bone pain) are common.

Risk factors for RCC include **smoking**, toxin exposure (eg, trichloroethylene, asbestos, petroleum by-products), obesity, and hypertension.

**(Choice A)** Alcohol use increases the risk of hepatocellular carcinoma and squamous cell carcinoma of the esophagus but is associated with a decreased risk of RCC.

**(Choice B)** Diets high in cured meat and salt-preserved foods (which are prevalent in some Asian populations) are associated with an increased risk of gastric cancer but not RCC.

**(Choice C)** Asian-American patients have a lower risk of RCC than other ethnicities. Individuals of Asian heritage are at increased risk of

This patient with back pain, osteolytic bone lesions, and histology demonstrating rounded, **polygonal clear cells** with eccentric nuclei has metastatic **renal cell carcinoma** (RCC). RCC is often asymptomatic until the disease is advanced, and many patients have metastatic disease at the time of diagnosis. Symptoms often include some combination of hematuria, abdominal mass, or flank pain; however, this classic triad occurs in <10% of cases. Systemic symptoms (eg, fever, weight loss, fatigue) and symptoms related to metastases (eg, bone pain) are common.

Risk factors for RCC include **smoking**, toxin exposure (eg, trichloroethylene, asbestos, petroleum by-products), obesity, and hypertension.

**(Choice A)** Alcohol use increases the risk of hepatocellular carcinoma and squamous cell carcinoma of the esophagus but is associated with a decreased risk of RCC.

**(Choice B)** Diets high in cured meat and salt-preserved foods (which are prevalent in some Asian populations) are associated with an increased risk of gastric cancer but not RCC.

**(Choice C)** Asian-American patients have a lower risk of RCC than other ethnicities. Individuals of Asian heritage are at increased risk of developing IgA nephropathy.

**(Choice D)** Von Hippel-Lindau disease is an autosomal dominant inherited disorder that can cause renal cell carcinoma, pheochromocytoma, and hemangioblastomas. It is not associated with breast cancer. A strong family history of breast cancer may be associated with *BRCA* gene positivity and places patients at higher risk for breast and ovarian cancers.

**Educational objective:**
Renal cell carcinoma may present with a combination of hematuria, abdominal mass, or flank pain; however, this triad occurs together in <10% of cases. Pathology demonstrates rounded, polygonal cells with a clear cytoplasm and eccentric nuclei. Risk factors include smoking, toxin exposure, and certain hereditary disorders (eg, von Hippel-Lindau syndrome).

| Pathology | Renal, Urinary Systems & Electrolytes | Renal cell carcinoma |
|---|---|---|
| Subject | System | Topic |

Copyright © UWorld. All rights reserved.

A 65-year-old woman is treated with gentamicin for an abdominal infection complicated by multidrug-resistant organisms. After a week of treatment, the patient's urine output decreases noticeably, and serum creatinine rises to 2.3 mg/dL. She has no previous kidney disease, and baseline kidney function was normal prior to the initiation of therapy. The patient has remained afebrile for 24 hours. Blood pressure is 130/80 mm Hg and pulse is 80/min. Examination shows moist mucous membranes. There is no rash. Results of urinalysis are as follows:

| | |
|---|---|
| Protein | +1 |
| White blood cells | 1-2/hpf |
| Red blood cells | none |
| Microscopy | granular casts |

Fractional excretion of sodium is >2%. Histologic examination of the patient's kidneys would most likely show which of the following?

A. Focal tubular epithelial necrosis

B. Leukocytic infiltration of the glomerular capillaries

C. Leukocytic infiltration of the interstitium and tubules

D. Preservation of normal renal architecture

E. Replacement of glomeruli with collagen

Submit

1 2 3 4 5 6 7 8 9 10 11 12 13 14 15 16 17 18 19 20 21 22 23 24 25 26 27 28 29 30

A 65-year-old woman is treated with gentamicin for an abdominal infection complicated by multidrug-resistant organisms. After a week of treatment, the patient's urine output decreases noticeably, and serum creatinine rises to 2.3 mg/dL. She has no previous kidney disease, and baseline kidney function was normal prior to the initiation of therapy. The patient has remained afebrile for 24 hours. Blood pressure is 130/80 mm Hg and pulse is 80/min. Examination shows moist mucous membranes. There is no rash. Results of urinalysis are as follows:

| | |
|---|---|
| Protein | +1 |
| White blood cells | 1-2/hpf |
| Red blood cells | none |
| Microscopy | granular casts |

Fractional excretion of sodium is >2%. Histologic examination of the patient's kidneys would most likely show which of the following?

- A. Focal tubular epithelial necrosis (70%)
- B. Leukocytic infiltration of the glomerular capillaries (2%)
- C. Leukocytic infiltration of the interstitium and tubules (22%)
- D. Preservation of normal renal architecture (3%)
- E. Replacement of glomeruli with collagen (0%)

Omitted
Correct answer
A

70%
Answered correctly

02 secs
Time Spent

01/29/2020
Last Updated

1 2 3 4 5 6 7 8 9 10 11 12 13 14 15 16 17 18 19 20 21 22 23 24 25 26 27 28 29 30

baseline kidney function was normal prior to the initiation of therapy. The patient has remained afebrile for 24 hours. Blood pressure is 130/80 mm Hg and pulse is 80/min. Examination shows moist mucous membranes. There is no rash. Results of urinalysis are as follows:

| | |
|---|---|
| Protein | +1 |
| White blood cells | 1-2/hpf |
| Red blood cells | none |
| Microscopy | granular casts |

Fractional excretion of sodium is >2%. Histologic examination of the patient's kidneys would most likely show which of the following?

- ✓ A. Focal tubular epithelial necrosis (70%)
- B. Leukocytic infiltration of the glomerular capillaries (2%)
- C. Leukocytic infiltration of the interstitium and tubules (22%)
- D. Preservation of normal renal architecture (3%)
- E. Replacement of glomeruli with collagen (0%)

Omitted
Correct answer
A

70%
Answered correctly

02 secs
Time Spent

01/29/2020
Last Updated

Explanation

Acute tubular necrosis due to nephrotoxins

| Acute tubular necrosis due to nephrotoxins | |
|---|---|
| **Common nephrotoxins** | • Antibiotics: aminoglycosides (eg, gentamicin), vancomycin<br>• Antivirals: cidofovir, foscarnet<br>• Other: intravenous radiocontrast dye, cisplatin, heme pigment |
| **Histology** | • Tubular epithelial necrosis with casts obstructing the tubular lumens and rupture of basement membrane<br>• Extensive involvement of the proximal tubules |
| **Presentation** | • BUN/creatinine ratio <20:1, FENa >2%,<br>• Muddy brown granular casts, low urine osmolality<br>• Oliguria or polyuria, ± electrolyte abnormalities |

**BUN** = blood urea nitrogen; **FENa** = fractional excretion of sodium.

**Aminoglycosides** (eg, gentamicin, tobramycin) are bactericidal antibiotics that bind to the 30S ribosomal subunit and inhibit protein synthesis. They are commonly used for severe gram-negative infections but carry a significant risk of acute kidney injury. Aminoglycosides are filtered across the glomerulus and concentrate within the proximal renal tubules, where they impair lysosomal function, protein synthesis, and mitochondrial activity, leading to **acute tubular necrosis** (ATN). This is visualized histologically as **focal tubular epithelial necrosis**, often with extensive granular casts that obstruct the tubular lumen and lead to rupture of the basement membrane.

Aminoglycoside-induced kidney injury typically manifests within 1 week of therapy initiation. Due to the high intratubular drug concentrations, ATN can occur despite normal serum drug levels. Proximal tubular dysfunction results in loss of resorptive capacity and **electrolyte wasting** (eg, hypomagnesemia, hypophosphatemia); severe disease can result in Fanconi syndrome (ie, aminoaciduria, glucosuria, uricosuria, phosphaturia). Distal tubular injury may also occur and results in loss of concentrating capacity with polyuria (nonoliguric renal failure). Urinalysis typically demonstrates mild proteinuria with granular or hyaline casts. Consistent with other causes of ATN, the **fractional excretion of sodium** (FENa) **is >2%**.

**(Choices B and E)** Leukocytic infiltration of the glomerular capillaries is seen with vasculitides (eg, granulomatosis with polyangiitis) that cause glomerulonephritis. Chronic glomerulonephritis is characterized by protracted inflammation with collagenous replacement of the glomeruli.

**Aminoglycosides** (eg, gentamicin, tobramycin) are bactericidal antibiotics that bind to the 30S ribosomal subunit and inhibit protein synthesis. They are commonly used for severe gram-negative infections but carry a significant risk of acute kidney injury. Aminoglycosides are filtered across the glomerulus and concentrate within the proximal renal tubules, where they impair lysosomal function, protein synthesis, and mitochondrial activity, leading to **acute tubular necrosis** (ATN). This is visualized histologically as **focal tubular epithelial necrosis**, often with extensive granular casts that obstruct the tubular lumen and lead to rupture of the basement membrane.

Aminoglycoside-induced kidney injury typically manifests within 1 week of therapy initiation. Due to the high intratubular drug concentrations, ATN can occur despite normal serum drug levels. Proximal tubular dysfunction results in loss of resorptive capacity and **electrolyte wasting** (eg, hypomagnesemia, hypophosphatemia); severe disease can result in Fanconi syndrome (ie, aminoaciduria, glucosuria, uricosuria, phosphaturia). Distal tubular injury may also occur and results in loss of concentrating capacity with polyuria (nonoliguric renal failure). Urinalysis typically demonstrates mild proteinuria with granular or hyaline casts. Consistent with other causes of ATN, the **fractional excretion of sodium** (FENa) **is >2%**.

**(Choices B and E)** Leukocytic infiltration of the glomerular capillaries is seen with vasculitides (eg, granulomatosis with polyangiitis) that cause glomerulonephritis. Chronic glomerulonephritis is characterized by protracted inflammation with collagenous replacement of the glomeruli. However, nephritic diseases typically cause hypertension, hematuria, and red blood cell casts on urinalysis.

**(Choice C)** Leukocytic infiltration of the interstitium and tubules is seen in acute interstitial nephritis, a common cause of kidney injury that often occurs after introduction of a new drug. However, patients typically have fever and rash, and urinalysis shows pyuria and white blood cell casts.

**(Choice D)** Patients with prerenal causes of kidney injury (eg, dehydration, blood loss) have normal renal architecture. However, the FENa in prerenal disease is <1%, and the patient would be expected to have signs of hypovolemia (eg, dry mucous membranes).

**Educational objective:**
Aminoglycosides are filtered across the glomerulus and concentrate in the renal tubules, leading to proximal tubular injury and acute tubular necrosis. This is visualized histologically as focal tubular epithelial necrosis, often with extensive granular casts that obstruct the tubular lumen and lead to rupture of the basement membrane.

---

Pathology Renal, Urinary Systems & Electrolytes Aminoglycoside

## Exhibit Display

### Types of acute tubular necrosis (ATN)

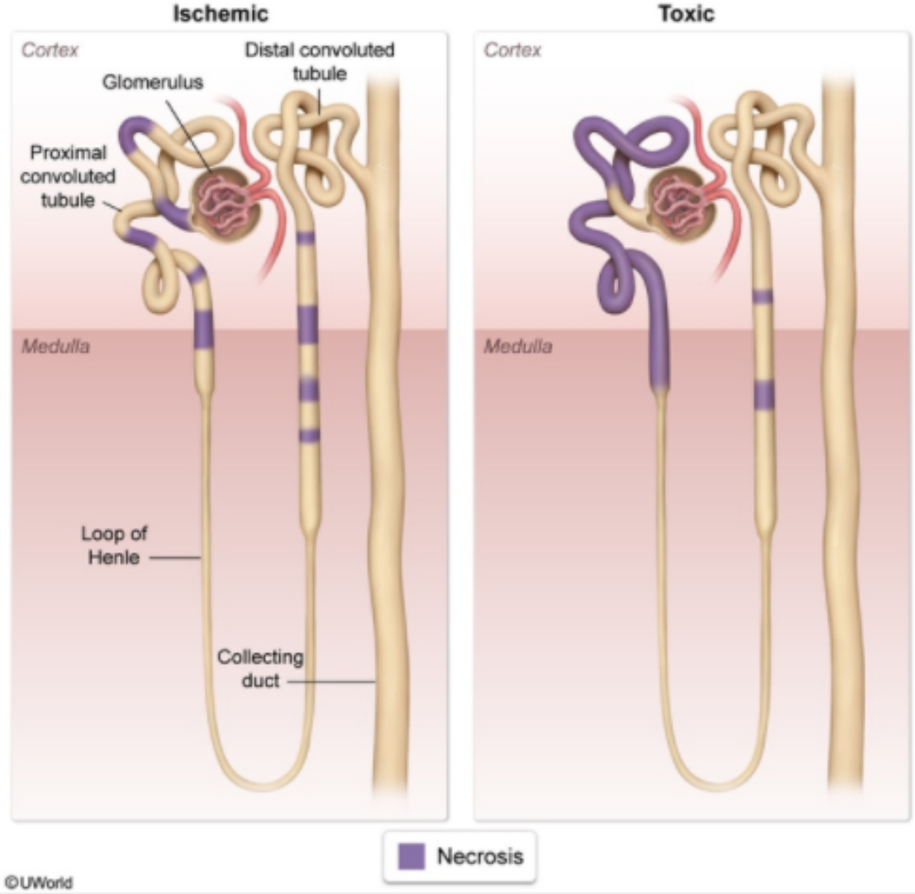


Zoom In | Zoom Out | Reset | Add To New Card | Existing Card

Pathology | Renal, Urinary Systems & Electrolytes | Aminoglycoside

mitochondrial activity, leading to **acute tubular necrosis** (ATN). This is visualized histologically as **focal tubular epithelial necrosis**, often with extensive granular casts that obstruct the tubular lumen and lead to rupture of the basement membrane.

Aminoglycoside-induced kidney injury typically manifests within 1 week of therapy initiation. Due to the high intratubular drug concentrations, ATN can occur despite normal serum drug levels. Proximal tubular dysfunction results in loss of resorptive capacity and **electrolyte wasting** (eg, hypomagnesemia, hypophosphatemia); severe disease can result in Fanconi syndrome (ie, aminoaciduria, glucosuria, uricosuria, phosphaturia). Distal tubular injury may also occur and results in loss of concentrating capacity with polyuria (nonoliguric renal failure). Urinalysis typically demonstrates mild proteinuria with granular or hyaline casts. Consistent with other causes of ATN, the **fractional excretion of sodium** (FENa) **is >2%**.

**(Choices B and E)** Leukocytic infiltration of the glomerular capillaries is seen with vasculitides (eg, granulomatosis with polyangiitis) that cause glomerulonephritis. Chronic glomerulonephritis is characterized by protracted inflammation with collagenous replacement of the glomeruli. However, nephritic diseases typically cause hypertension, hematuria, and red blood cell casts on urinalysis.

**(Choice C)** Leukocytic infiltration of the interstitium and tubules is seen in acute interstitial nephritis, a common cause of kidney injury that often occurs after introduction of a new drug. However, patients typically have fever and rash, and urinalysis shows pyuria and white blood cell casts.

**(Choice D)** Patients with prerenal causes of kidney injury (eg, dehydration, blood loss) have normal renal architecture. However, the FENa in prerenal disease is <1%, and the patient would be expected to have signs of hypovolemia (eg, dry mucous membranes).

**Educational objective:**
Aminoglycosides are filtered across the glomerulus and concentrate in the renal tubules, leading to proximal tubular injury and acute tubular necrosis. This is visualized histologically as focal tubular epithelial necrosis, often with extensive granular casts that obstruct the tubular lumen and lead to rupture of the basement membrane.

| Pathology | Renal, Urinary Systems & Electrolytes | Aminoglycoside |
|---|---|---|
| Subject | System | Topic |

Copyright © UWorld. All rights reserved.

1
2
3
4
5
6
7
8
9
10
11
12
13
14
15
16
17
18
19
20
21
22
23
24
25
26
27
28
29
30

A 50-year-old man comes to the office for evaluation of abdominal fullness and mild right flank pain. He also reports a weight loss of 4.5 kg (10 lb) over the past 2 months. The patient has no other medical issues and works in a local industrial chemical manufacturing facility. Examination shows a soft abdomen. Ultrasound reveals a mass in the right kidney. A subsequent abdominal CT scan confirms the presence of a large right renal mass with evidence of necrosis. The patient undergoes a right total nephrectomy. The specimen is shown below.

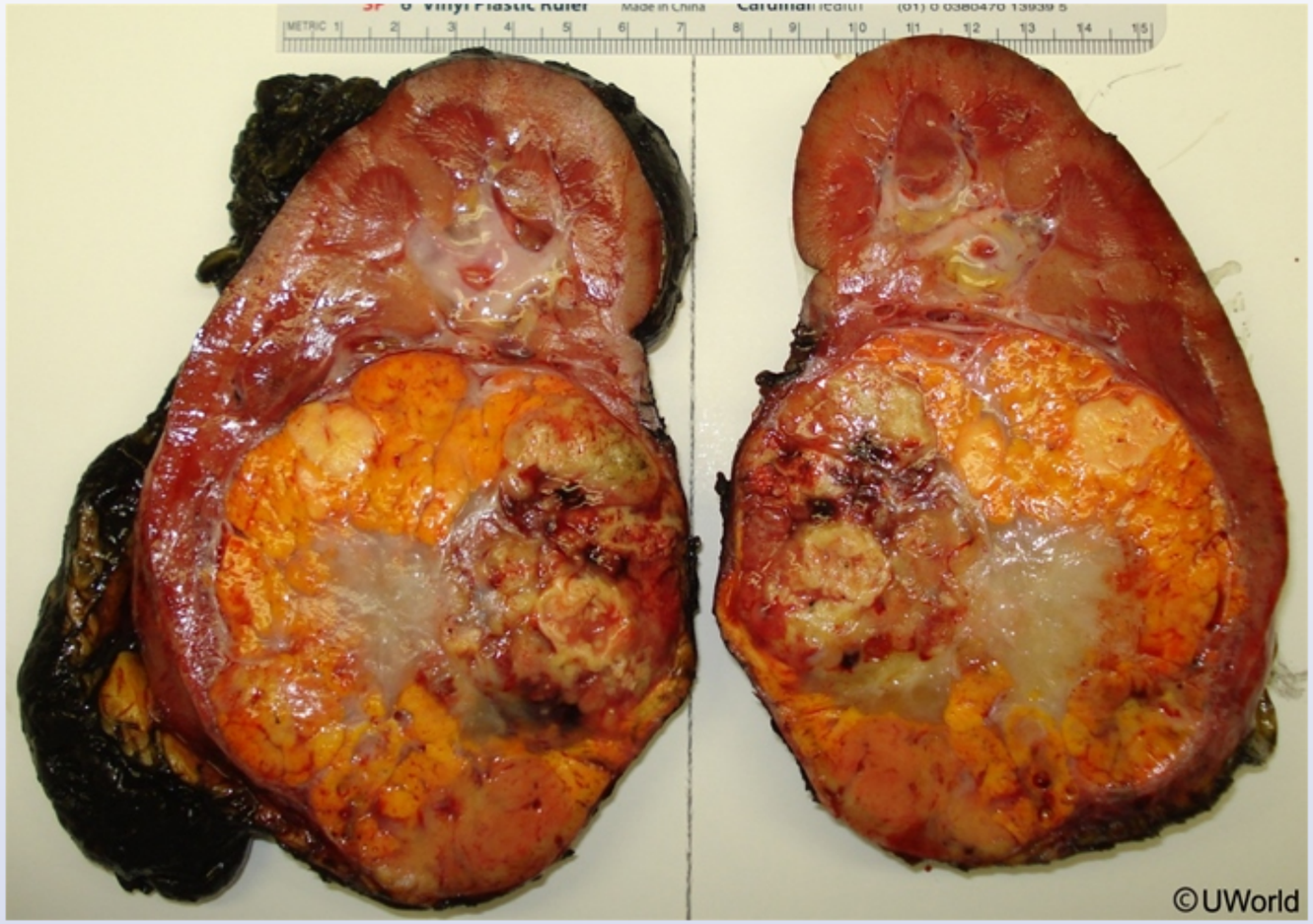

Settings

1 2 3 4 5 6 7 8 9 10 11 12 13 14 15 16 17 18 19 20 21 22 23 24 25 26 27 28 29 30

Item 19 of 39
Question Id: 905

Mark | Previous | Next | Full Screen | Tutorial | Lab Values | Notes | Calculator | Reverse Color | Text Zoom | Settings

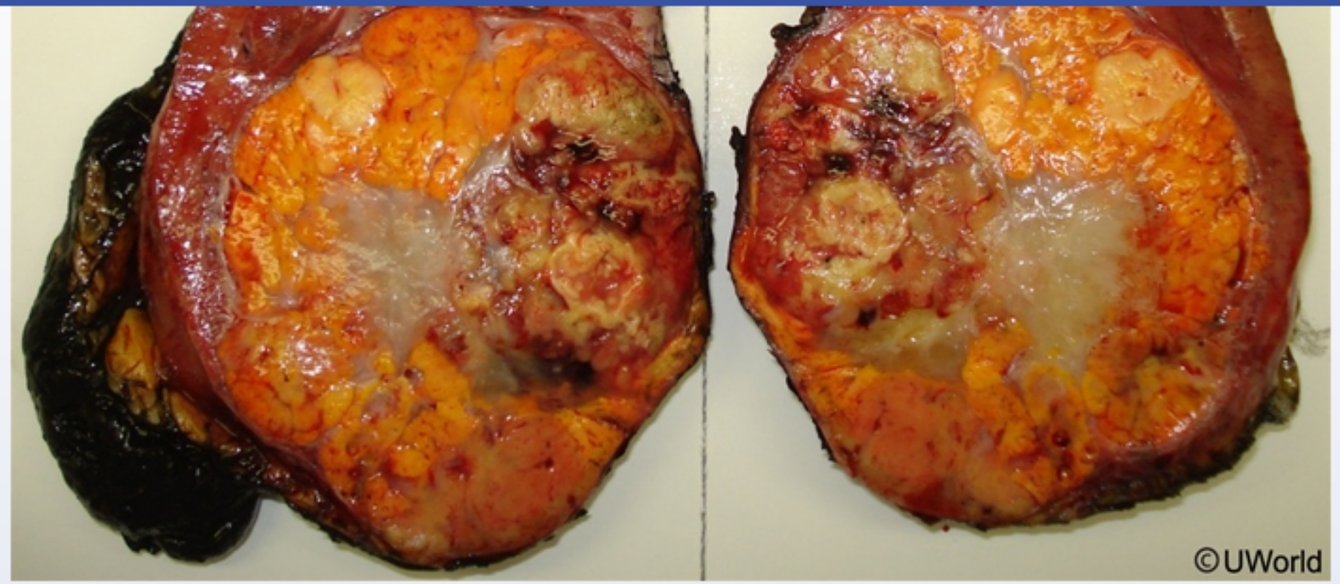


This patient's lesion most likely originated from which of the following portions of the kidney?

- A. Blood vessels
- B. Collecting duct cells
- C. Glomeruli
- D. Proximal renal tubules
- E. Renal pelvis lining

Submit

Block Time Remaining: 00:05:08
TUTOR

5 | Feedback | Suspend | End Block

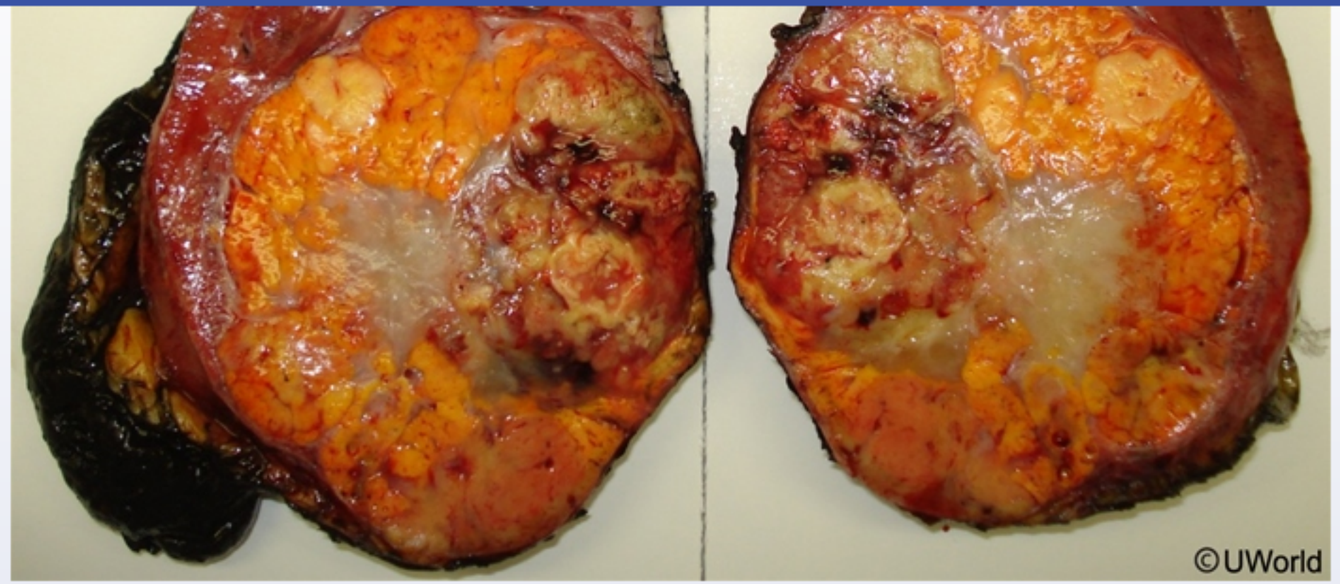


This patient's lesion most likely originated from which of the following portions of the kidney?

- A. Blood vessels (7%)
- B. Collecting duct cells (14%)
- C. Glomeruli (6%)
- ✓ D. Proximal renal tubules (45%)
- E. Renal pelvis lining (25%)

Omitted
Correct answer

45%
Answered correctly

03 secs
Time Spent

07/02/2020
Last Updated

| Renal cell carcinoma | |
|---|---|
| **Presentation** | • Hematuria, flank pain, palpable abdominal mass<br>• Paraneoplastic syndrome (eg, polycythemia, hypercalcemia) |
| **Risk factors** | • Smoking, hypertension, obesity<br>• Toxin exposure (eg, heavy metal, petroleum by-products) |
| **Gross examination** | • Spherical mass, often with invasion of the renal vein<br>• Golden-yellow tissue (due to high lipid content) |
| **Histology**<br>(Clear cell) | • Cuboidal or polygonal cells with abundant, clear cytoplasm<br>• Branching, "chicken-wire" vasculature |

This patient with a history of chemical exposure and a necrotic kidney mass likely has renal cell carcinoma (RCC), the most common renal malignancy. RCC originates in the renal cortex and occurs most commonly in patients age 60-70. Risk factors include **smoking**, obesity, hypertension and **toxin exposure** (eg, heavy metal, petroleum by-products, asbestos).

RCC is classified into subtypes based on cellular origin; **clear cell carcinoma** (CCC) is the most common type and accounts for up to 85% of RCCs. CCC originates from the epithelium of the **proximal renal tubules**. Gross pathology typically demonstrates a **sphere-like** mass composed of **golden-yellow tissue** (due to high lipid content) with areas of focal **necrosis** and **hemorrhage**. It often invades the renal vein and may extend into the inferior vena cava. On microscopy, CCC appears as cuboidal or polygonal cells with abundant clear cytoplasm and eccentric nuclei.

**(Choice A)** Angiomyolipomas are rare tumors that arise from blood vessel epithelial cells. Gross pathology demonstrates a well-circumscribed tumor composed of 3 different cell types: Yellow adipose tissue, red vascular components, and grayish smooth muscle. Angiomyolipomas are benign neoplasms often associated with tuberous sclerosis.

**(Choice B)** Renal oncocytomas are rare tumors that originate from collecting duct cells. Gross pathology often demonstrates a homogenous brown tumor with a central stellate scar that is often visible on imaging; focal areas of necrosis are rare.

hypertension and **toxin exposure** (eg, heavy metal, petroleum by-products, asbestos).

RCC is classified into subtypes based on cellular origin; **clear cell carcinoma** (CCC) is the most common type and accounts for up to 85% of RCCs. CCC originates from the epithelium of the **proximal renal tubules**. Gross pathology typically demonstrates a **sphere-like** mass composed of **golden-yellow tissue** (due to high lipid content) with areas of focal **necrosis** and **hemorrhage**. It often invades the renal vein and may extend into the inferior vena cava. On microscopy, CCC appears as cuboidal or polygonal cells with abundant clear cytoplasm and eccentric nuclei.

**(Choice A)** Angiomyolipomas are rare tumors that arise from blood vessel epithelial cells. Gross pathology demonstrates a well-circumscribed tumor composed of 3 different cell types: Yellow adipose tissue, red vascular components, and grayish smooth muscle. Angiomyolipomas are benign neoplasms often associated with tuberous sclerosis.

**(Choice B)** Renal oncocytomas are rare tumors that originate from collecting duct cells. Gross pathology often demonstrates a homogenous brown tumor with a central stellate scar that is often visible on imaging; focal areas of necrosis are rare.

**(Choice C)** Glomerular diseases (eg, membranous nephropathy, minimal change disease) can be seen as a paraneoplastic syndrome associated with certain malignancies (eg, lung, gastrointestinal tumors), but the glomeruli are not the site of origin of RCC.

**(Choice E)** Urothelial carcinoma arises from the epithelium of the renal pelvis, ureters, or bladder and may be multifocal in nature. It often forms papillary tumors composed of urothelium supported by a thin fibrovascular stalk.

**Educational objective:**
Clear cell carcinoma is the most common type of renal cell carcinoma and originates from the epithelial cells of the proximal renal tubules. Gross pathology typically demonstrates a sphere-like mass composed of golden-yellow cells (due to high lipid content) with areas of necrotic cells and focal hemorrhage.

| Pathology | Renal, Urinary Systems & Electrolytes | Renal cell carcinoma |
|---|---|---|
| Subject | System | Topic |

Copyright © UWorld. All rights reserved.

1
2
3
4
5
6
7
8
9
10
11
12
13
14
15
16
17
18
19
20
21
22
23
24
25
26
27
28
29
30

hypertension and **toxin exposure** (eg, heavy metal, petroleum by-products, asbestos).

**Exhibit Display**

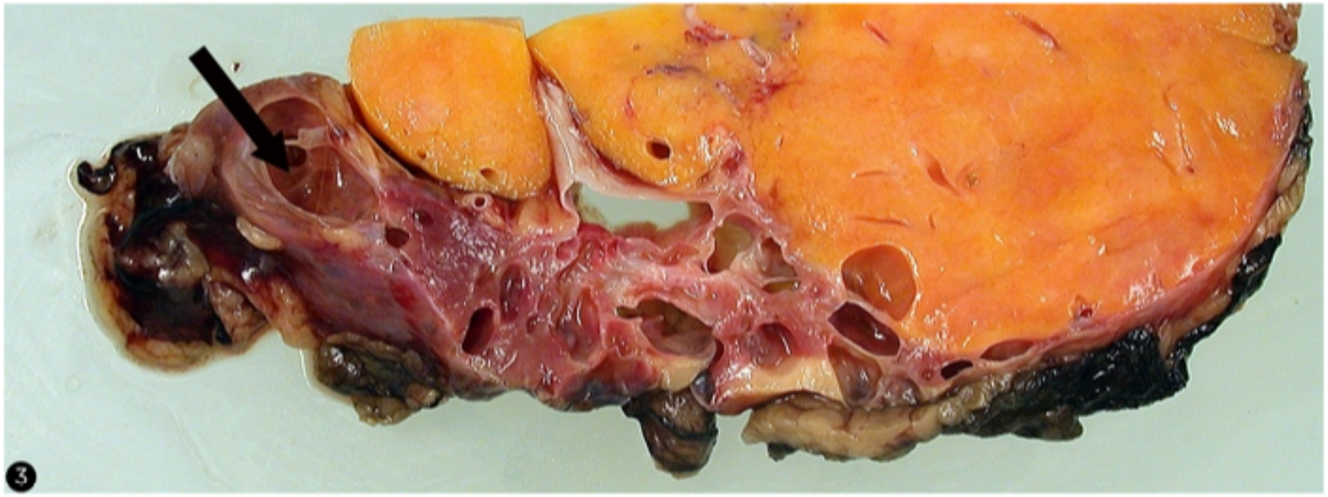

Zoom In | Zoom Out | Reset | Add To New Card | Existing Card

hypertension and **toxin exposure** (eg, heavy metal, petroleum by-products, asbestos).

**Exhibit Display**

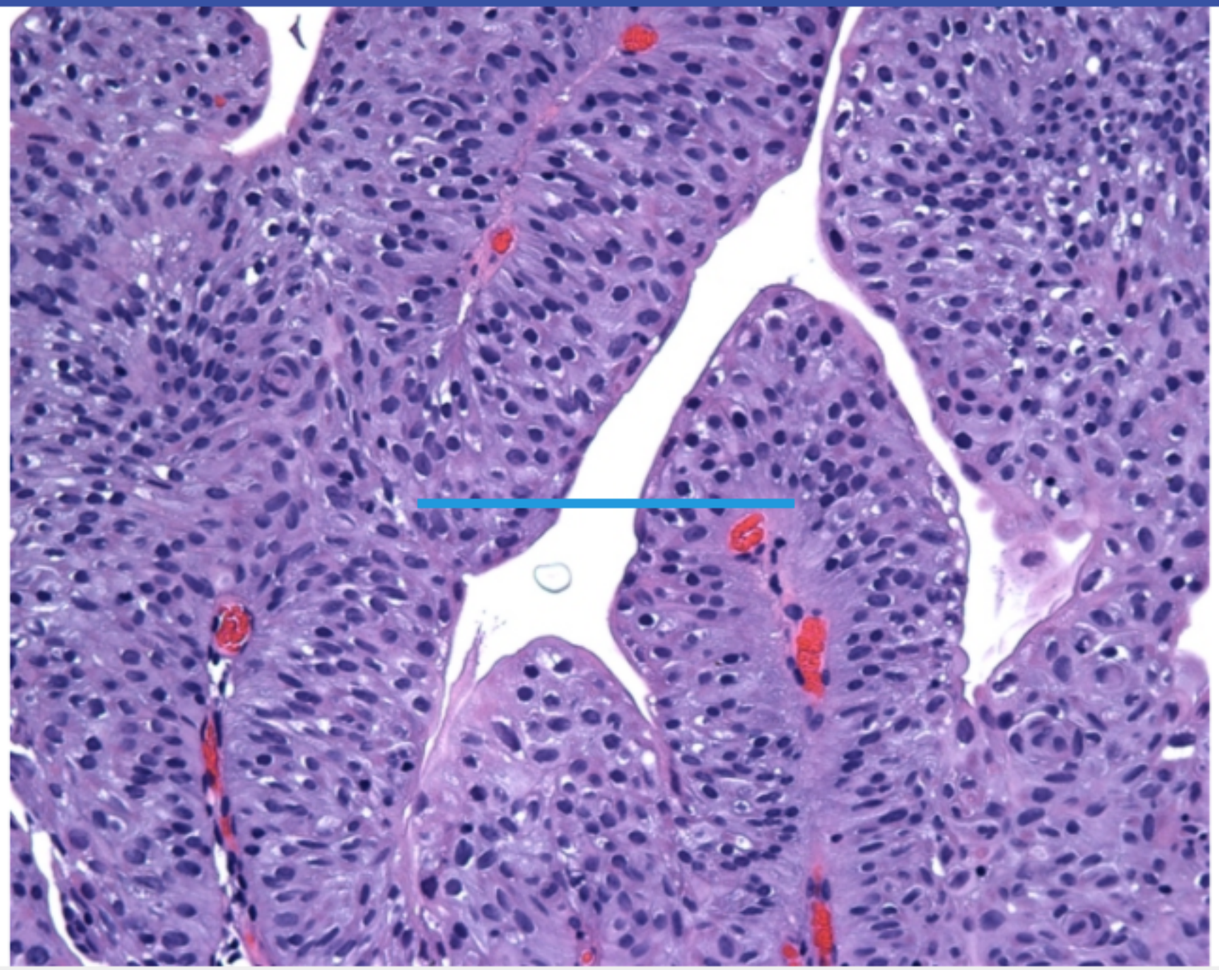

Zoom In | Zoom Out | Reset | Add To New Card | Existing Card

A 24-year-old woman comes to the office for the evaluation of joint pain, fatigue, edema, and weight gain for the past four weeks. She has no previous medical conditions except for recurrent oral ulcers. The patient takes no medications and does not use tobacco, alcohol, or illicit drugs. Blood pressure is 130/80 mm Hg and pulse is 80/min. Examination shows oral mucosal ulcers, facial puffiness, and 3+ peripheral edema. Swelling, erythema, and tenderness are noted over the bilateral metacarpophalangeal and proximal interphalangeal joints. Cardiopulmonary examination reveals no abnormalities. Twenty-four-hour urine protein excretion is 4.5 g. Serum antinuclear antibodies are present. Kidney biopsy shows glomerular capillary wall thickening with no increase in cellularity. When the sample is stained with methenamine silver, irregular spikes protruding from the glomerular basement membrane are seen. This patient most likely has which of the following conditions?

- A. Antiglomerular basement membrane disease
- B. Antineutrophil cytoplasmic antibody–associated glomerulonephritis
- C. Diffuse proliferative nephritis
- D. Focal segmental glomerulosclerosis
- E. Membranoproliferative glomerulonephritis
- F. Membranous glomerulopathy
- G. Postinfectious glomerulonephritis

Submit

1 2 3 4 5 6 7 8 9 10 11 12 13 14 15 16 17 18 19 20 21 22 23 24 25 26 27 28 29 30

A 24-year-old woman comes to the office for the evaluation of joint pain, fatigue, edema, and weight gain for the past four weeks. She has no previous medical conditions except for recurrent oral ulcers. The patient takes no medications and does not use tobacco, alcohol, or illicit drugs. Blood pressure is 130/80 mm Hg and pulse is 80/min. Examination shows oral mucosal ulcers, facial puffiness, and 3+ peripheral edema. Swelling, erythema, and tenderness are noted over the bilateral metacarpophalangeal and proximal interphalangeal joints. Cardiopulmonary examination reveals no abnormalities. Twenty-four-hour urine protein excretion is 4.5 g. Serum antinuclear antibodies are present. Kidney biopsy shows glomerular capillary wall thickening with no increase in cellularity. When the sample is stained with methenamine silver, irregular spikes protruding from the glomerular basement membrane are seen. This patient most likely has which of the following conditions?

A. Antiglomerular basement membrane disease (2%)

B. Antineutrophil cytoplasmic antibody–associated glomerulonephritis (8%)

C. Diffuse proliferative nephritis (9%)

D. Focal segmental glomerulosclerosis (4%)

E. Membranoproliferative glomerulonephritis (14%)

✓ F. Membranous glomerulopathy (58%)

G. Postinfectious glomerulonephritis (1%)

Omitted
Correct answer
F

58%
Answered correctly

02 secs
Time Spent

03/28/2020
Last Updated

Explanation

This patient has **nephrotic syndrome** (ie, generalized edema, marked proteinuria). In conjunction with the characteristic biopsy findings, this presentation suggests **membranous glomerulopathy** (MG). MG is caused by immune-complex deposition in the subepithelial portion of the glomerular capillary wall. Light microscopy shows **diffuse thickening** of the glomerular basement membrane (GBM) without an increase in glomerular cellularity. Immunofluorescence reveals granular deposits of IgG and C3 along the GBM. Electron microscopy demonstrates irregular, electron-dense immune deposits located between the GBM and epithelial cells. Protrusion of the GBM through the deposits resemble **spikes and domes** when stained with a silver stain.

MG is a common cause of nephrotic syndrome in adults. Most cases are idiopathic, with the remainder due to chronic infection (eg, viral hepatitis, syphilis), solid tumors (eg, lung, colon), or **systemic lupus erythematous** (SLE). This patient with inflammatory arthritis, oral ulcers, and antinuclear antibodies likely has MG secondary to SLE (which leads to renal disease from anti–double-stranded DNA immune-complex formation).

**(Choices A and B)** Anti-GBM disease (ie, Goodpasture disease) and antineutrophil cytoplasmic antibody–associated glomerulonephritis (eg, granulomatosis with polyangiitis) cause rapidly progressive crescentic disease, characterized by glomerular hypercellularity with crescent formation (composed of fibrin and proliferating cells). These diseases cause nephritic syndrome (eg, hematuria, red blood cell casts), not isolated proteinuria.

**(Choice C)** Diffuse proliferative nephritis, another common renal manifestation of SLE, is characterized by proliferation of lymphocytes and endothelial cells within the capillary loops. Diffuse "wire-loop" deposits are often seen.

**(Choice D)** Focal segmental glomerulosclerosis also causes nephrotic syndrome but is characterized by sclerosis in some (but not all) glomeruli (focal) and some portions of the glomerulus. It is commonly associated with drug use (eg, heroin) and viruses (eg, HIV).

**(Choice E)** Membranoproliferative glomerulonephritis is often associated with hepatitis B or C. It is characterized by thickening of the GBM, but, unlike MG, large hypercellular glomeruli are also seen.

**(Choice G)** Postinfectious glomerulonephritis occurs more commonly in children and causes a nephritic (not nephrotic) syndrome, typically two to four weeks after a group A streptococcal infection. Light microscopy demonstrates enlarged, diffusely hypercellular glomeruli.

**Educational objective:**

Membranous glomerulopathy is a common cause of nephrotic syndrome in adults and can occur in association with solid malignancy, viral

Settings

1
2
3
4
5
6
7
8
9
10
11
12
13
14
15
16
17
18
19
20
21
22
23
24
25
26
27
28
29
30

Item 20 of 39
Question Id: 382

Mark | Previous | Next | Full Screen | Tutorial | Lab Values | Notes | Calculator | Reverse Color | Text Zoom | Settings

Exhibit Display

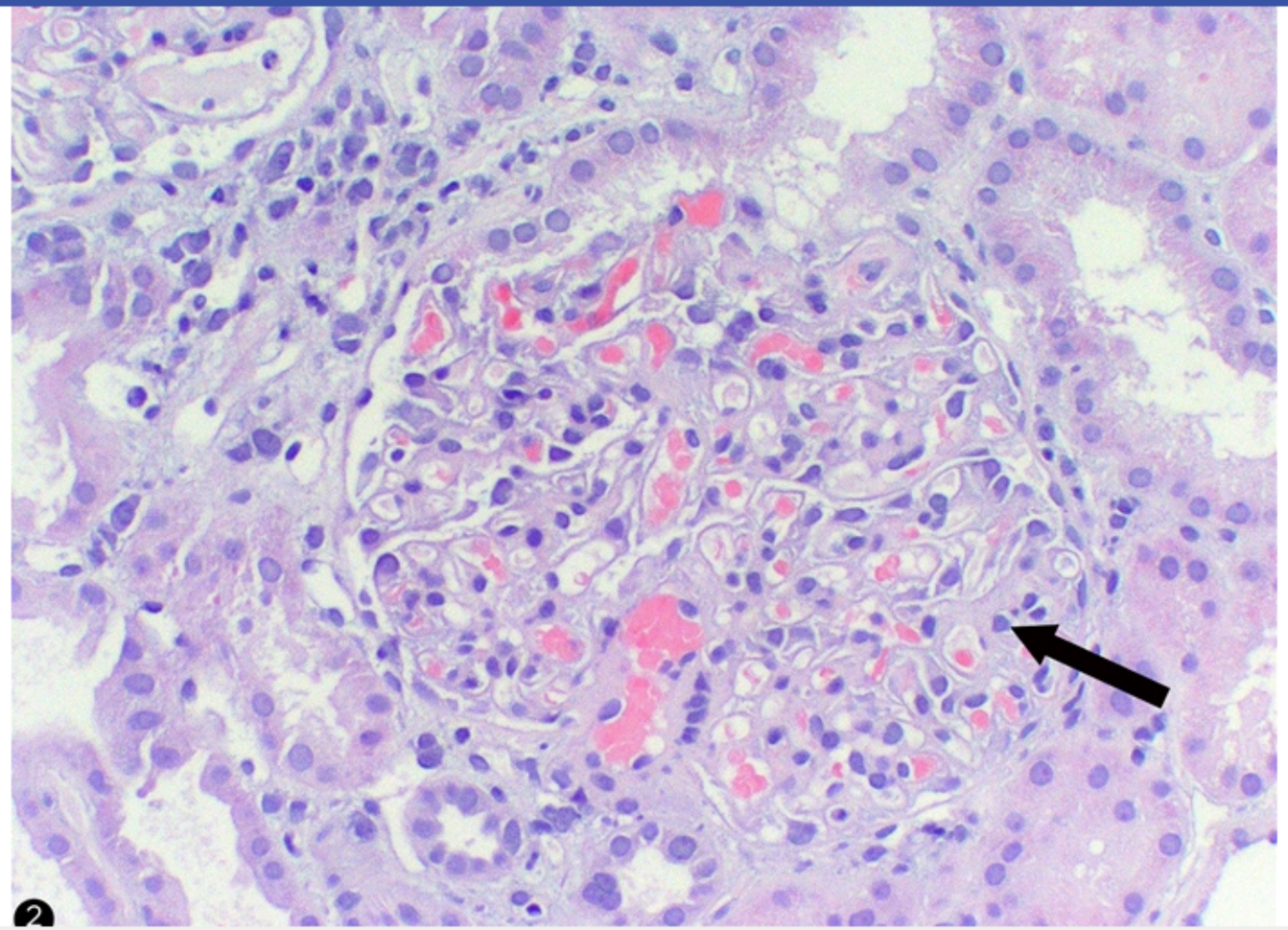

Zoom In | Zoom Out | Reset | Add To New Card | Existing Card

Membranous glomerulopathy is a common cause of nephrotic syndrome in adults and can occur in association with solid malignancy, viral

Block Time Remaining: 00:05:11
TUTOR

7 | Feedback | Suspend | End Block

Settings

1
2
3
4
5
6
7
8
9
10
11
12
13
14
15
16
17
18
19
20
21
22
23
24
25
26
27
28
29
30

Item 20 of 39
Question Id: 382

Mark | Previous | Next | Full Screen | Tutorial | Lab Values | Notes | Calculator | Reverse Color | Text Zoom | Settings

Exhibit Display

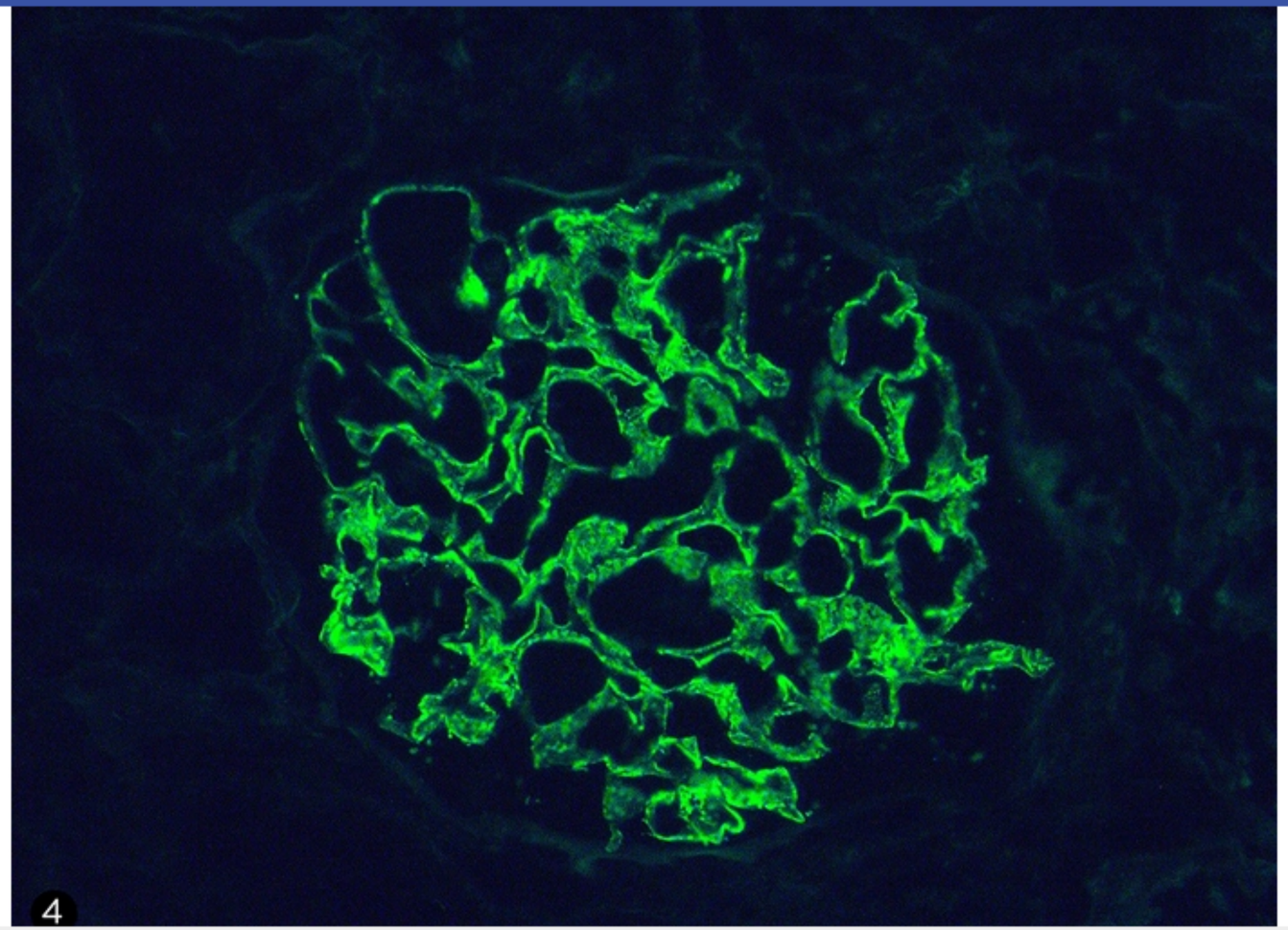


Zoom In | Zoom Out | Reset | Add To New Card | Existing Card

Membranous glomerulopathy is a common cause of nephrotic syndrome in adults and can occur in association with solid malignancy, viral

Block Time Remaining: 00:05:11
TUTOR

7 | Feedback | Suspend | End Block

Settings

1
2
3
4
5
6
7
8
9
10
11
12
13
14
15
16
17
18
19
20
21
22
23
24
25
26
27
28
29
30

Item 20 of 39
Question Id: 382

Mark | Previous | Next | Full Screen | Tutorial | Lab Values | Notes | Calculator | Reverse Color | Text Zoom | Settings

Exhibit Display

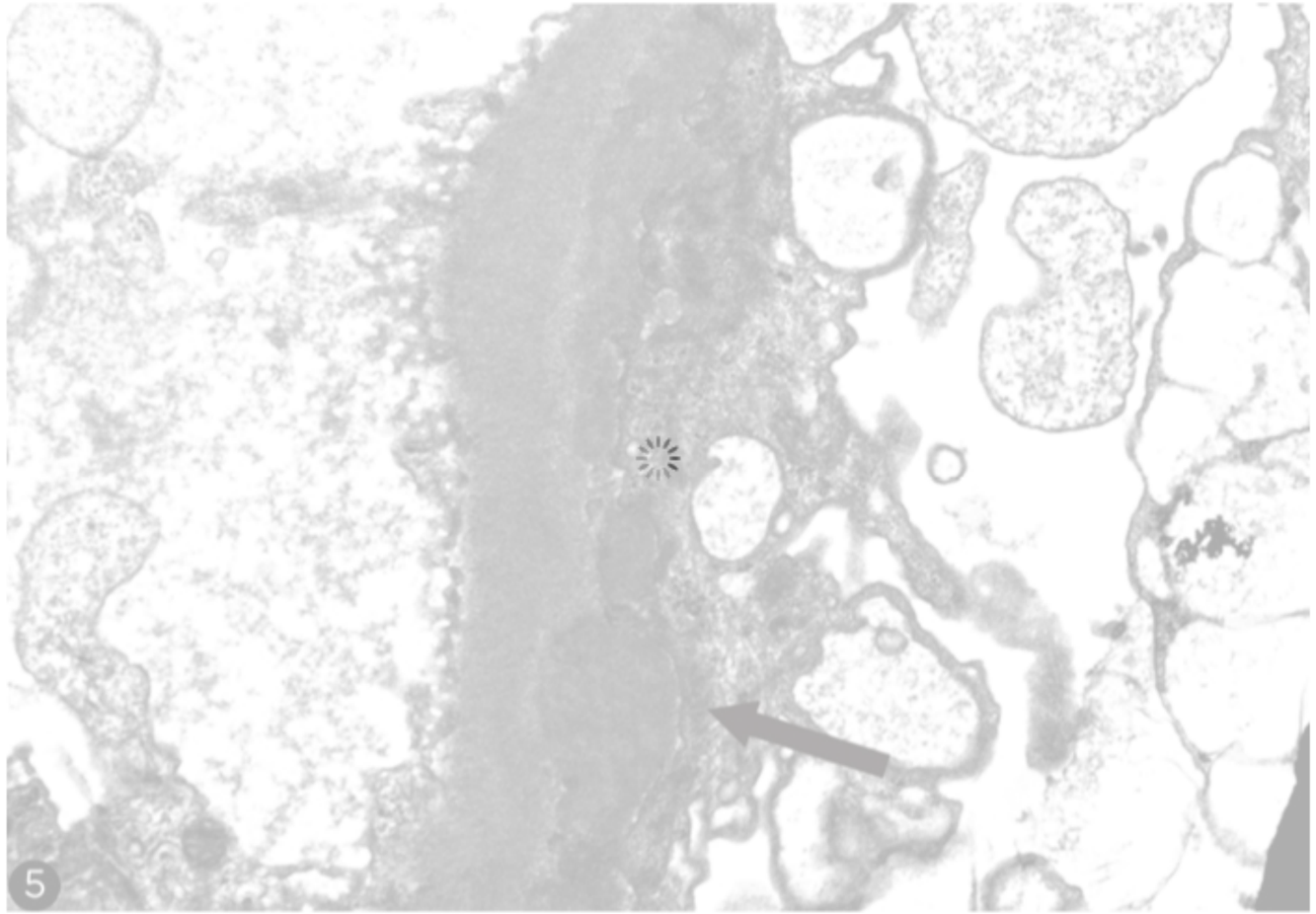


Zoom In | Zoom Out | Reset | Add To New Card | Existing Card

Membranous glomerulopathy is a common cause of nephrotic syndrome in adults and can occur in association with solid malignancy, viral

Block Time Remaining: 00:05:11
TUTOR

7 | Feedback | Suspend | End Block

Settings

1 2 3 4 5 6 7 8 9 10 11 12 13 14 15 16 17 18 19 20 21 22 23 24 25 26 27 28 29 30

Item 20 of 39
Question Id: 382

Mark | Previous | Next | Full Screen | Tutorial | Lab Values | Notes | Calculator | Reverse Color | Text Zoom | Settings

Exhibit Display

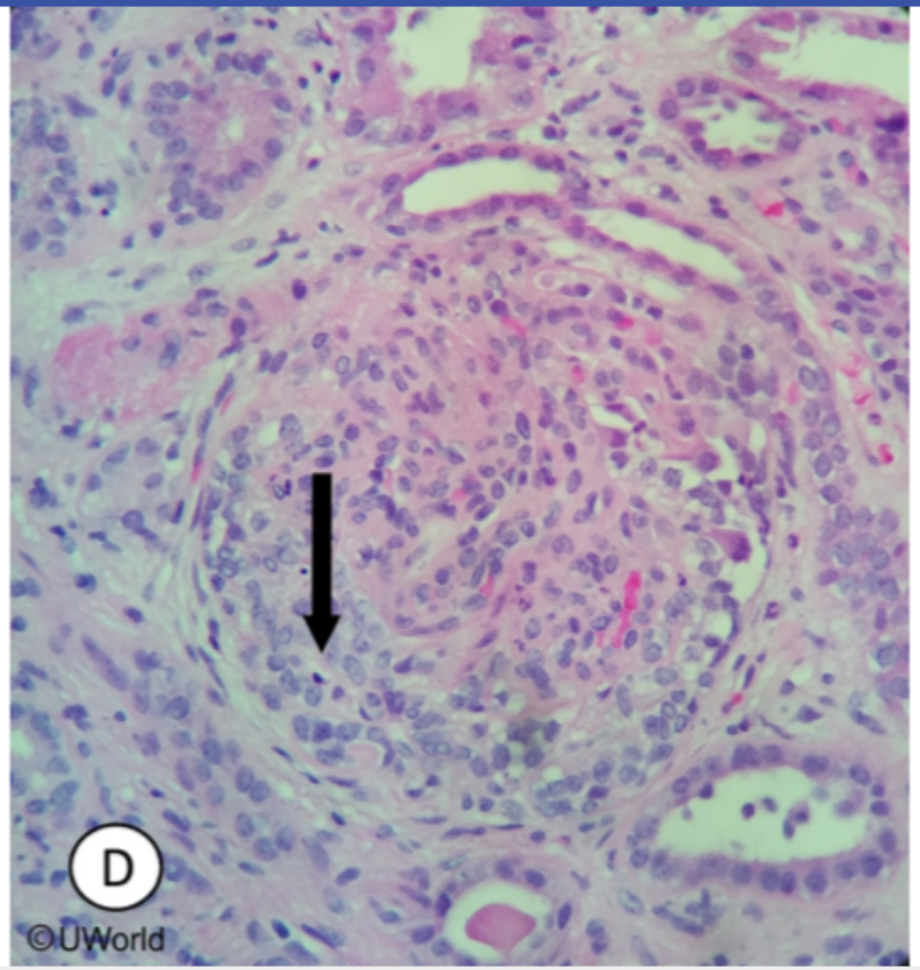


Zoom In | Zoom Out | Reset | Add To New Card | Existing Card

Membranous glomerulopathy is a common cause of nephrotic syndrome in adults and can occur in association with solid malignancy, viral

Block Time Remaining: 00:05:11
TUTOR

7 | Feedback | Suspend | End Block

Settings

1
2
3
4
5
6
7
8
9
10
11
12
13
14
15
16
17
18
19
20
21
22
23
24
25
26
27
28
29
30

Item 20 of 39
Question Id: 382

Mark | Previous | Next | Full Screen | Tutorial | Lab Values | Notes | Calculator | Reverse Color | Text Zoom | Settings

Exhibit Display

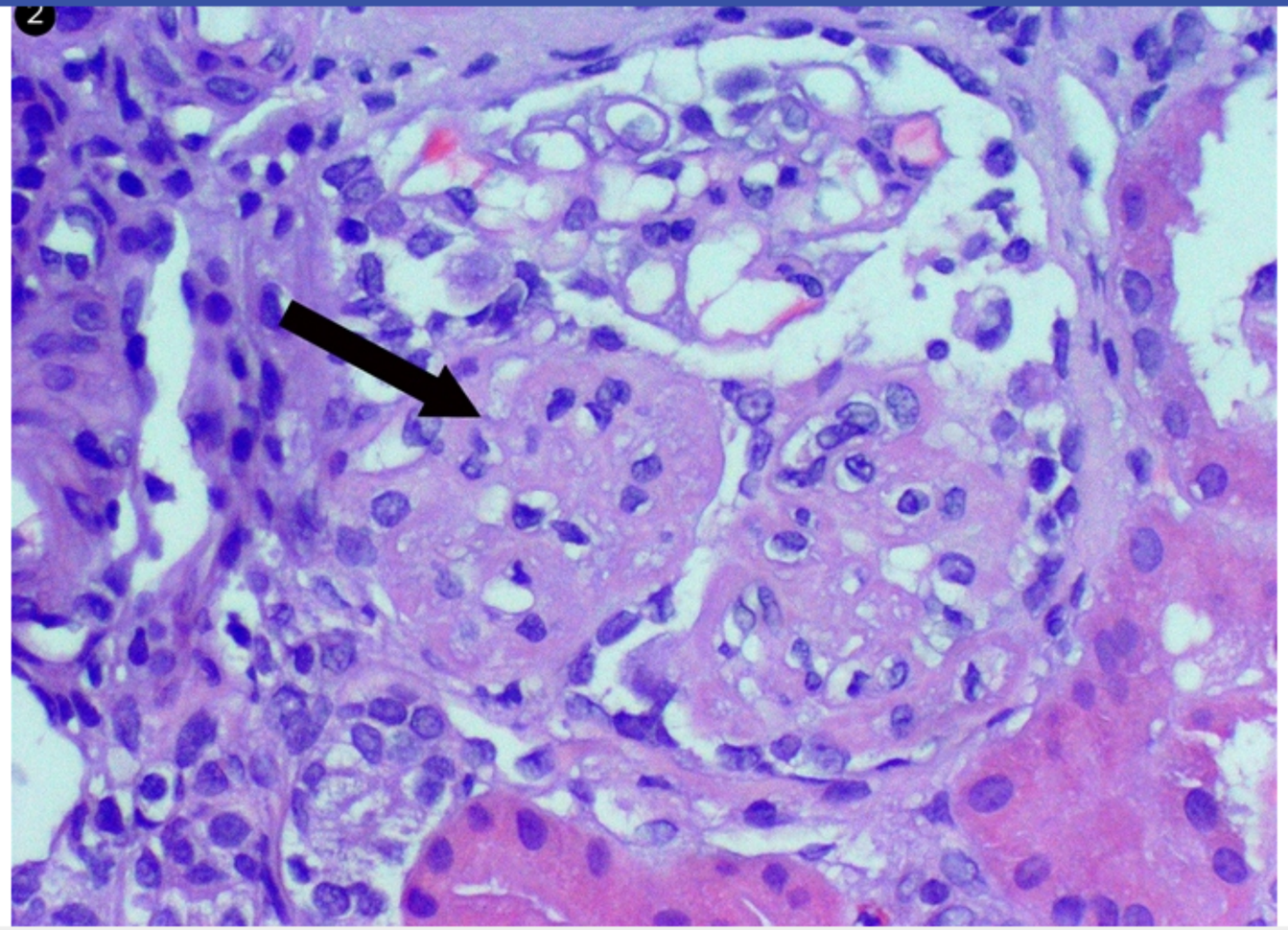

Zoom In | Zoom Out | Reset | Add To New Card | Existing Card

Membranous glomerulopathy is a common cause of nephrotic syndrome in adults and can occur in association with solid malignancy, viral

Block Time Remaining: 00:05:11
TUTOR

7 | Feedback | Suspend | End Block

Settings

1
2
3
4
5
6
7
8
9
10
11
12
13
14
15
16
17
18
19
20
21
22
23
24
25
26
27
28
29
30

Item 20 of 39
Question Id: 382

Mark | Previous | Next | Full Screen | Tutorial | Lab Values | Notes | Calculator | Reverse Color | Text Zoom | Settings

Exhibit Display

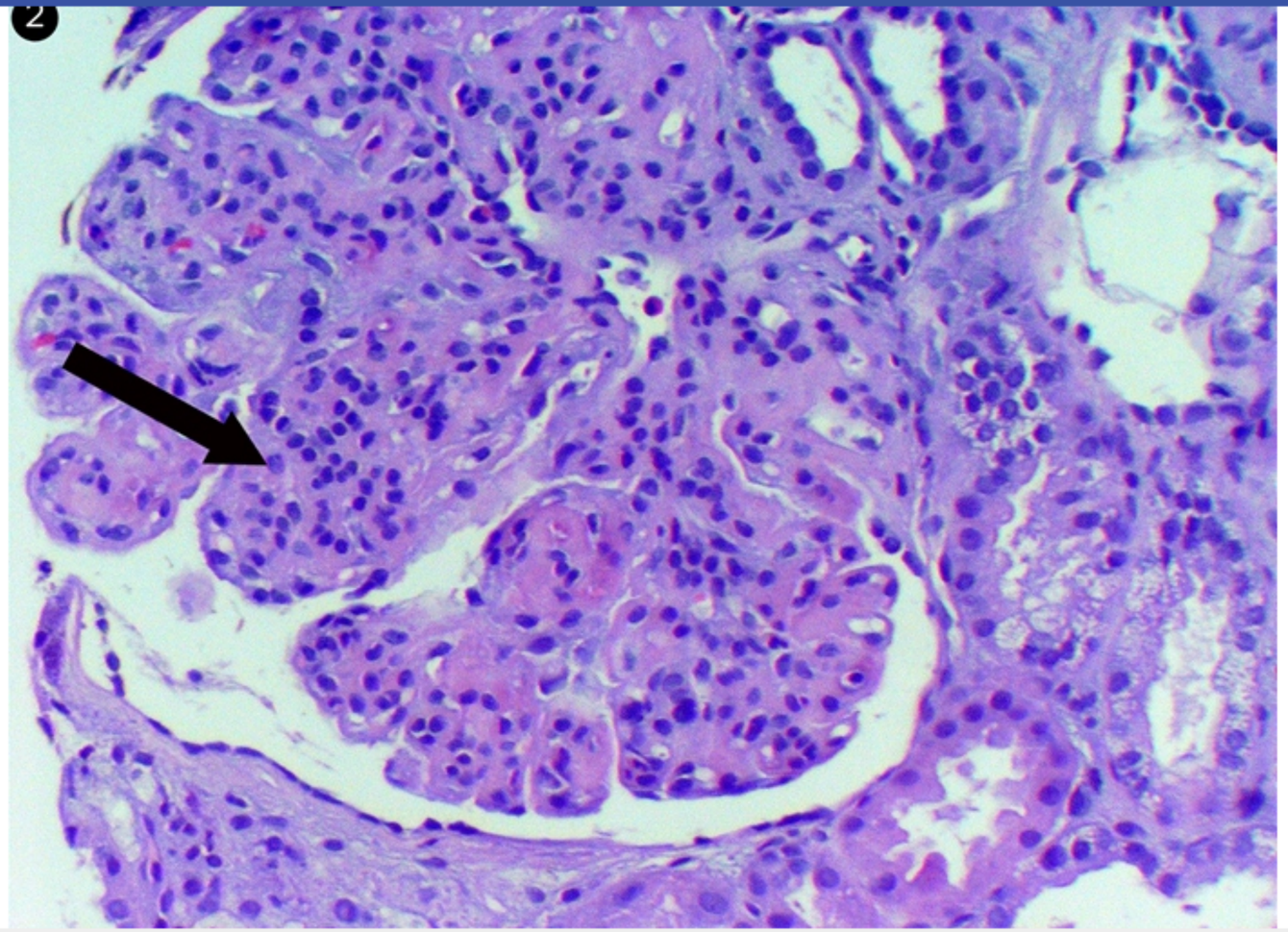


Zoom In | Zoom Out | Reset | Add To New Card | Existing Card

Membranous glomerulopathy is a common cause of nephrotic syndrome in adults and can occur in association with solid malignancy, viral

Block Time Remaining: 00:05:11
TUTOR

7 | Feedback | Suspend | End Block

Settings

1 2 3 4 5 6 7 8 9 10 11 12 13 14 15 16 17 18 19 20 21 22 23 24 25 26 27 28 29 30

Item 20 of 39
Question Id: 382

Mark | Previous | Next | Full Screen | Tutorial | Lab Values | Notes | Calculator | Reverse Color | Text Zoom | Settings

syphilis), solid tumors (eg, lung, colon), or **systemic lupus erythematous** (SLE). This patient with inflammatory arthritis, oral ulcers, and

Exhibit Display

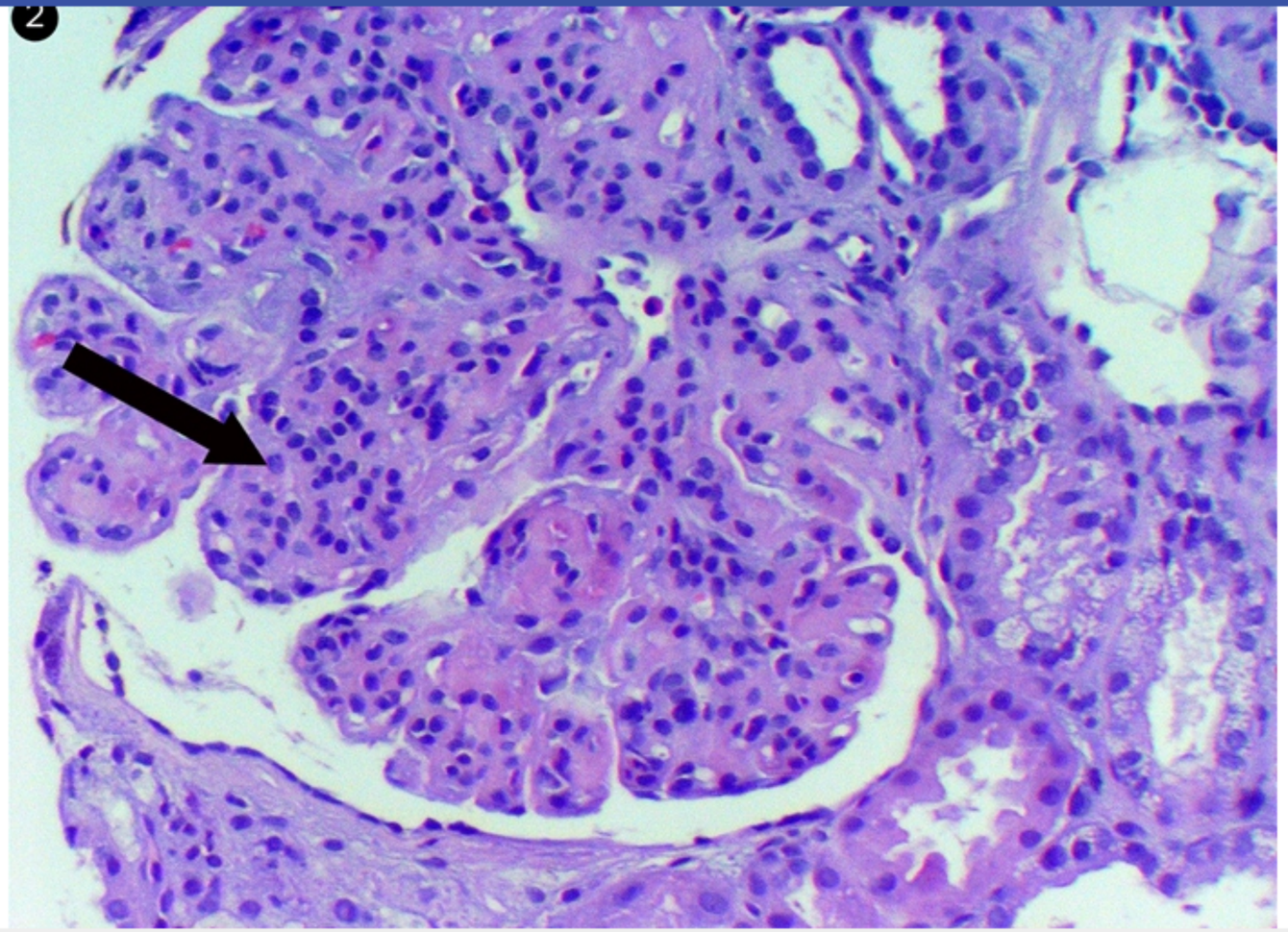


Zoom In | Zoom Out | Reset | Add To New Card | Existing Card

Subject System Topic

Block Time Remaining: 00:05:11
TUTOR

7 | Feedback | Suspend | End Block

1 2 3 4 5 6 7 8 9 10 11 12 13 14 15 16 17 18 19 20 21 22 23 24 25 26 27 28 29 30

A 17-year-old girl comes to the office with her mother for evaluation of urinary frequency and urgency. She has also noticed scant vaginal discharge. The symptoms started 2 days ago. The patient has never had similar symptoms before and has no chronic medical problems. She takes a combination oral contraceptive daily and has been sexually active with multiple partners over the last year. She is a high school student and does not use tobacco or alcohol. A urine sample is obtained for urinalysis and culture. Which of the following additional findings would be most specific for a diagnosis of pyelonephritis?

A. Abdominal pain

B. Bacteriuria

C. Fever

D. Microscopic hematuria

E. Sterile pyuria

F. White blood cell casts

Submit

1 2 3 4 5 6 7 8 9 10 11 12 13 14 15 16 17 18 19 20 21 22 23 24 25 26 27 28 29 30

A 17-year-old girl comes to the office with her mother for evaluation of urinary frequency and urgency. She has also noticed scant vaginal discharge. The symptoms started 2 days ago. The patient has never had similar symptoms before and has no chronic medical problems. She takes a combination oral contraceptive daily and has been sexually active with multiple partners over the last year. She is a high school student and does not use tobacco or alcohol. A urine sample is obtained for urinalysis and culture. Which of the following additional findings would be most specific for a diagnosis of pyelonephritis?

- A. Abdominal pain (0%)
- B. Bacteriuria (5%)
- C. Fever (10%)
- D. Microscopic hematuria (2%)
- E. Sterile pyuria (3%)
- ✓ F. White blood cell casts (77%)

Omitted
Correct answer
F

77%
Answered correctly

02 secs
Time Spent

02/17/2020
Last Updated

## Explanation

Women are more susceptible to urinary tract infections (UTIs) as their urethra is both closer to the rectum and shorter than that of men. Sexual intercourse is often a precipitating factor for UTIs.

Urethritis and cystitis are both characterized by dysuria, frequency, urgency, pyuria, and bacteriuria, but suprapubic pressure and tenderness is

Women are more susceptible to urinary tract infections (UTIs) as their urethra is both closer to the rectum and shorter than that of men. Sexual intercourse is often a precipitating factor for UTIs.

Urethritis and cystitis are both characterized by dysuria, frequency, urgency, pyuria, and bacteriuria, but suprapubic pressure and tenderness is more specific to cystitis. If pathogens ascend via the ureter to penetrate the kidney parenchyma, symptoms of acute **pyelonephritis** including fever, chills, nausea, vomiting, flank/abdominal pain, and costovertebral angle tenderness develop. Urine sediment microscopy reveals white blood cells (WBCs), **WBC casts**, and bacteria.

Pyuria and bacteriuria are also found in infections of the lower urinary tract, but WBC casts are pathognomonic for pyelonephritis in the setting of UTI. They are formed only in tubules, where WBCs precipitate with Tamm-Horsfall protein secreted by tubular epithelial cells. WBC casts can also be seen with acute interstitial nephritis, which often presents with low-grade fever and findings of acute kidney injury (urinary symptoms are not present).

**(Choices A and C)** Fever (a sign of any systemic infection) and abdominal pain are nonspecific symptoms. They can be present in acute pyelonephritis and in numerous other conditions, such as pelvic inflammatory disease. Mild/moderate urinary symptoms can also occur with pelvic infection/inflammation of any cause.

**(Choices B and D)** Bacteriuria and microscopic hematuria are found in both upper (acute pyelonephritis) and lower (cystitis, urethritis) UTIs.

**(Choice E)** Sterile pyuria (WBCs, but no bacteria) occurs in a small number of patients with acute pyelonephritis, but it can also be seen with nongonococcal urethritis caused by *Chlamydia* or *Ureaplasma*.

**Educational objective:**
Pyuria and bacteriuria are found in both upper and lower urinary tract infections (UTIs). However, white blood cell casts only form in the renal tubules and are pathognomonic for acute pyelonephritis when accompanied by symptoms of acute UTI.

| Pathology | Renal, Urinary Systems & Electrolytes | Urinary tract infection |
|---|---|---|
| Subject | System | Topic |

A 58-year-old man comes to the office due to problems urinating. Over the past year, he has had difficulty initiating urination and has noticed a weakened urine stream. He has also had frequent nocturnal voiding. The patient has not passed any visible blood clots and has had no dysuria, fever, recent illnesses, or urinary trauma. He has no other medical conditions and takes no medications. Vital signs are within normal limits. Rectal examination reveals a smooth, enlarged prostate with no tenderness to palpation. Prostate specific antigen is within normal range. Urinalysis reveals 20-30 red blood cells per high power field and no urinary casts. Cystoscopy is performed and shows increased bladder wall trabeculations with normal appearing mucosa. Which of the following is the most likely cause of this patient's hematuria?

A. Acquired bleeding disorder

B. Friable prostatic blood vessels

C. Glomerulonephritis

D. Interstitial cystitis

E. Transitional cell carcinoma of bladder

Submit

1 2 3 4 5 6 7 8 9 10 11 12 13 14 15 16 17 18 19 20 21 22 23 24 25 26 27 28 29 30

A 58-year-old man comes to the office due to problems urinating. Over the past year, he has had difficulty initiating urination and has noticed a weakened urine stream. He has also had frequent nocturnal voiding. The patient has not passed any visible blood clots and has had no dysuria, fever, recent illnesses, or urinary trauma. He has no other medical conditions and takes no medications. Vital signs are within normal limits. Rectal examination reveals a smooth, enlarged prostate with no tenderness to palpation. Prostate specific antigen is within normal range. Urinalysis reveals 20-30 red blood cells per high power field and no urinary casts. Cystoscopy is performed and shows increased bladder wall trabeculations with normal appearing mucosa. Which of the following is the most likely cause of this patient's hematuria?

- A. Acquired bleeding disorder (0%)
- ✓ B. Friable prostatic blood vessels (35%)
- C. Glomerulonephritis (2%)
- D. Interstitial cystitis (26%)
- E. Transitional cell carcinoma of bladder (34%)

Omitted
Correct answer
B

35%
Answered correctly

01 sec
Time Spent

03/30/2020
Last Updated

Explanation

**Benign prostatic hyperplasia (BPH)**

## Benign prostatic hyperplasia (BPH)

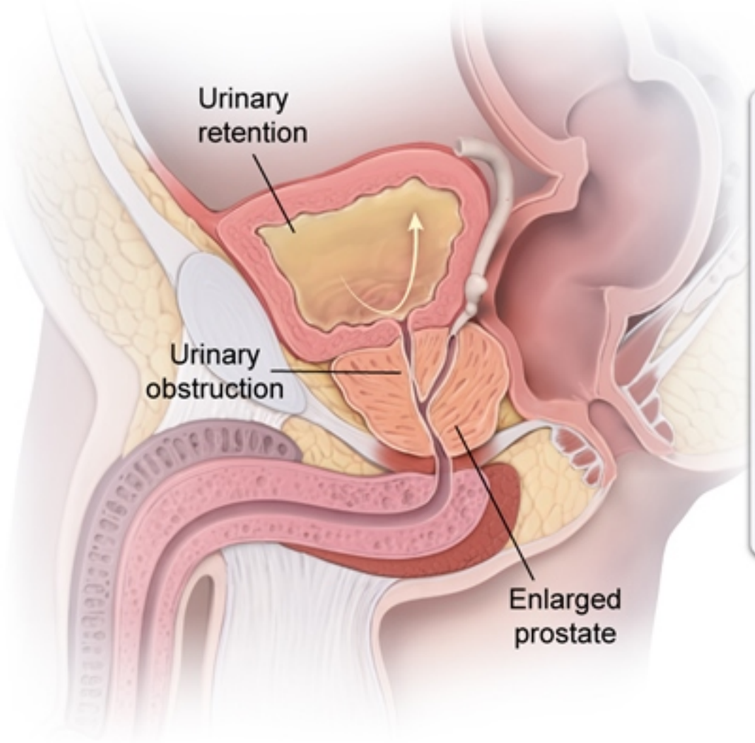


**Voiding (obstructive) symptoms**

- Weak urinary stream
- Intermittency
- Incomplete emptying
- Hesitancy
- Straining to void

**Storage (irritative, filling) symptoms**

- Frequency
- Urgency
- Nocturia
- Incontinence

©UWorld

This patient's urinary hesitancy, weakened urinary stream, and nocturia in the setting of an enlarged, nontender prostate raises strong suspicion for **benign prostatic hyperplasia** (BPH), a common condition in men age >50. In BPH, stromal and glandular hyperplasia in the periurethral and transitional zone can impinge the urethra, leading to progressive urinary voiding (eg, hesitancy, weakened stream) and storage (eg, nocturia, frequency) symptoms. The diagnosis is generally confirmed when examination reveals a smooth, **large, non-tender prostate**.

**Microscopic or gross hematuria** can sometimes arise in patients with BPH due to the formation of new, **friable blood vessels** in the area of prostatic hyperplasia. Further examination with cystoscopy is generally warranted to rule out other (potentially life-threatening) causes of hematuria such as bladder cancer and urinary calculi. Cystoscopy in those with BPH often shows **increased detrusor wall trabeculations** due

©UWorld

This patient's urinary hesitancy, weakened urinary stream, and nocturia in the setting of an enlarged, nontender prostate raises strong suspicion for **benign prostatic hyperplasia** (BPH), a common condition in men age >50. In BPH, stromal and glandular hyperplasia in the periurethral and transitional zone can impinge the urethra, leading to progressive urinary voiding (eg, hesitancy, weakened stream) and storage (eg, nocturia, frequency) symptoms. The diagnosis is generally confirmed when examination reveals a smooth, **large, non-tender prostate**.

**Microscopic or gross hematuria** can sometimes arise in patients with BPH due to the formation of new, **friable blood vessels** in the area of prostatic hyperplasia. Further examination with cystoscopy is generally warranted to rule out other (potentially life-threatening) causes of hematuria such as bladder cancer and urinary calculi. Cystoscopy in those with BPH often shows **increased detrusor wall trabeculations** due to detrusor muscle hypertrophy (to generate increased pressure to overcome urethral obstruction).

**(Choice A)** Hematuria is typically caused by urinary tract pathology rather than a systemic bleeding disorder. Furthermore, systemic bleeding disorders are often associated with other sites of mucosal bleeding (eg, nosebleed) or bruising. The presence of lower urinary tract symptoms and prostatic enlargement make BPH more likely.

**(Choice C)** Glomerulonephritis can cause hematuria but is also associated with red blood cell casts and dysmorphic red cells. Furthermore, this patient's increased bladder wall trabeculations and prostatic enlargement make BPH more likely.

**(Choice D)** Although interstitial cystitis can cause urinary frequency, urgency, and nocturia, it is more common in women and usually presents with suprapubic pain (often worse with bladder filling and better with voiding). Furthermore, hematuria is uncommon, and cystoscopy is likely to show patchy erythema and petechiae.

**(Choice E)** Bladder cancer often presents with painless hematuria and storage symptoms (eg, frequency, urgency). However, voiding symptoms (eg, hesitancy, decreased force of stream) are less common, and most cases arise in the setting of advanced age, smoking, or chemical/carcinogen exposures in the workplace. Furthermore, cystoscopy generally reveals a mucosal mass, not increased trabeculations.

**Educational objective:**
Benign prostatic hyperplasia (BPH) is associated with stromal and glandular growth in the periurethral and transitional zone of the prostate. The hyperplastic cells are supported by the formation of new blood vessels, which are friable and prone to bleeding. Therefore, BPH is often associated with microscopic or gross hematuria.

hematuria such as bladder cancer and urinary calculi. Cystoscopy in those with BPH often shows **increased detrusor wall trabeculations** due to detrusor muscle hypertrophy (to generate increased pressure to overcome urethral obstruction).

**(Choice A)** Hematuria is typically caused by urinary tract pathology rather than a systemic bleeding disorder. Furthermore, systemic bleeding disorders are often associated with other sites of mucosal bleeding (eg, nosebleed) or bruising. The presence of lower urinary tract symptoms and prostatic enlargement make BPH more likely.

**(Choice C)** Glomerulonephritis can cause hematuria but is also associated with red blood cell casts and dysmorphic red cells. Furthermore, this patient's increased bladder wall trabeculations and prostatic enlargement make BPH more likely.

**(Choice D)** Although interstitial cystitis can cause urinary frequency, urgency, and nocturia, it is more common in women and usually presents with suprapubic pain (often worse with bladder filling and better with voiding). Furthermore, hematuria is uncommon, and cystoscopy is likely to show patchy erythema and petechiae.

**(Choice E)** Bladder cancer often presents with painless hematuria and storage symptoms (eg, frequency, urgency). However, voiding symptoms (eg, hesitancy, decreased force of stream) are less common, and most cases arise in the setting of advanced age, smoking, or chemical/carcinogen exposures in the workplace. Furthermore, cystoscopy generally reveals a mucosal mass, not increased trabeculations.

**Educational objective:**
Benign prostatic hyperplasia (BPH) is associated with stromal and glandular growth in the periurethral and transitional zone of the prostate. The hyperplastic cells are supported by the formation of new blood vessels, which are friable and prone to bleeding. Therefore, BPH is often associated with microscopic or gross hematuria.

**References**

- Assessment of asymptomatic microscopic hematuria in adults.

| Pathology | Renal, Urinary Systems & Electrolytes | Benign prostatic hyperplasia |
|---|---|---|
| Subject | System | Topic |

Copyright © UWorld. All rights reserved.

1 2 3 4 5 6 7 8 9 10 11 12 13 14 15 16 17 18 19 20 21 22 23 24 25 26 27 28 29 30

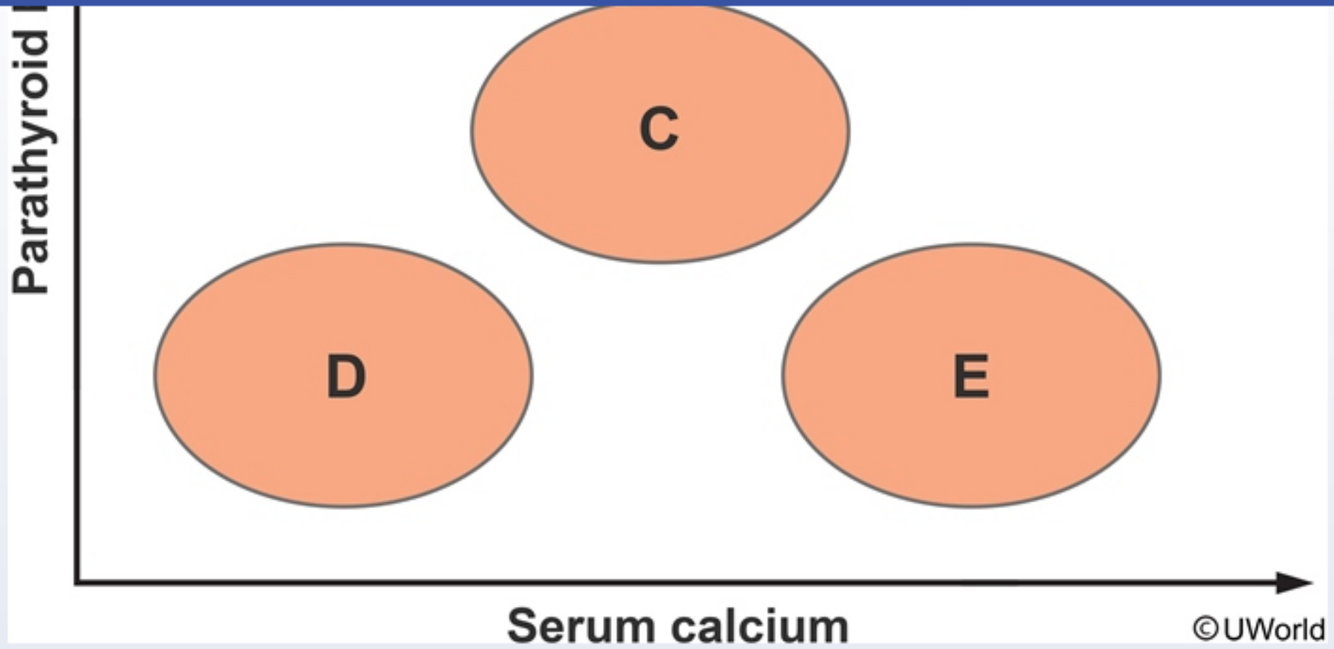


A. A

B. B

C. C

D. D

E. E

Submit

A 64-year-old man comes to the office with fatigue. He has hypertension and poorly controlled diabetes complicated by nephropathy and peripheral neuropathy. His renal function has declined steadily over the last few years. On examination, his conjunctivae are pale and he has bilateral 1+ peripheral edema. Laboratory results are as follows:

| Serum chemistry | |
|---|---|
| Sodium | 133 mEq/L |
| Potassium | 4.4 mEq/L |
| Chloride | 98 mEq/L |
| Bicarbonate | 22 mEq/L |
| Blood urea nitrogen | 76 mg/dL |
| Creatinine | 5.8 mg/dL |

On the graph below, area "C" shows the normal relationship between serum concentrations of free calcium and parathyroid hormone. Which of the following areas most likely represents this patient's current metabolic state?

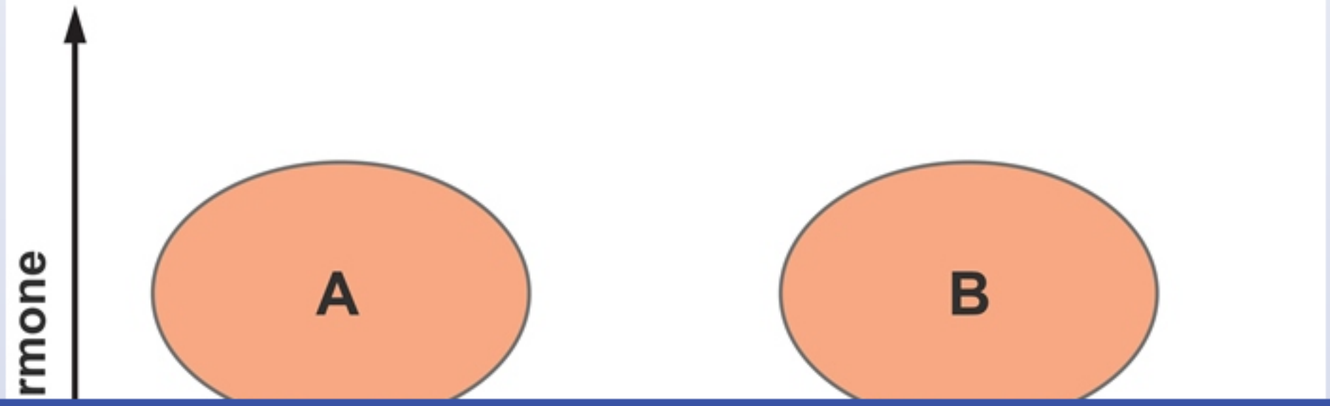

On the graph below, area "C" shows the normal relationship between serum concentrations of free calcium and parathyroid hormone. Which of the following areas most likely represents this patient's current metabolic state?

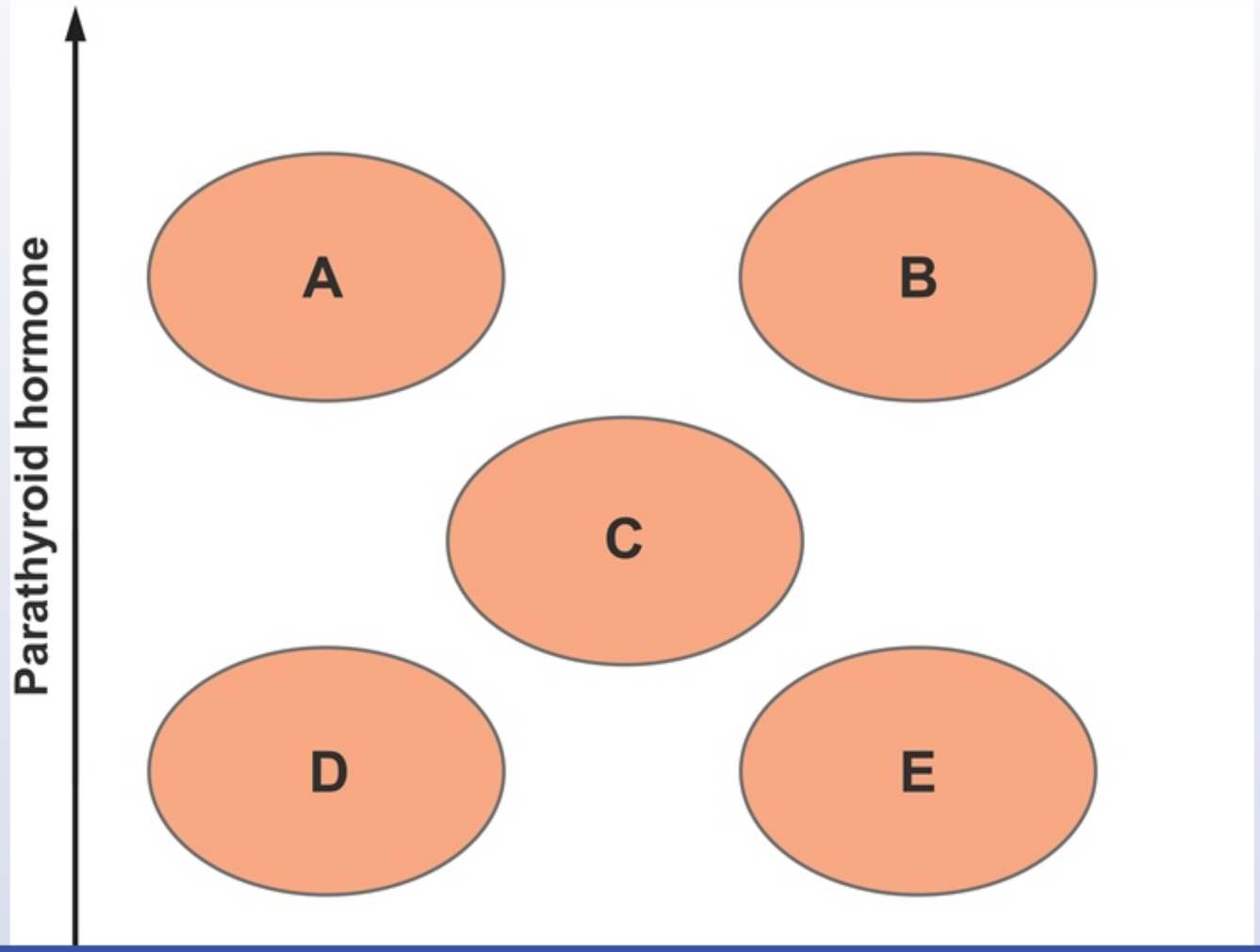

Settings

1 2 3 4 5 6 7 8 9 10 11 12 13 14 15 16 17 18 19 20 21 22 23 24 25 26 27 28 29 30

Item 23 of 39
Question Id: 979

Mark | Previous | Next | Full Screen | Tutorial | Lab Values | Notes | Calculator | Reverse Color | Text Zoom | Settings

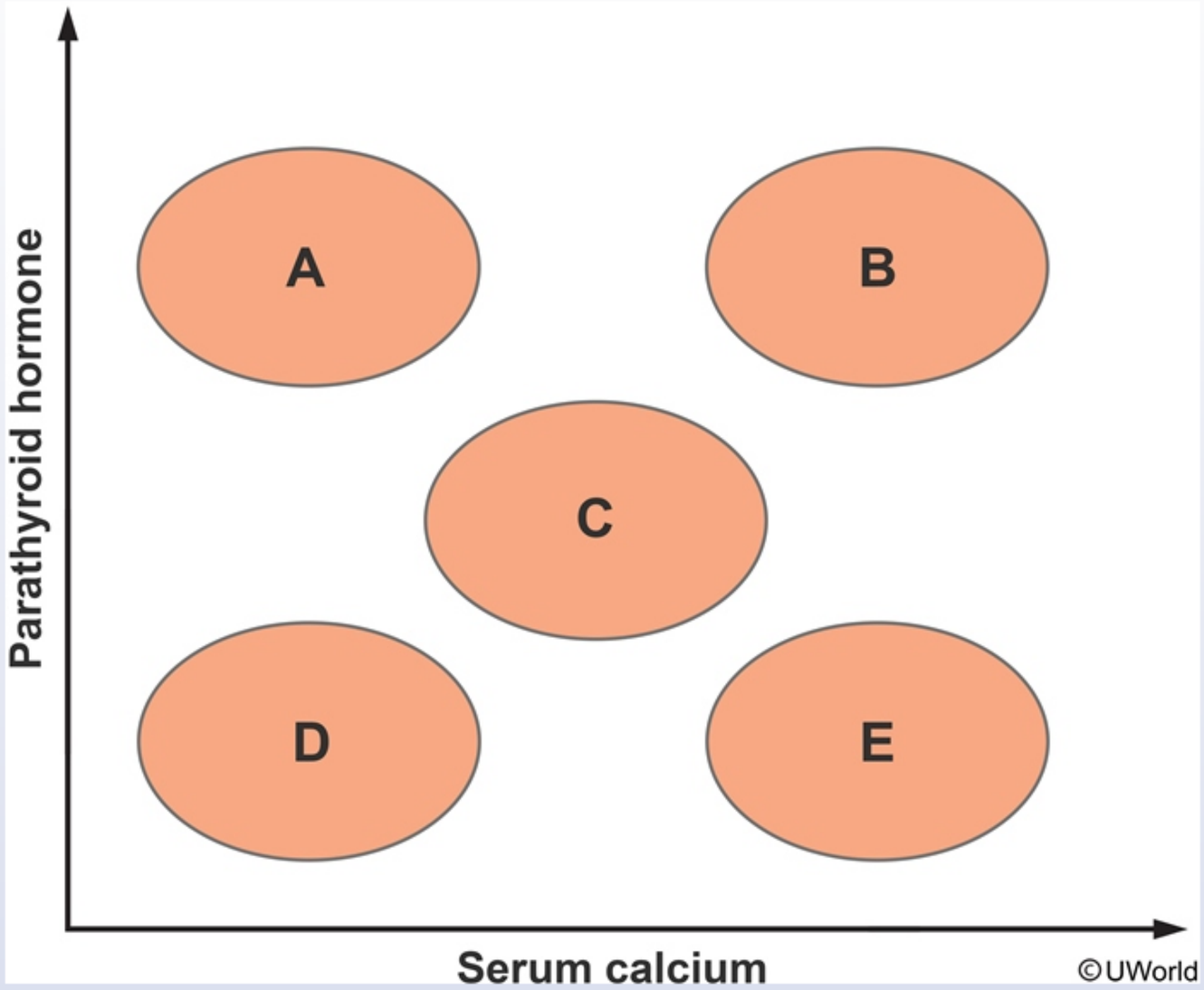


A. A

Block Time Remaining: 00:05:22
TUTOR

Feedback | Suspend | End Block

1 2 3 4 5 6 7 8 9 10 11 12 13 14 15 16 17 18 19 20 21 22 23 24 25 26 27 28 29 30

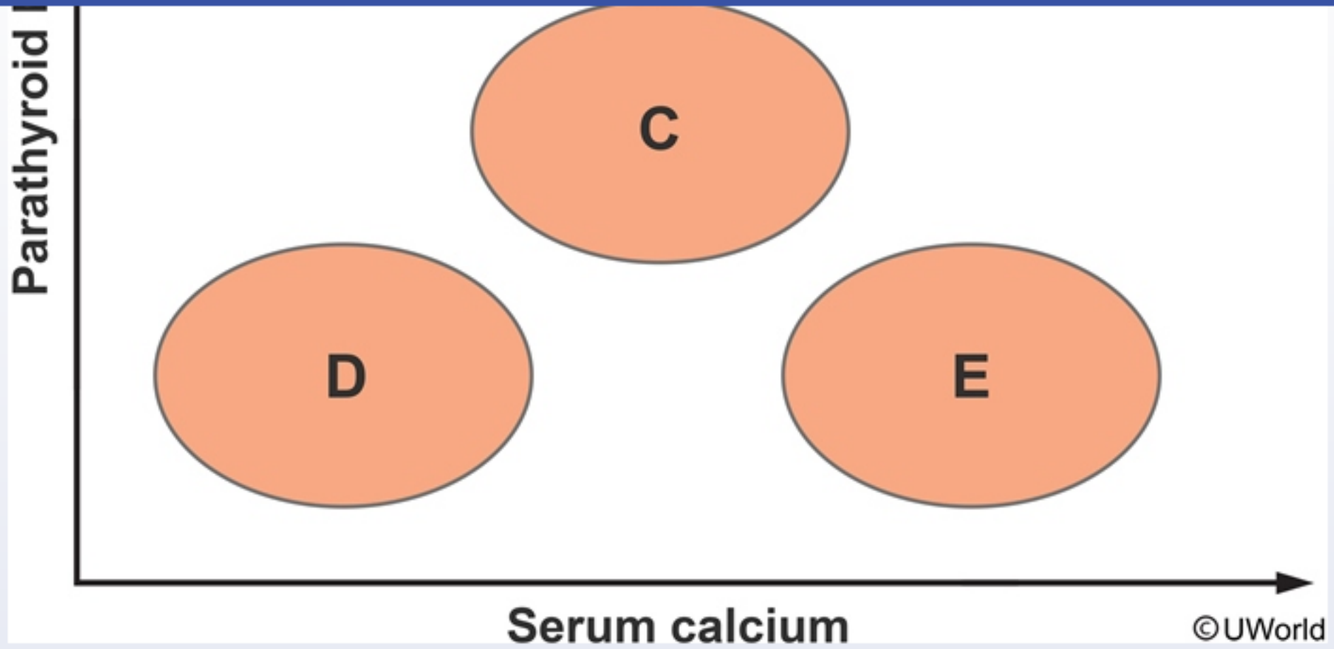


- ✓ A. A (77%)
- B. B (8%)
- C. C (3%)
- D. D (5%)
- E. E (5%)

Omitted
Correct answer

77%
Answered correctly

10 secs
Time Spent

06/13/2020
Last Updated

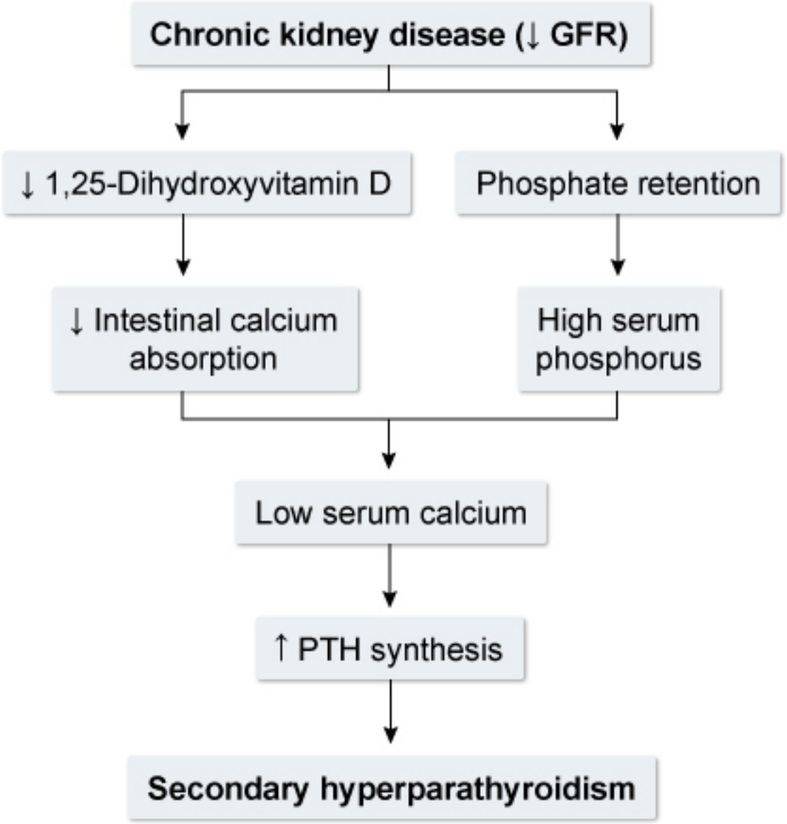


**GFR** = glomerular filtration rate; **PTH** = parathyroid hormone.

©UWorld

In the physiologic state, parathyroid hormone (PTH) causes an overall increase in serum calcium ($Ca^{2+}$) and a decrease serum phosphate ($PO_4$) via the following effects:

- Increasing osteoclastic bone resorption, releasing $Ca^{2+}$ and $PO_4$ into serum
- Increasing renal calcium reabsorption and reducing phosphate reabsorption

In the physiologic state, parathyroid hormone (PTH) causes an overall increase in serum calcium ($Ca^{2+}$) and a decrease serum phosphate ($PO_4$) via the following effects:

- Increasing osteoclastic bone resorption, releasing $Ca^{2+}$ and $PO_4$ into serum
- Increasing renal calcium reabsorption and reducing phosphate reabsorption
- Increasing formation of 1,25-dihydroxycholecalciferol (by upregulating renal 1-alpha-hydroxylase), which increases intestinal $Ca^{2+}$ and $PO_4$ absorption

PTH production is very sensitive to small changes in serum free $Ca^{2+}$ and is regulated by a negative feedback mechanism: increased $Ca^{2+}$ will suppress PTH, but decreased $Ca^{2+}$ will increase PTH.

In **chronic kidney disease** (CKD), $PO_4$ clearance declines due to the fall in GFR. The **increased $PO_4$** binds free serum $Ca^{2+}$, resulting in **hypocalcemia**. Loss of normal renal parenchyma reduces 1,25-dihydroxyvitamin D synthesis, resulting in a significant decline in intestinal $Ca^{2+}$ absorption and $Ca^{2+}$ release from bone. This further exacerbates the hypocalcemia, which along with hyperphosphatemia and low calcitriol, stimulates PTH production (**secondary hyperparathyroidism**).

**(Choice B)** In primary hyperparathyroidism, serum $Ca^{2+}$ is elevated but does not suppress PTH due to autonomous gland function. In longstanding CKD, PTH release may become independent of $Ca^{2+}$ levels due to chronic parathyroid cell stimulation; PTH remains elevated despite 1,25-dihydroxyvitamin D and $Ca^{2+}$ supplementation (**tertiary hyperparathyroidism**). However, this is less common than secondary hyperparathyroidism and is usually seen in patients with end-stage renal disease (ie, on dialysis).

**(Choice C)** Calcitriol and $Ca^{2+}$ supplementation in patients with CKD often returns PTH and $Ca^{2+}$ levels to normal.

**(Choice D)** Low PTH with hypocalcemia and hyperphosphatemia is seen in hypoparathyroidism.

**(Choice E)** High serum $Ca^{2+}$ with low PTH is seen in patients with PTH-independent causes of hypercalcemia, which include hypercalcemia of malignancy, vitamin D toxicity, excessive $Ca^{2+}$ ingestion, thyrotoxicosis, and immobilization ($Ca^{2+}$ resorbed from inactive bones).

**Educational objective:**
Chronic kidney disease usually causes hyperphosphatemia (binds serum $Ca^{2+}$) and low 1,25-dihydroxyvitamin D (decreases intestinal $Ca^{2+}$ absorption and $Ca^{2+}$ release from bone). The resulting hypocalcemia stimulates release of parathyroid hormone, causing secondary

**hypocalcemia**. Loss of normal renal parenchyma reduces 1,25-dihydroxyvitamin D synthesis, resulting in a significant decline in intestinal $Ca^{2+}$ absorption and $Ca^{2+}$ release from bone. This further exacerbates the hypocalcemia, which along with hyperphosphatemia and low calcitriol, stimulates PTH production (**secondary hyperparathyroidism**).

**(Choice B)** In primary hyperparathyroidism, serum $Ca^{2+}$ is elevated but does not suppress PTH due to autonomous gland function. In longstanding CKD, PTH release may become independent of $Ca^{2+}$ levels due to chronic parathyroid cell stimulation; PTH remains elevated despite 1,25-dihydroxyvitamin D and $Ca^{2+}$ supplementation (**tertiary hyperparathyroidism**). However, this is less common than secondary hyperparathyroidism and is usually seen in patients with end-stage renal disease (ie, on dialysis).

**(Choice C)** Calcitriol and $Ca^{2+}$ supplementation in patients with CKD often returns PTH and $Ca^{2+}$ levels to normal.

**(Choice D)** Low PTH with hypocalcemia and hyperphosphatemia is seen in hypoparathyroidism.

**(Choice E)** High serum $Ca^{2+}$ with low PTH is seen in patients with PTH-independent causes of hypercalcemia, which include hypercalcemia of malignancy, vitamin D toxicity, excessive $Ca^{2+}$ ingestion, thyrotoxicosis, and immobilization ($Ca^{2+}$ resorbed from inactive bones).

**Educational objective:**
Chronic kidney disease usually causes hyperphosphatemia (binds serum $Ca^{2+}$) and low 1,25-dihydroxyvitamin D (decreases intestinal $Ca^{2+}$ absorption and $Ca^{2+}$ release from bone). The resulting hypocalcemia stimulates release of parathyroid hormone, causing secondary hyperparathyroidism.

**References**


- Hyperparathyroidism in chronic kidney disease patients: an update on current pharmacotherapy.
- Secondary and tertiary hyperparathyroidism.


| Pathology | Renal, Urinary Systems & Electrolytes | Chronic kidney disease |
|---|---|---|
| Subject | System | Topic |

Copyright © UWorld. All rights reserved.

A 64-year-old man comes to the office due to several episodes of intermittent hematuria over the past 2 months. He has had no abdominal pain, burning on urination, or fever but has lost 4.5 kg (10 lb) since the onset of symptoms. The patient has smoked a pack of cigarettes daily for 30 years. Vital signs are within normal limits. The abdomen is soft, nontender, and nondistended. An enlarged and firm prostate is palpated on digital rectal examination. Serum calcium is 12.3 mg/dL. Urinalysis shows 30-40 red blood cells/hpf, negative protein, and no casts. A CT scan of the abdomen is shown below.

[redacted]

1
2
3
4
5
6
7
8
9
10
11
12
13
14
15
16
17
18
19
20
21
22
23
24
25
26
27
28
29
30

the abdomen is shown below.

Which of the following is the most likely diagnosis?

A. Bladder cancer

1 2 3 4 5 6 7 8 9 10 11 12 13 14 15 16 17 18 19 20 21 22 23 24 25 26 27 28 29 30

Which of the following is the most likely diagnosis?

- A. Bladder cancer
- B. Pheochromocytoma
- C. Polycystic kidney disease
- D. Prostate cancer
- E. Renal cell carcinoma
- F. Ureterolithiasis

Submit

1 2 3 4 5 6 7 8 9 10 11 12 13 14 15 16 17 18 19 20 21 22 23 24 25 26 27 28 29 30

Which of the following is the most likely diagnosis?

- A. Bladder cancer (7%)
- B. Pheochromocytoma (0%)
- C. Polycystic kidney disease (5%)
- D. Prostate cancer (10%)
- ✓ E. Renal cell carcinoma (74%)
- F. Ureterolithiasis (2%)

Omitted
Correct answer

74%
Answered correctly

06 secs
Time Spent

03/04/2020
Last Updated

Explanation

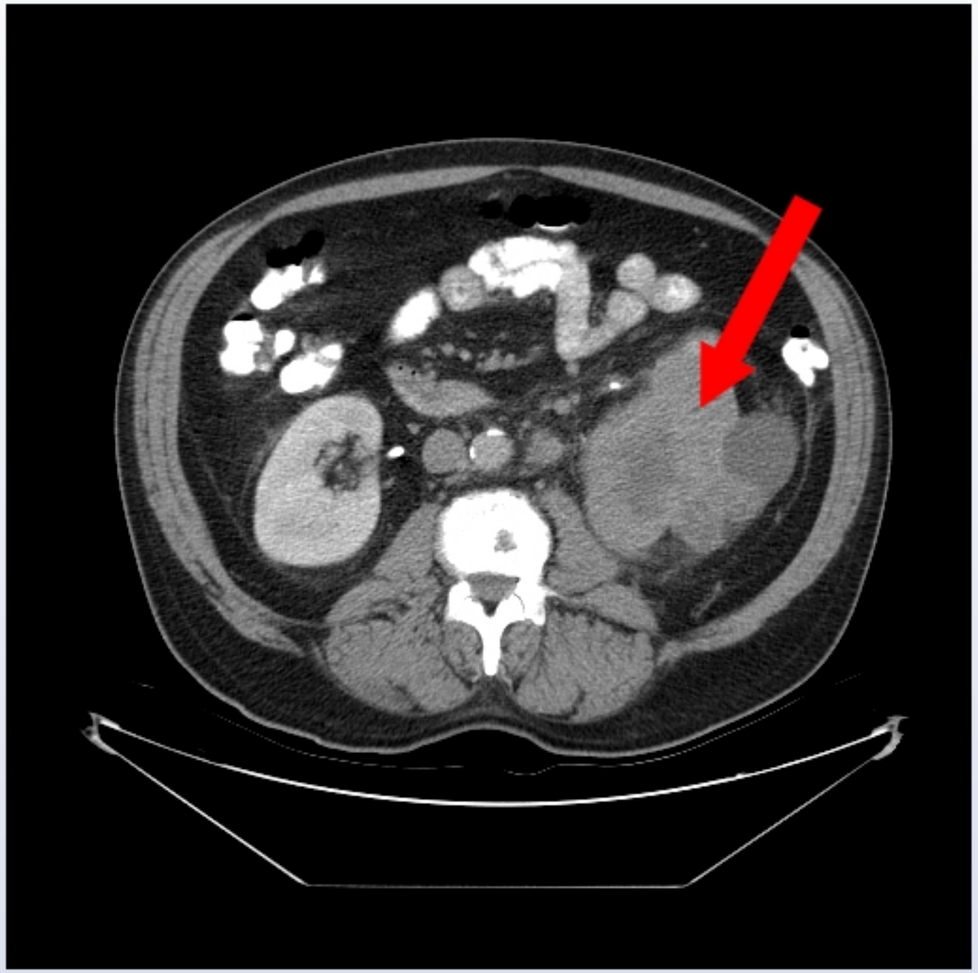

This patient with an extensive smoking history, 4.5-kg weight loss, painless hematuria, hypercalcemia, and renal mass (arrow) likely has **renal cell carcinoma** (RCC). RCC originates in the renal cortex and accounts for up to 90% of primary renal tumors. It is often identified incidentally on

[redacted]

This patient with an extensive smoking history, 4.5-kg weight loss, painless hematuria, hypercalcemia, and renal mass (arrow) likely has **renal cell carcinoma** (RCC). RCC originates in the renal cortex and accounts for up to 90% of primary renal tumors. It is often identified incidentally on radiographic imaging, and many individuals remain **asymptomatic** until the disease is relatively advanced. Hematuria is the most common symptom, and **painless hematuria** in an adult should raise suspicion for a genitourinary malignancy. Patients may also have **flank pain** and a palpable **abdominal mass** at the time of presentation.

Paraneoplastic syndromes are common in RCC due to the secretion of biologically active substances by the tumor cells. **Hypercalcemia** is frequently seen due to increased production of parathyroid hormone–related peptide or overproduction of prostaglandins that promote bony resorption. **Erythrocytosis** (due to ectopic erythropoietin production) and hepatic dysfunction unrelated to liver metastases may also be seen.

**(Choice A)** Bladder cancer is another common cause of hematuria and weight loss; however, CT scan would demonstrate a bladder mass. This malignancy tends to metastasize to the liver, bones, and lungs, not the kidney. Although hypercalcemia may occur occasionally, it is more strongly associated with RCC.

**(Choice B)** Pheochromocytoma can cause severe, episodic hypertension associated with headaches, anxiety, palpitations, and sweating. A CT scan would reveal a suprarenal mass, and urine catecholamines and metanephrine would be elevated. Hematuria is not seen.

**(Choice C)** Polycystic kidney disease can cause hematuria; however, flank pain is common, and imaging would show bilateral renal cysts, not a unilateral mass. In addition, weight loss and hypercalcemia would be unexpected.

**(Choice D)** Prostate cancer typically presents with discrete nodules or asymmetric induration of the prostate on digital rectal examination. Diffuse, symmetric enlargement and firmness of the prostate are more suggestive of benign prostatic hyperplasia.

**(Choice F)** Ureterolithiasis is a common cause of hematuria, and patients with hypercalcemia from other causes (eg, hyperparathyroidism) are predisposed to stone formation. Although there are small kidney stones on this patient's imaging, this would not explain the large renal mass and unintended weight loss, which are highly suggestive of malignancy.

**Educational objective:**
Classic signs and symptoms of renal cell carcinoma (RCC) include hematuria, an abdominal mass, flank pain, and weight loss. Hypercalcemia

palpable **abdominal mass** at the time of presentation.

Paraneoplastic syndromes are common in RCC due to the secretion of biologically active substances by the tumor cells. **Hypercalcemia** is frequently seen due to increased production of parathyroid hormone–related peptide or overproduction of prostaglandins that promote bony resorption. **Erythrocytosis** (due to ectopic erythropoietin production) and hepatic dysfunction unrelated to liver metastases may also be seen.

**(Choice A)** Bladder cancer is another common cause of hematuria and weight loss; however, CT scan would demonstrate a bladder mass. This malignancy tends to metastasize to the liver, bones, and lungs, not the kidney. Although hypercalcemia may occur occasionally, it is more strongly associated with RCC.

**(Choice B)** Pheochromocytoma can cause severe, episodic hypertension associated with headaches, anxiety, palpitations, and sweating. A CT scan would reveal a suprarenal mass, and urine catecholamines and metanephrine would be elevated. Hematuria is not seen.

**(Choice C)** Polycystic kidney disease can cause hematuria; however, flank pain is common, and imaging would show bilateral renal cysts, not a unilateral mass. In addition, weight loss and hypercalcemia would be unexpected.

**(Choice D)** Prostate cancer typically presents with discrete nodules or asymmetric induration of the prostate on digital rectal examination. Diffuse, symmetric enlargement and firmness of the prostate are more suggestive of benign prostatic hyperplasia.

**(Choice F)** Ureterolithiasis is a common cause of hematuria, and patients with hypercalcemia from other causes (eg, hyperparathyroidism) are predisposed to stone formation. Although there are small kidney stones on this patient's imaging, this would not explain the large renal mass and unintended weight loss, which are highly suggestive of malignancy.

**Educational objective:**
Classic signs and symptoms of renal cell carcinoma (RCC) include hematuria, an abdominal mass, flank pain, and weight loss. Hypercalcemia and erythrocytosis are common paraneoplastic syndromes associated with RCC.

| Pathology | Renal, Urinary Systems & Electrolytes | Renal cell carcinoma |
|---|---|---|
| Subject | System | Topic |

Copyright © UWorld. All rights reserved.

Settings

1
2
3
4
5
6
7
8
9
10
11
12
13
14
15
16
17
18
19
20
21
22
23
24
25
26
27
28
29
30

Item 24 of 39
Question Id: 11806

Mark | Previous | Next | Full Screen | Tutorial | Lab Values | Notes | Calculator | Reverse Color | Text Zoom | Settings

palpable **abdominal mass** at the time of presentation?

Exhibit Display

Zoom In | Zoom Out | Reset | Add To New Card | Existing Card

Block Time Remaining: 00:05:30
TUTOR

3 | Feedback | Suspend | End Block

A 64-year-old man who recently moved to the area comes to the office for a new patient evaluation. He has chronic low back pain, resulting from an injury 8 years ago, for which he uses several over-the-counter analgesics. Most recently, the patient has been taking naproxen daily. He has no other joint pain, fever, rash, urinary symptoms, or other medical conditions. Blood pressure is 135/70 mm Hg and pulse is 78/min. Examination shows trace lower extremity edema. Neurologic and musculoskeletal examinations reveal no abnormalities. Laboratory results show blood counts within normal limits, blood urea nitrogen of 12 mg/dL, and serum creatinine of 2.0 mg/dL. Urinalysis reveals 1+ protein and 3-4 white blood cells/hpf. Renal ultrasound demonstrates bilateral shrunken and irregular kidneys with a few papillary calcifications. Which of the following is the most likely cause of this patient's renal dysfunction?

- A. Chronic interstitial nephritis
- B. Chronic pyelonephritis
- C. Crystal nephropathy
- D. Focal segmental glomerular sclerosis
- E. Ischemic tubular necrosis
- F. Renal artery stenosis

Submit

A 64-year-old man who recently moved to the area comes to the office for a new patient evaluation. He has chronic low back pain, resulting from an injury 8 years ago, for which he uses several over-the-counter analgesics. Most recently, the patient has been taking naproxen daily. He has no other joint pain, fever, rash, urinary symptoms, or other medical conditions. Blood pressure is 135/70 mm Hg and pulse is 78/min. Examination shows trace lower extremity edema. Neurologic and musculoskeletal examinations reveal no abnormalities. Laboratory results show blood counts within normal limits, blood urea nitrogen of 12 mg/dL, and serum creatinine of 2.0 mg/dL. Urinalysis reveals 1+ protein and 3-4 white blood cells/hpf. Renal ultrasound demonstrates bilateral shrunken and irregular kidneys with a few papillary calcifications. Which of the following is the most likely cause of this patient's renal dysfunction?

- ✓ A. Chronic interstitial nephritis (61%)
- B. Chronic pyelonephritis (7%)
- C. Crystal nephropathy (2%)
- D. Focal segmental glomerular sclerosis (3%)
- E. Ischemic tubular necrosis (16%)
- F. Renal artery stenosis (8%)

Omitted
Correct answer
A

61%
Answered correctly

02 secs
Time Spent

03/15/2020
Last Updated

Explanation

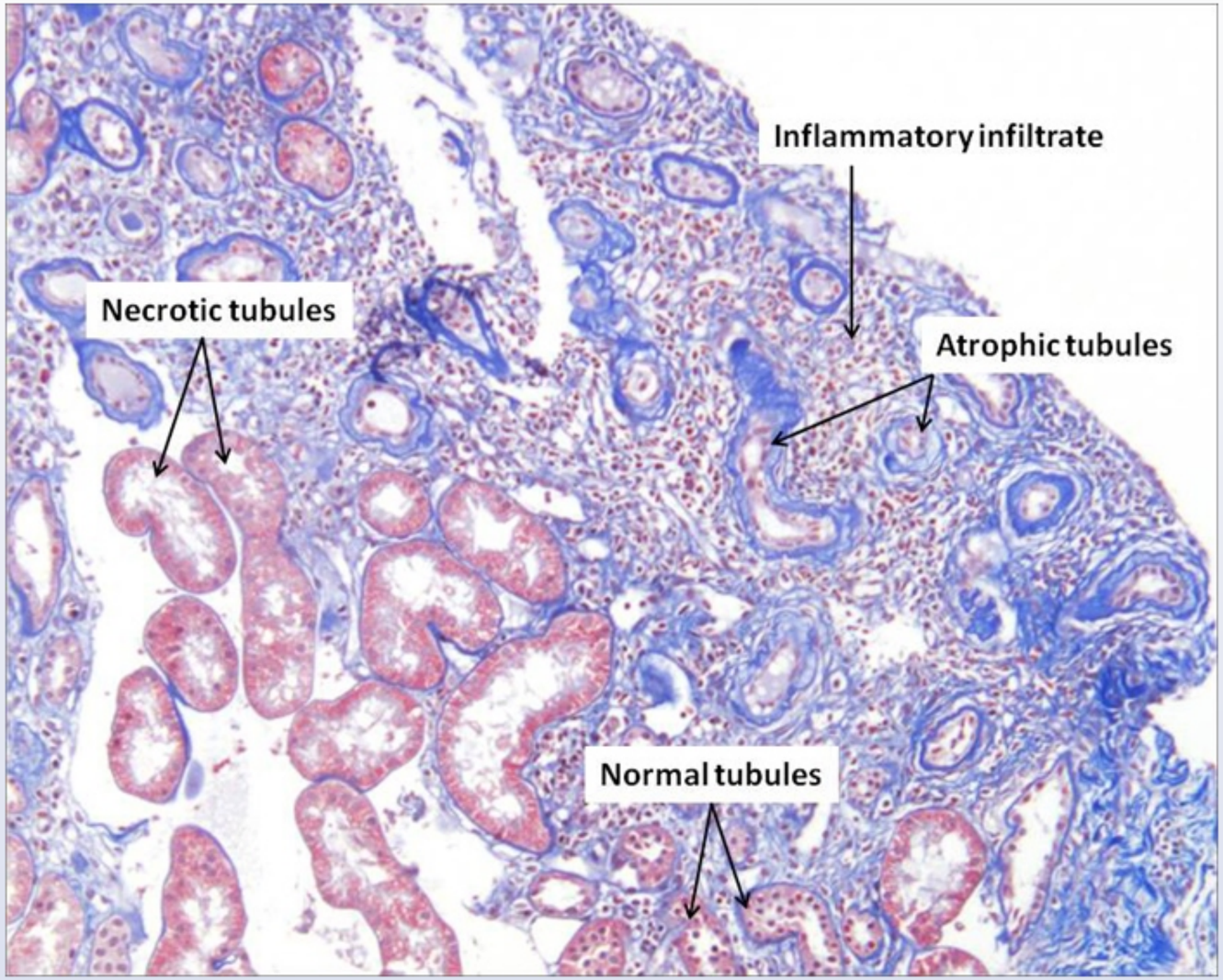


Over-the-counter analgesics such as nonsteroidal anti-inflammatory drugs (**NSAIDs**) can cause renal failure (**analgesic nephropathy**) if taken in large amounts over extended periods. Affected patients typically have a modest elevation in serum creatinine, mild proteinuria, and evidence of

Over-the-counter analgesics such as nonsteroidal anti-inflammatory drugs (**NSAIDs**) can cause renal failure (**analgesic nephropathy**) if taken in large amounts over extended periods. Affected patients typically have a modest elevation in serum creatinine, mild proteinuria, and evidence of tubular dysfunction (polyuria, nocturia). Microscopic hematuria and sterile pyuria (white cells without bacteria) may also be seen on urinalysis. NSAIDs concentrate in the renal medulla along the medullary osmotic gradient, with higher levels in the papillae. These drugs uncouple oxidative phosphorylation and increase oxidative stress, resulting in damage to tubular and vascular endothelial cells. Prolonged use results in **chronic interstitial nephritis** visualized as patchy interstitial inflammation with subsequent tubular atrophy and fibrosis, papillary necrosis, and scarring. Grossly, the kidneys appear shrunken with irregular contours and distortion of the caliceal architecture. NSAIDs also decrease prostaglandin synthesis, causing renal vasoconstriction which further increases the risk of **ischemic papillary necrosis**.

**(Choice B)** Chronic pyelonephritis can also cause chronic interstitial nephritis with papillary necrosis. However, urinalysis would be expected to demonstrate evidence of infection (eg, bacteria, nitrites, marked pyuria), and the patient would likely have flank pain and fever.

**(Choice C)** Acute crystal nephropathy presents with renal failure, and patients often have nausea, vomiting, or flank pain. Chronic crystalline nephropathy is most commonly seen in patients with gout or hyperuricemia secondary to urate deposition in the medullary interstitium.

**(Choice D)** Focal segmental glomerular sclerosis (FSGS) presents with nephrotic-range proteinuria. Drug-related secondary FSGS has been reported with the use of anabolic steroids or heroin but not NSAIDs.

**(Choice E)** Ischemic tubular necrosis usually occurs acutely after a prolonged period of hypotension (eg, sepsis, major surgery); muddy brown casts would be expected on urinalysis.

**(Choice F)** Symptoms of renal artery stenosis include resistant hypertension, recurrent flash pulmonary edema, and chronic kidney disease. The absence of hypertension and history of NSAID use are more consistent with chronic interstitial nephritis.

**Educational objective:**
Analgesic nephropathy is a form of chronic kidney disease caused by prolonged, heavy intake of nonsteroidal anti-inflammatory drugs and/or acetaminophen. Pathologic characteristics include chronic interstitial nephritis and papillary necrosis.

| Pathology | Renal, Urinary Systems & Electrolytes | NSAIDs |
|---|---|---|
| Subject | System | Topic |

A 35-year-old pregnant woman at 8 weeks gestation comes to the emergency department due to persistent nausea and vomiting. The patient has had intermittent nausea for the past week and vomiting for the past 3 days. Now, she is unable to tolerate solids or liquids. Temperature is 36.7 C (98 F), blood pressure is 90/64 mm Hg, pulse is 108/min, and respirations are 14/min. Mucous membranes are dry and capillary refill time is delayed. Cardiac examination shows sinus tachycardia and no murmurs. The abdomen is nontender and nondistended. Compared to her baseline, which of the following sets of serum electrolyte concentration abnormalities are most likely present in this patient?

| | Sodium | Potassium | Chloride | Bicarbonate |
|---|---|---|---|---|
| A. | ↓ | ↓ | ↓ | ↑ |
| B. | ↓ | Normal | ↓ | Normal |
| C. | Normal | ↑ | Normal | ↓ |
| D. | ↑ | Normal | ↑ | Normal |
| E. | Normal | ↑ | Normal | ↑ |
| F. | ↓ | ↓ | ↓ | ↓ |

Submit

1 2 3 4 5 6 7 8 9 10 11 12 13 14 15 16 17 18 19 20 21 22 23 24 25 26 27 28 29 30

A 35-year-old pregnant woman at 8 weeks gestation comes to the emergency department due to persistent nausea and vomiting. The patient has had intermittent nausea for the past week and vomiting for the past 3 days. Now, she is unable to tolerate solids or liquids. Temperature is 36.7 C (98 F), blood pressure is 90/64 mm Hg, pulse is 108/min, and respirations are 14/min. Mucous membranes are dry and capillary refill time is delayed. Cardiac examination shows sinus tachycardia and no murmurs. The abdomen is nontender and nondistended. Compared to her baseline, which of the following sets of serum electrolyte concentration abnormalities are most likely present in this patient?

| | Sodium | Potassium | Chloride | Bicarbonate |
|---|---|---|---|---|
| ✓ A. (71%) | ↓ | ↓ | ↓ | ↑ |
| B. (4%) | ↓ | Normal | ↓ | Normal |
| C. (2%) | Normal | ↑ | Normal | ↓ |
| D. (3%) | ↑ | Normal | ↑ | Normal |
| E. (3%) | Normal | ↑ | Normal | ↑ |
| F. (14%) | ↓ | ↓ | ↓ | ↓ |

Omitted
Correct answer
A

71%
Answered correctly

02 secs
Time Spent

04/20/2020
Last Updated

| Hypokalemic, hypochloremic metabolic alkalosis | |
|---|---|
| **Common etiologies** | • Gastric suction or severe vomiting<br>• Loop or thiazide diuretic overuse |
| **Pathophysiology** | • Gastric or renal $H^+$ losses **initiate** alkalosis<br>• Volume depletion activates RAAS<br>• ↑ renal $K^+$ & $H^+$ losses cause hypokalemia & **worsen** alkalosis<br>• Relatively greater loss of $Cl^-$ than $Na^+$ → profound $Cl^-$ depletion<br>• ↓ $Cl^-$ impairs renal $HCO_3^-$ excretion to **perpetuate** alkalosis |
| **Management** | • Remove or treat initiating factor<br>• $Cl^-$ repletion with normal saline corrects alkalosis |

RAAS = renin-angiotensin-aldosterone system.

This patient has had **severe vomiting** (suggestive of hyperemesis gravidarum) and now has multiple signs of **volume depletion** (eg, dry mucous membranes, delayed capillary refill time, tachycardia). Vomiting causes a significant loss of gastric $H^+$ from the body, which leads to **increased serum $HCO_3^-$** (metabolic alkalosis). There is also loss of water and salt (relatively more $Cl^-$ is lost than $Na^+$ due to high gastric quantity of HCl), leading to volume depletion that perpetuates the metabolic alkalosis and causes other electrolyte abnormalities.

Intravascular volume depletion decreases renal perfusion, resulting in activation of the **renin-angiotensin-aldosterone system**. Aldosterone stimulates $Na^+$ reabsorption and a lesser degree of passive $Cl^-$ reabsorption in the distal tubules of the kidneys in an effort to increase blood volume. The relatively greater loss of $Cl^-$ compared to $Na^+$ from both the stomach and kidneys leads to a large $Cl^-$ deficit and characteristic **hypochloremia**.

The aldosterone-mediated increase in $Na^+$ reabsorption comes at the expense of increased $K^+$ and $H^+$ excretion via the principal and alpha intercalated cells in the collecting duct. This leads to **hypokalemia** and exacerbation of the metabolic alkalosis. **Chloride depletion** then **perpetuates the metabolic alkalosis** because low tubular $Cl^-$ concentration impairs $HCO_3^-$ excretion via the pendrin pump on beta intercalated

RAAS = renin-angiotensin-aldosterone system.

This patient has had **severe vomiting** (suggestive of hyperemesis gravidarum) and now has multiple signs of **volume depletion** (eg, dry mucous membranes, delayed capillary refill time, tachycardia). Vomiting causes a significant loss of gastric $H^+$ from the body, which leads to **increased serum $HCO_3^-$** (metabolic alkalosis). There is also loss of water and salt (relatively more $Cl^-$ is lost than $Na^+$ due to high gastric quantity of HCl), leading to volume depletion that perpetuates the metabolic alkalosis and causes other electrolyte abnormalities.

Intravascular volume depletion decreases renal perfusion, resulting in activation of the **renin-angiotensin-aldosterone system**. Aldosterone stimulates $Na^+$ reabsorption and a lesser degree of passive $Cl^-$ reabsorption in the distal tubules of the kidneys in an effort to increase blood volume. The relatively greater loss of $Cl^-$ compared to $Na^+$ from both the stomach and kidneys leads to a large $Cl^-$ deficit and characteristic **hypochloremia**.

The aldosterone-mediated increase in $Na^+$ reabsorption comes at the expense of increased $K^+$ and $H^+$ excretion via the principal and alpha intercalated cells in the collecting duct. This leads to **hypokalemia** and exacerbation of the metabolic alkalosis. **Chloride depletion** then **perpetuates the metabolic alkalosis** because low tubular $Cl^-$ concentration impairs $HCO_3^-$ excretion via the pendrin pump on beta intercalated cells.

If the hypovolemia persists, it also provides nonosmotic stimulus for the secretion of antidiuretic hormone (ADH). The ADH secretion is considered appropriate because the body's priority is to restore itself to euvolemia; however, it leads to free water retention with **hyponatremia** and more profound hypochloremia.

**Educational objective:**
Severe vomiting characteristically causes hypokalemic, hypochloremic metabolic alkalosis. The metabolic alkalosis is initiated by loss of gastric $H^+$ from the body, worsened by hypovolemia-induced activation of the renin-angiotensin-aldosterone system, and perpetuated by profound gastric and renal losses of $Cl^-$ that lead to hypochloremia and impaired renal $HCO_3^-$ excretion. Hypokalemia primarily results from aldosterone-mediated renal $K^+$ losses.

**References**

- Physiology, metabolic alkalosis.

This patient has had **severe vomiting** (suggestive of hyperemesis gravidarum) and now has multiple signs of **volume depletion** (eg, dry mucous

## Exhibit Display

**Action of aldosterone in the collecting duct of the nephron**

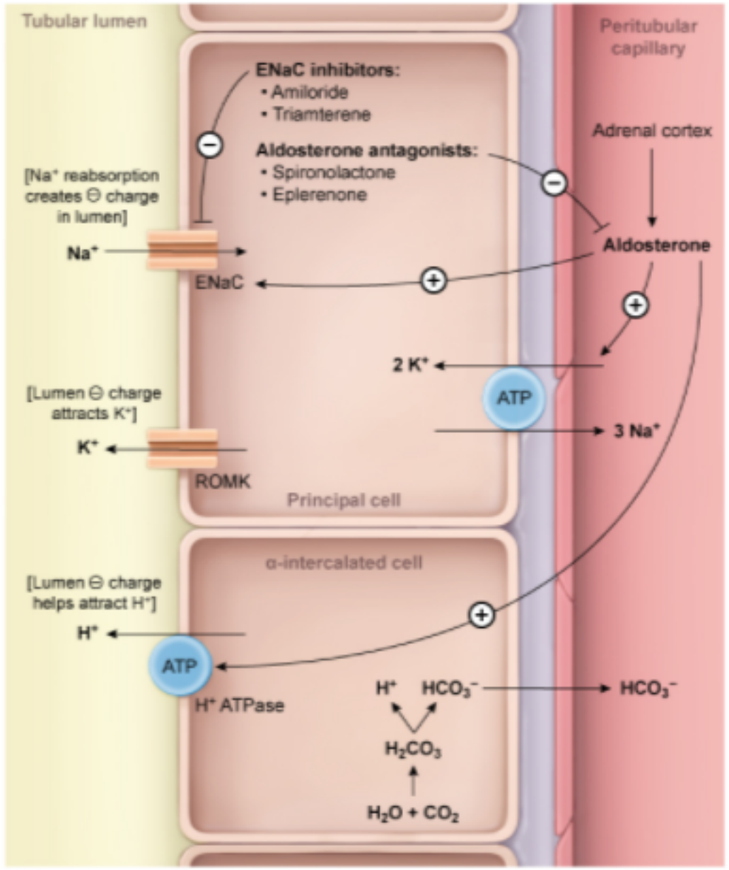


Zoom In | Zoom Out | Reset | Add To Flash Card

Subject System Topic

This patient has had **severe vomiting** (suggestive of hyperemesis gravidarum) and now has multiple signs of **volume depletion** (eg, dry mucous

Exhibit Display

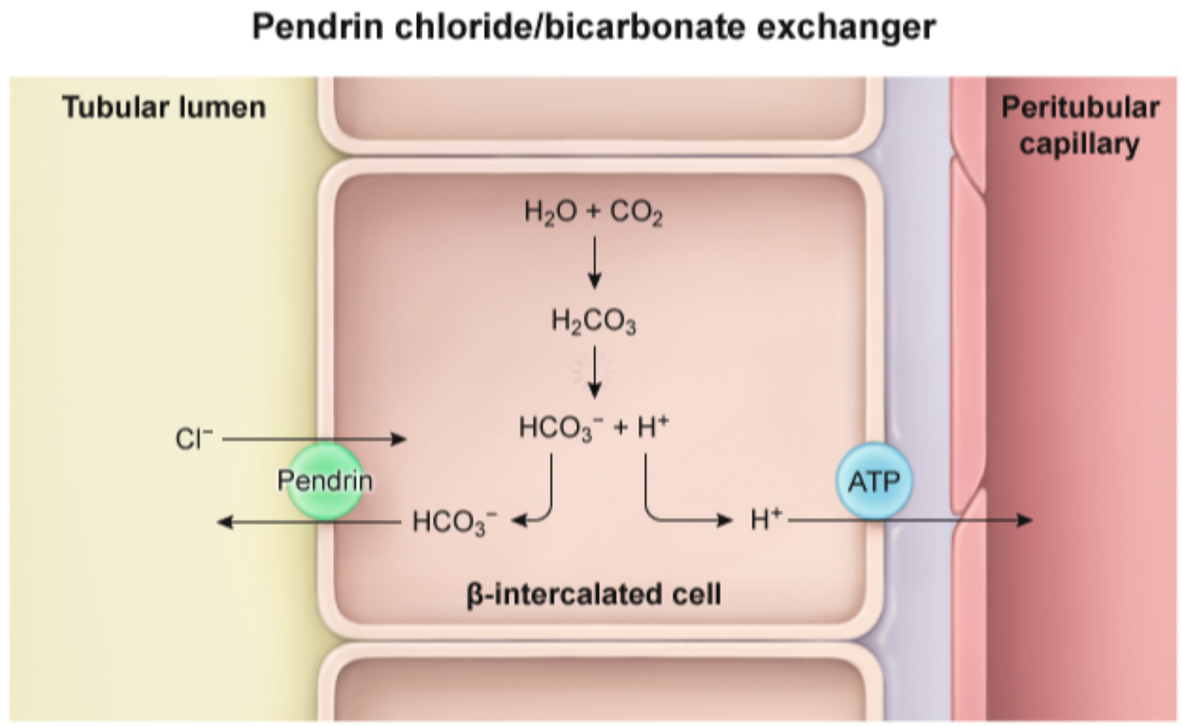


©UWorld

Zoom In Zoom Out Reset Add To Flash Card

Subject System Topic

Settings

1
2
3
4
5
6
7
8
9
10
11
12
13
14
15
16
17
18
19
20
21
22
23
24
25
26
27
28
29
30

Item 27 of 39
Question Id: 12

Mark | Previous | Next | Full Screen | Tutorial | Lab Values | Notes | Calculator | Reverse Color | Text Zoom | Settings

Exhibit Display

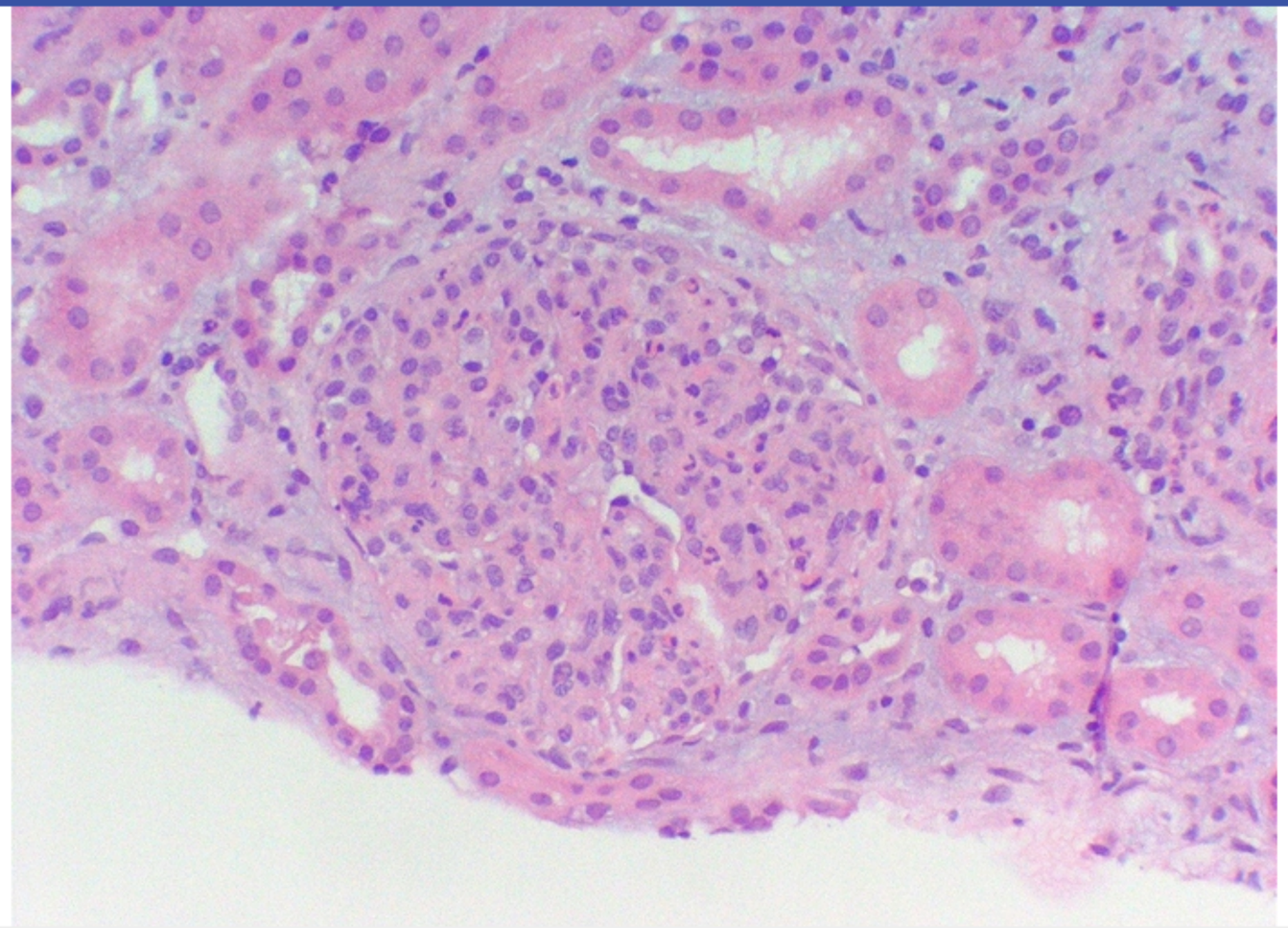

Zoom In | Zoom Out | Reset | Add To New Card | Existing Card

Block Time Remaining: 00:05:35
TUTOR

4 | Feedback | Suspend | End Block

A 12-year-old boy is brought to the clinic because of facial puffiness. Examination shows periorbital edema. Urinalysis reveals:

| | |
|---|---|
| Protein | 1+ |
| Blood | trace |
| White blood cells | 3-5/hpf |
| Red blood cells | 20-30/hpf |
| Casts | red blood cells |
| Crystals | none |

A biopsy image representative of this patient's disease process is shown below.

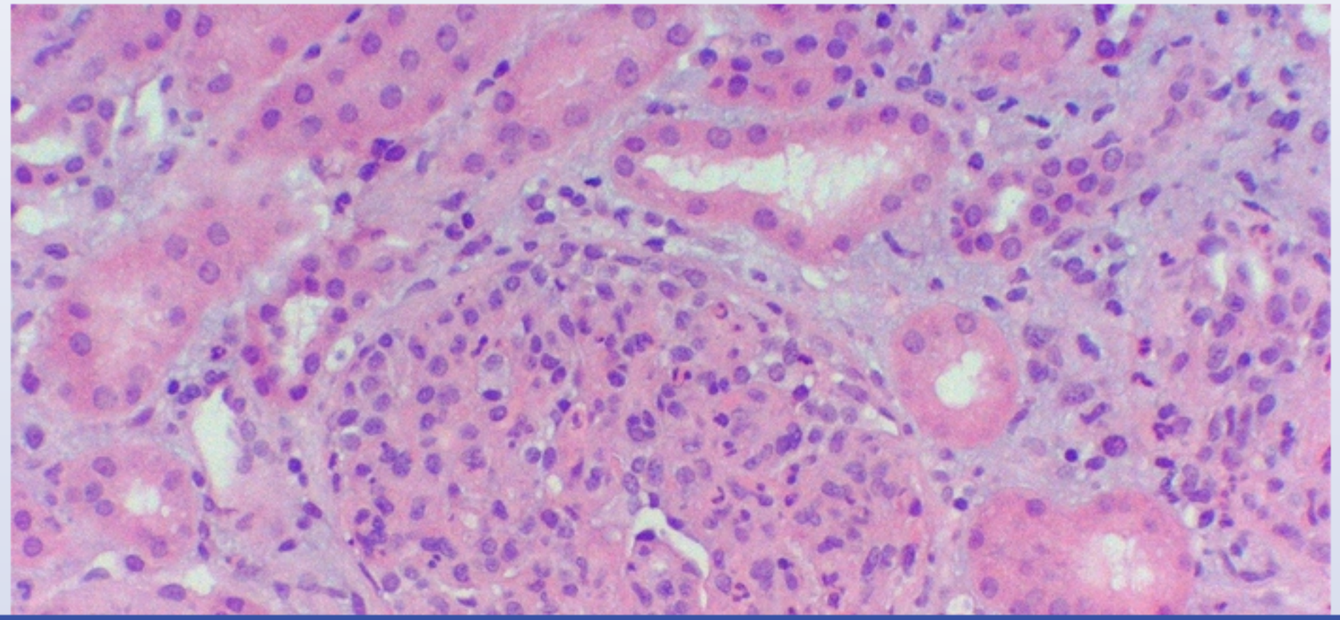

1 2 3 4 5 6 7 8 9 10 11 12 13 14 15 16 17 18 19 20 21 22 23 24 25 26 27 28 29 30

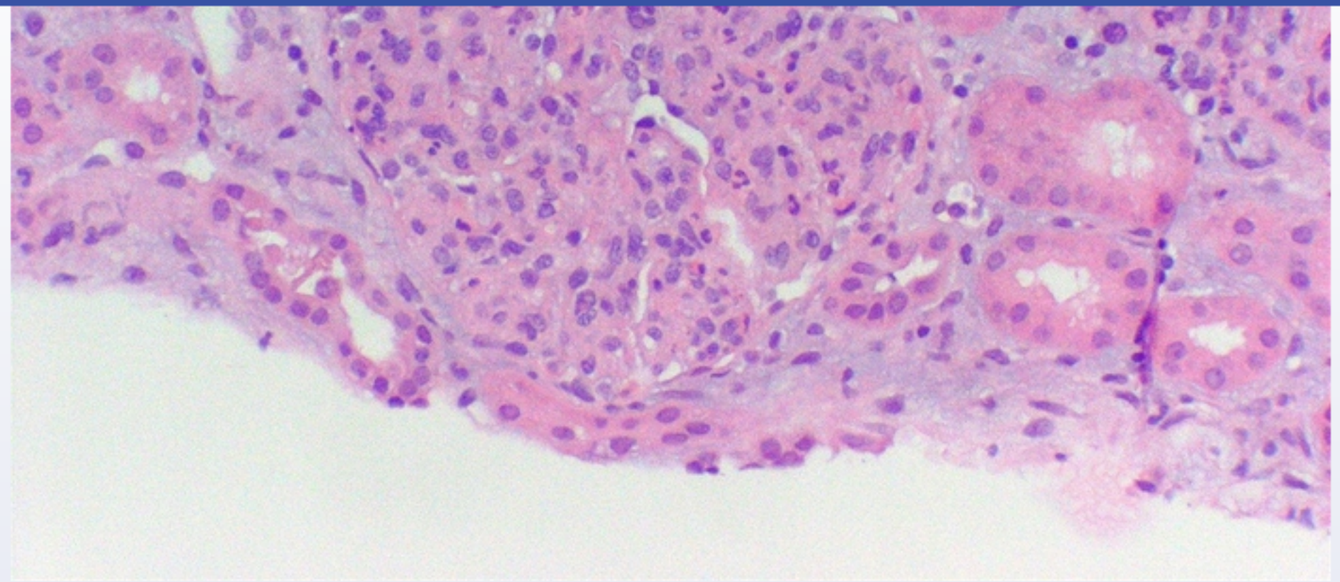

Which of the following additional findings is most likely to be present in this patient?

- A. Antiglomerular basement membrane antibodies
- B. Antineutrophil cytoplasmic antibodies
- C. Decreased serum C3 level
- D. Decreased serum C4 level
- E. Increased eosinophil count

Submit

1
2
3
4
5
6
7
8
9
10
11
12
13
14
15
16
17
18
19
20
21
22
23
24
25
26
27
28
29
30

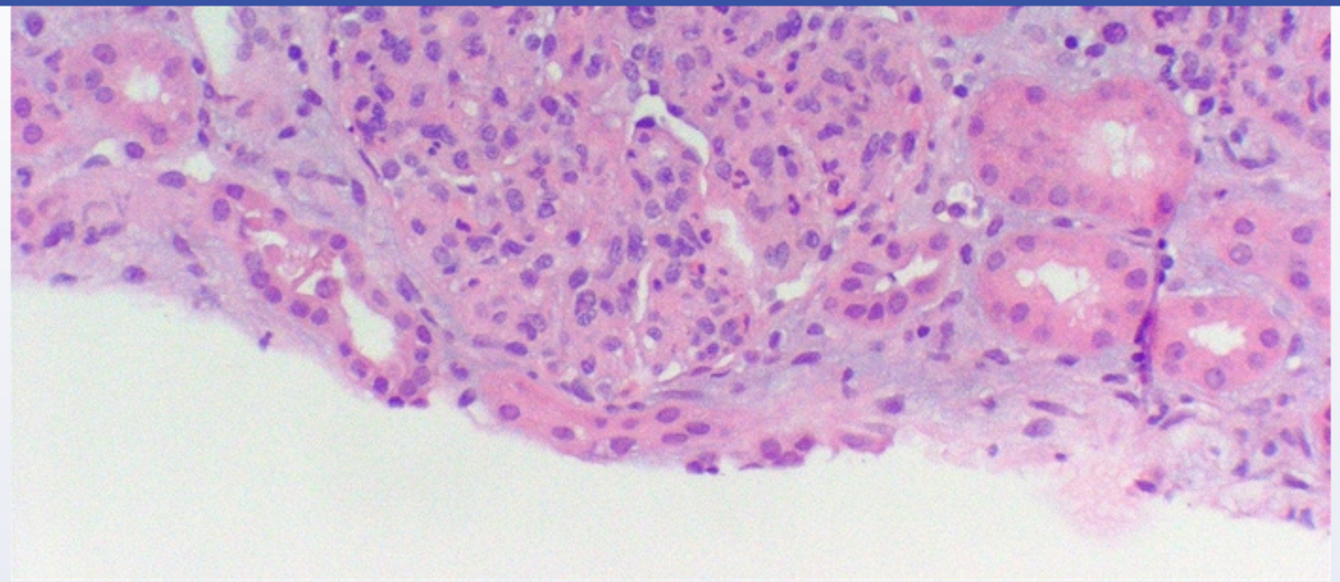

Which of the following additional findings is most likely to be present in this patient?

A. Antiglomerular basement membrane antibodies (8%)

B. Antineutrophil cytoplasmic antibodies (4%)

✓ C. Decreased serum C3 level (77%)

D. Decreased serum C4 level (3%)

E. Increased eosinophil count (5%)

Omitted
Correct answer

77%
Answered correctly

07 secs
Time Spent

03/22/2020
Last Updated

Explanation

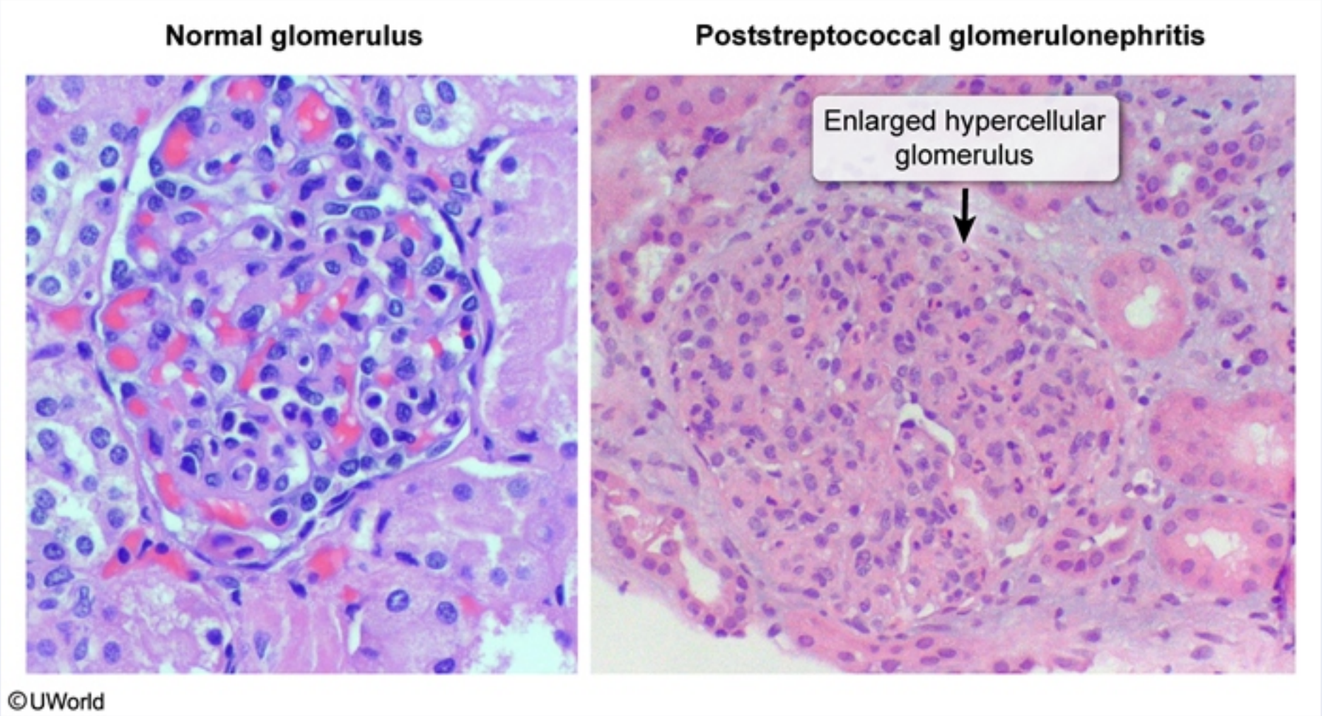


This pediatric patient with microscopic hematuria, red blood cell casts, mild pyuria, and proteinuria has a nephritic syndrome (glomerulonephritis). The biopsy sample demonstrates **enlarged, hypercellular glomeruli** consistent with **poststreptococcal glomerulonephritis** (PSGN), which is the most common cause of **nephritic syndrome** in children. PSGN is caused by immune complex deposition in the glomerulus following group A beta-hemolytic *Streptococcus* (eg, *Streptococcus pyogenes*) infection. Hypercellularity, which involves all lobules of all glomeruli, is the result of leukocyte infiltration and endothelial and mesangial cell proliferation in response to secreted cytokines.

Other classic findings include elevated titers of antistreptococcal antibodies (eg, antistreptolysin O, anti–DNase B) and **low C3 concentrations** (due to consumption). Electron microscopy typically shows electron-dense deposits composed of immune complexes on the epithelial side of the glomerular basement membrane. On immunofluorescent microscopy, there are coarse, granular deposits of IgG and C3 with a characteristic

©UWorld

This pediatric patient with microscopic hematuria, red blood cell casts, mild pyuria, and proteinuria has a nephritic syndrome (glomerulonephritis). The biopsy sample demonstrates **enlarged, hypercellular glomeruli** consistent with **poststreptococcal glomerulonephritis** (PSGN), which is the most common cause of **nephritic syndrome** in children. PSGN is caused by immune complex deposition in the glomerulus following group A beta-hemolytic *Streptococcus* (eg, *Streptococcus pyogenes*) infection. Hypercellularity, which involves all lobules of all glomeruli, is the result of leukocyte infiltration and endothelial and mesangial cell proliferation in response to secreted cytokines.

Other classic findings include elevated titers of antistreptococcal antibodies (eg, antistreptolysin O, anti–DNase B) and **low C3 concentrations** (due to consumption). Electron microscopy typically shows electron-dense deposits composed of immune complexes on the epithelial side of the glomerular basement membrane. On immunofluorescent microscopy, there are coarse, granular deposits of IgG and C3 with a characteristic "starry sky" appearance.

**(Choices A and B)** Serum antiglomerular basement membrane antibodies are found in Goodpasture syndrome. Serum antineutrophil cytoplasmic antibodies are associated with certain vasculitides (eg, granulomatosis with polyangiitis, microscopic polyangiitis). These conditions can cause both pulmonary-renal syndrome with hemoptysis and renal failure. However, the typical renal manifestation is rapidly progressive glomerulonephritis, which is characterized by crescent formation on light microscopy. In addition, these conditions are rare in children.

**(Choice D)** Although C3 levels are decreased in almost all patients with PSGN, C4 levels are usually normal as complement activation in PSGN occurs predominantly via the alternative pathway.

**(Choice E)** Eosinophilia can occur in acute interstitial nephritis, which causes renal failure but is typically associated with fever, rash, sterile pyuria, and white blood cell casts; significant hematuria and red blood cell casts are unexpected.

**Educational objective:**
Poststreptococcal glomerulonephritis is the most common cause of nephritic syndrome in children. Light microscopy demonstrates enlarged, hypercellular glomeruli. Laboratory findings in poststreptococcal glomerulonephritis include elevated antistreptococcal antibodies (eg, antistreptolysin O, anti–DNase B) and decreased C3 and total complement levels. C4 levels are usually normal.

Pathology | Renal, Urinary Systems & Electrolytes | Poststreptococcal Glomerulonephritis

©UWorld

This pediatric patient with ... s).
The biopsy sample demor ... is
the most common cause ... p A
beta-hemolytic *Streptococ* ... of
leukocyte infiltration and e

Other classic findings incl ...
(due to consumption). Ele ... the
glomerular basement mer
"starry sky" appearance.

**(Choices A and B)** Seru
cytoplasmic antibodies are ... ns
can cause both pulmonary
glomerulonephritis, which

**(Choice D)** Although C3 ... GN
occurs predominantly via

**(Choice E)** Eosinophilia
pyuria, and white blood ce

**Educational objective:**
Poststreptococcal glomeru
hypercellular glomeruli. L
antistreptolysin O, anti–DN

Pathology | Renal, Urinary Systems & Electrolytes | Poststreptococcal Glomerulonephritis

**Exhibit Display**

**Nephritic vs nephrotic syndrome**

| | Nephritic | Nephrotic |
|---|---|---|
| **Onset** | Abrupt | Insidious |
| **GFR** | Low | Normal or low |
| **Serum albumin** | Normal | Low |
| **Edema** | ± | ++ |
| **Hypertension** | ++ | ± |
| **Casts** | RBC casts | Fatty or none |
| **Proteinuria** | ± | ++ |
| **Hematuria** | ++ | ± |
| **Pyuria** | + | None |

GFR = glomerular filtration rate; RBC = red blood cell.
+ = present; ++ = significant.

Add To New Card | Existing Card

©UWorld

Exhibit Display

## Crescentic glomerulonephritis

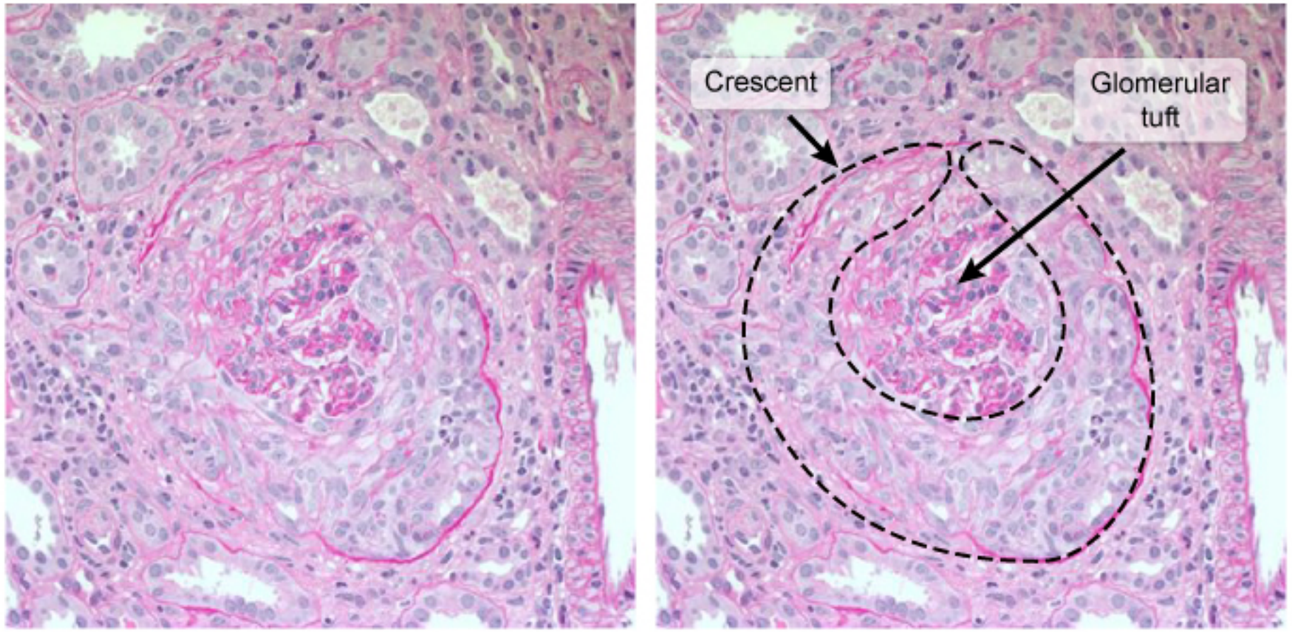


©UWorld

Zoom In | Zoom Out | Reset | Add To New Card | Existing Card

Pathology | Renal, Urinary Systems & Electrolytes | Poststreptococcal Glomerulonephritis

A 46-year-old previously healthy woman comes to the emergency department due to 4 days of intermittent fever, abdominal pain, and vomiting. For the past 2 days she has also had decreased urine output, skin rash, and progressive lethargy. Her temperature is 38.3 C (101 F), blood pressure is 130/80 mm Hg, and pulse is 100/min. There is a scattered petechial rash, facial puffiness, and 1+ bilateral pedal edema on physical examination. Laboratory studies show hemoglobin of 8.9 g/dL with elevated reticulocyte count and a platelet count of 26,000/mm$^3$. Bleeding time is prolonged; prothrombin time and activated partial thromboplastin time are normal. The peripheral blood smear shows schistocytes and reduced platelets with presence of giant forms. Blood urea nitrogen is 46 mg/dL and serum creatinine is 2.3 mg/dL. Urinalysis is positive for proteinuria and hematuria. Which of the following is most likely to be seen on renal biopsy?

- A. Collapse and sclerosis of glomerular tufts
- B. Crescent-shaped mass of cellular proliferation and leukocytes
- C. Diffuse proliferation and subepithelial immunoglobulin deposits
- D. Mesangial IgA deposition and proliferation
- E. Patchy necrosis of tubular epithelium and loss of basement membrane
- F. Platelet-rich thrombi in glomeruli and arterioles

Submit

A 46-year-old previously healthy woman comes to the emergency department due to 4 days of intermittent fever, abdominal pain, and vomiting. For the past 2 days she has also had decreased urine output, skin rash, and progressive lethargy. Her temperature is 38.3 C (101 F), blood pressure is 130/80 mm Hg, and pulse is 100/min. There is a scattered petechial rash, facial puffiness, and 1+ bilateral pedal edema on physical examination. Laboratory studies show hemoglobin of 8.9 g/dL with elevated reticulocyte count and a platelet count of 26,000/mm$^3$. Bleeding time is prolonged; prothrombin time and activated partial thromboplastin time are normal. The peripheral blood smear shows schistocytes and reduced platelets with presence of giant forms. Blood urea nitrogen is 46 mg/dL and serum creatinine is 2.3 mg/dL. Urinalysis is positive for proteinuria and hematuria. Which of the following is most likely to be seen on renal biopsy?

- A. Collapse and sclerosis of glomerular tufts (1%)
- B. Crescent-shaped mass of cellular proliferation and leukocytes (14%)
- C. Diffuse proliferation and subepithelial immunoglobulin deposits (12%)
- D. Mesangial IgA deposition and proliferation (10%)
- E. Patchy necrosis of tubular epithelium and loss of basement membrane (10%)
- ✓ F. Platelet-rich thrombi in glomeruli and arterioles (50%)

Omitted
Correct answer
F

50%
Answered correctly

03 secs
Time Spent

02/18/2020
Last Updated

Explanation

This patient has the **pentad** of fever, neurologic symptoms (progressive lethargy), renal failure, anemia, and thrombocytopenia in the setting of a

Explanation

This patient has the **pentad** of fever, neurologic symptoms (progressive lethargy), renal failure, anemia, and thrombocytopenia in the setting of a gastrointestinal illness. She most likely has **thrombocytopenic thrombotic purpura-hemolytic uremic syndrome** (TTP-HUS), one of the **thrombotic microangiopathy** (TMA) syndromes. These share common clinical and pathologic features, including:

- **Platelet activation** in arterioles and capillaries
- Diffuse **microvascular thrombosis** (most commonly affecting the brain, kidneys, and heart)
- Microangiopathic hemolytic anemia with schistocytes
- Thrombocytopenia

Unlike disseminated intravascular coagulation, in which coagulation cascade activation leads to prolongation of coagulation studies (prothrombin time [PT] and activated partial thromboplastin time [aPTT]), TTP is almost always characterized by **normal** PT and aPTT.

The pentad of symptoms described in this patient is classic for TTP.

**(Choice A)** Focal segmental glomerulosclerosis, including its collapsing variant, commonly manifests as heavy proteinuria.

**(Choice B)** Crescentic or rapidly progressive glomerulonephritis (RPGN) typically presents with macroscopic hematuria, hypertension, and progressive renal failure. It is classified as anti-glomerular basement membrane (with hemoptysis in Goodpasture syndrome), immune-complex mediated (eg, systemic lupus erythematous), or pauci-immune (with pulmonary, upper respiratory, and kidney involvement in granulomatosis with polyangiitis).

**(Choice C)** Poststreptococcal glomerulonephritis is typically a childhood disease that can follow streptococcal pharyngitis and lead to increased Coca-Cola-colored urine output and periorbital edema.

**(Choice D)** Henoch-Schönlein purpura is typically a childhood disease with nonthrombocytopenic palpable purpura and arthritis; IgA nephropathy commonly presents with recurrent hematuria and low-grade proteinuria following an upper respiratory tract infection. Both diseases have similar histopathologic findings with IgA deposition in the mesangium.

**(Choice E)** Acute tubular necrosis due to ischemia (eg, prolonged hypotension), nephrotoxins (eg, antibiotics), or pigment deposition (eg, myoglobinuria) generally presents with rising creatinine and muddy brown granular casts on urinalysis.

Unlike disseminated intravascular coagulation, in which coagulation cascade activation leads to prolongation of coagulation studies (prothrombin time [PT] and activated partial thromboplastin time [aPTT]), TTP is almost always characterized by **normal** PT and aPTT.

The pentad of symptoms described in this patient is classic for TTP.

**(Choice A)** Focal segmental glomerulosclerosis, including its collapsing variant, commonly manifests as heavy proteinuria.

**(Choice B)** Crescentic or rapidly progressive glomerulonephritis (RPGN) typically presents with macroscopic hematuria, hypertension, and progressive renal failure. It is classified as anti-glomerular basement membrane (with hemoptysis in Goodpasture syndrome), immune-complex mediated (eg, systemic lupus erythematous), or pauci-immune (with pulmonary, upper respiratory, and kidney involvement in granulomatosis with polyangiitis).

**(Choice C)** Poststreptococcal glomerulonephritis is typically a childhood disease that can follow streptococcal pharyngitis and lead to increased Coca-Cola-colored urine output and periorbital edema.

**(Choice D)** Henoch-Schönlein purpura is typically a childhood disease with nonthrombocytopenic palpable purpura and arthritis; IgA nephropathy commonly presents with recurrent hematuria and low-grade proteinuria following an upper respiratory tract infection. Both diseases have similar histopathologic findings with IgA deposition in the mesangium.

**(Choice E)** Acute tubular necrosis due to ischemia (eg, prolonged hypotension), nephrotoxins (eg, antibiotics), or pigment deposition (eg, myoglobinuria) generally presents with rising creatinine and muddy brown granular casts on urinalysis.

**Educational objective:**
Primary thrombotic microangiopathy (TMA) syndromes share common clinical and pathologic features and result in platelet activation and diffuse microthrombosis in arterioles and capillaries. TMA syndromes present with hemolytic anemia with schistocytes, thrombocytopenia, and organ injury (eg, brain, kidneys, heart).

**References**


- Thrombotic microangiopathy and associated renal disorders.
- Pathogenesis of thrombotic microangiopathies.

Settings

1
2
3
4
5
6
7
8
9
10
11
12
13
14
15
16
17
18
19
20
21
22
23
24
25
26
27
28
29
30

Item 28 of 39
Question Id: 11608

Mark | Previous | Next | Full Screen | Tutorial | Lab Values | Notes | Calculator | Reverse Color | Text Zoom | Settings

Exhibit Display

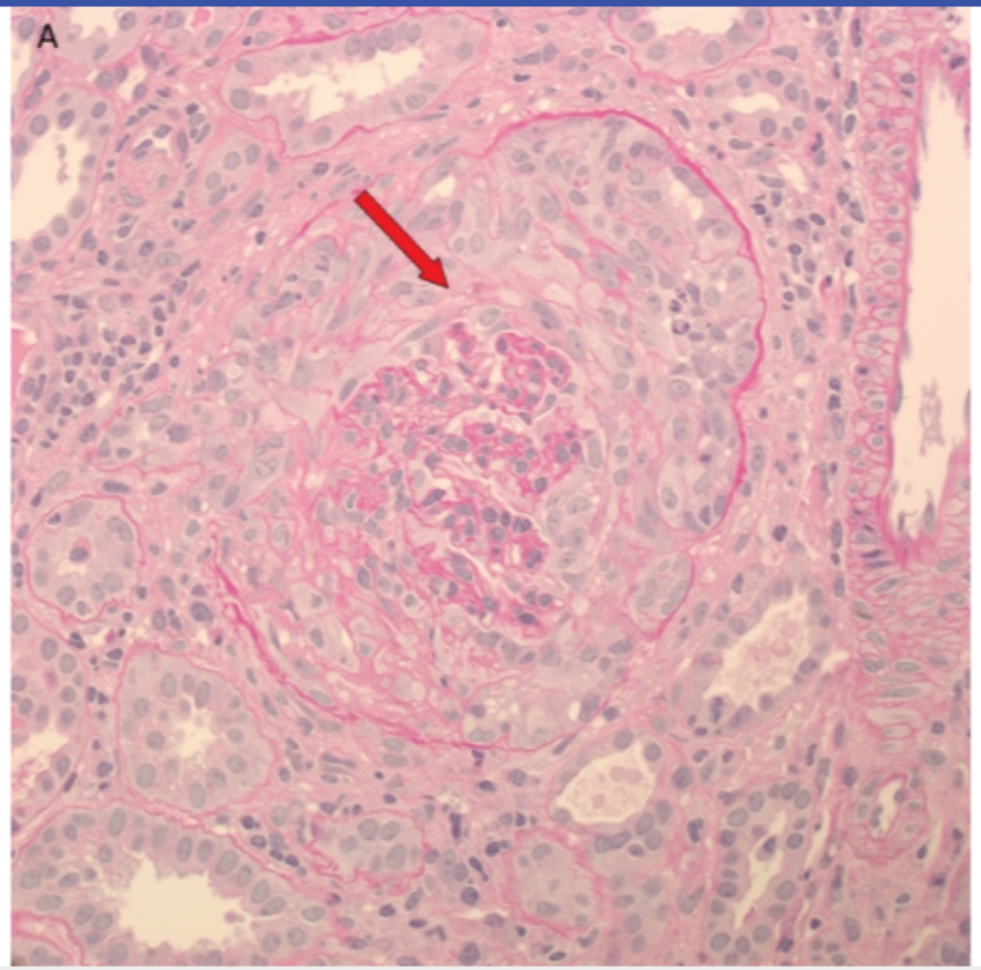


Zoom In | Zoom Out | Reset | Add To New Card | Existing Card

Block Time Remaining: 00:05:44
TUTOR

4 | Feedback | Suspend | End Block

1
2
3
4
5
6
7
8
9
10
11
12
13
14
15
16
17
18
19
20
21
22
23
24
25
26
27
28
29
30

Exhibit Display

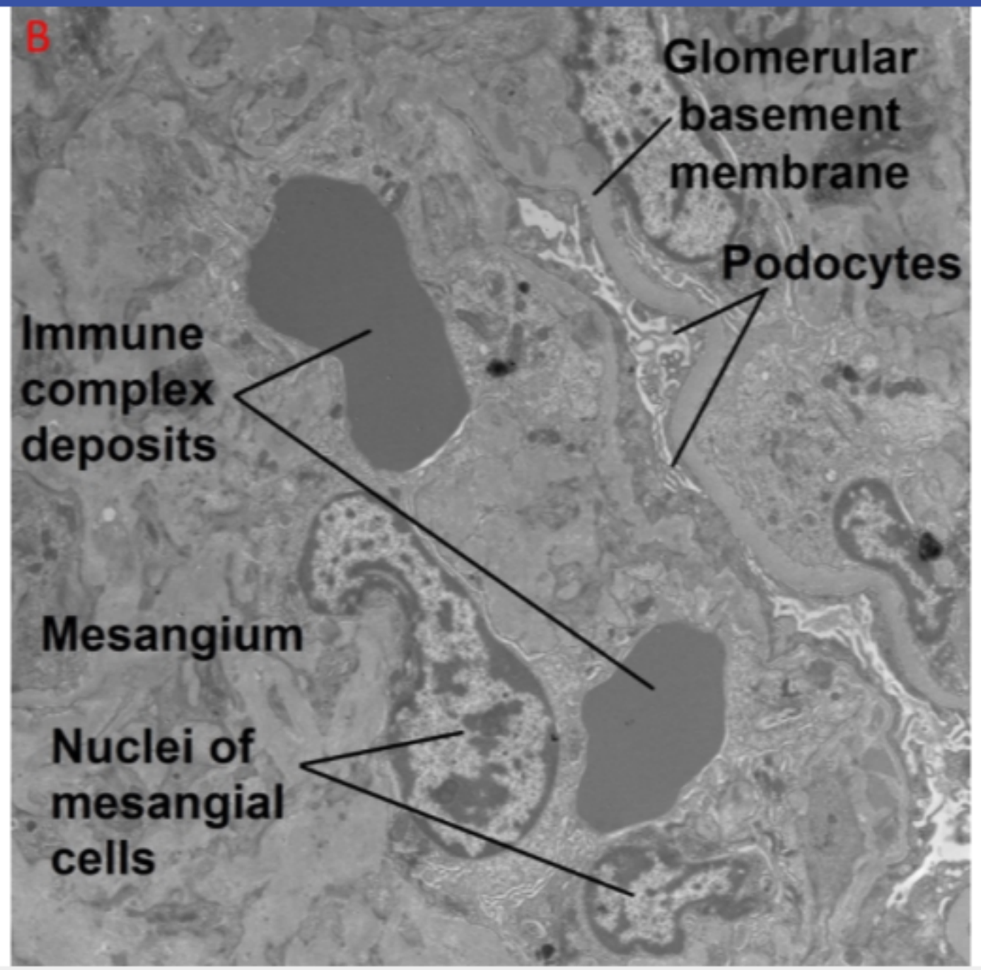


Zoom In | Zoom Out | Reset | Add To New Card | Existing Card

Settings

1 2 3 4 5 6 7 8 9 10 11 12 13 14 15 16 17 18 19 20 21 22 23 24 25 26 27 28 29 30

Item 28 of 39
Question Id: 11608

Mark | Previous | Next | Full Screen | Tutorial | Lab Values | Notes | Calculator | Reverse Color | Text Zoom | Settings

Exhibit Display

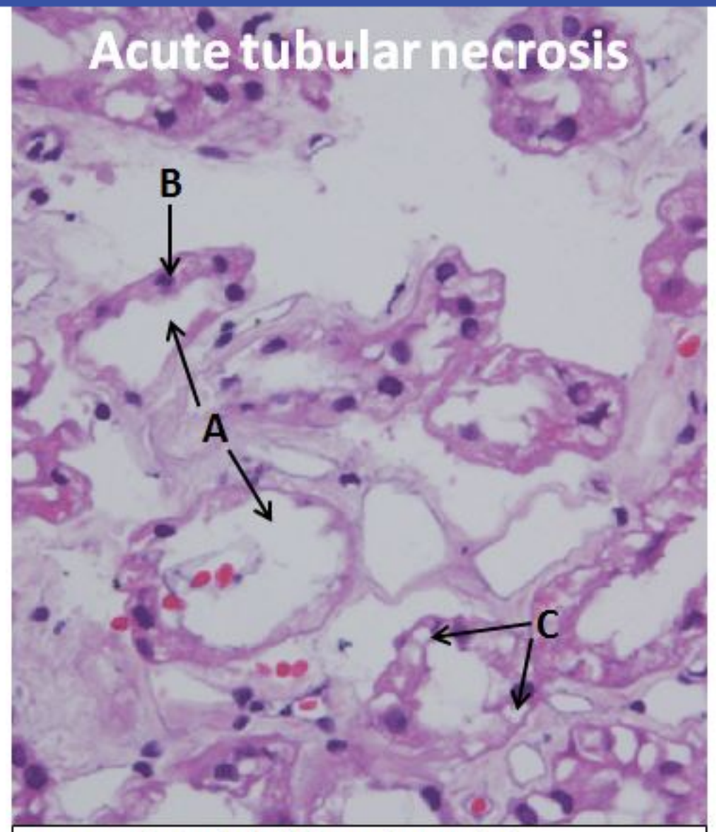


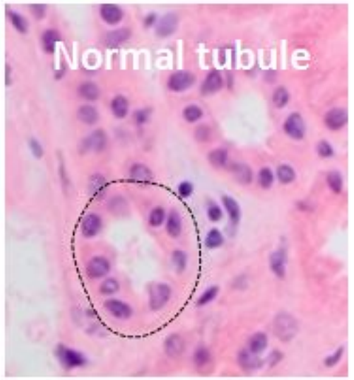


**Outer medulla of the kidney (H&E stain)**
(a) Patchy loss of proximal tubular epithelial cells with tubular dilation; (b) regenerating epithelial cells with hyperchromatic nuclei; (c) epithelial cell vacuolization.

Zoom In | Zoom Out | Reset | Add To New Card | Existing Card

Block Time Remaining: 00:05:44
TUTOR

4 | Feedback | Suspend | End Block

1 2 3 4 5 6 7 8 9 10 11 12 13 14 15 16 17 18 19 20 21 22 23 24 25 26 27 28 29 30

A 28-year-old man is hospitalized following a motor vehicle collision complicated by severe hemorrhage. Over the next 8 hours his urine output is markedly decreased. Laboratory results reveal elevated blood urea nitrogen. The patient is given aggressive intravenous fluid hydration. After 24 hours of therapy, urine output is increased and blood urea nitrogen declines toward normal. Which of the following additional laboratory abnormalities suggests that this patient's initial oliguria is a compensation for volume contraction?

A. Muddy brown casts on urinalysis

B. Serum BUN/creatinine ratio <15

C. Urine fractional excretion of sodium >2%

D. Urine osmolarity <350 mOsm/kg

E. Urine sodium <20 mEq/L

Submit

A 28-year-old man is hospitalized following a motor vehicle collision complicated by severe hemorrhage. Over the next 8 hours his urine output is markedly decreased. Laboratory results reveal elevated blood urea nitrogen. The patient is given aggressive intravenous fluid hydration. After 24 hours of therapy, urine output is increased and blood urea nitrogen declines toward normal. Which of the following additional laboratory abnormalities suggests that this patient's initial oliguria is a compensation for volume contraction?

- A. Muddy brown casts on urinalysis (8%)
- B. Serum BUN/creatinine ratio <15 (9%)
- C. Urine fractional excretion of sodium >2% (12%)
- D. Urine osmolarity <350 mOsm/kg (7%)
- ✓ E. Urine sodium <20 mEq/L (62%)

Omitted
Correct answer
E

62%
Answered correctly

02 secs
Time Spent

01/26/2020
Last Updated

Explanation

**Acute kidney injury**

| | Prerenal | Acute tubular necrosis |
|---|---|---|
| **Mechanism** | Decreased renal perfusion (eg, hypovolemia, CHF) | Renal ischemia (eg, hemorrhage, sepsis) or nephrotoxins (eg, aminoglycosides, radiocontrast) |

**Acute kidney injury**

| | Prerenal | Acute tubular necrosis |
|---|---|---|
| **Mechanism** | Decreased renal perfusion (eg, hypovolemia, CHF) | Renal ischemia (eg, hemorrhage, sepsis) or nephrotoxins (eg, aminoglycosides, radiocontrast) |
| **Findings** | | |
| BUN/creatine ratio | Typically >20 | Typically ~10-15 |
| Fractional excretion of sodium | <1% | >2% |
| Urine osmolality | >500 mOsm/kg | ~300 mOsm/kg |
| Microscopy | Hyaline cast | Muddy brown casts |

**BUN** = blood urea nitrogen; **CHF** = congestive heart failure. ©UWorld

This patient developed symptoms of acute renal failure (ARF) (eg, low urine output, high blood urea nitrogen) after a massive hemorrhage. ARF can be classified according to 1 of 3 etiologies:

- **Prerenal:** Caused by **decreased renal perfusion**; the nephrons remain intact and tubular function is preserved. Etiologies include volume loss (eg, hemorrhage), low-output states (eg, myocardial infarction, congestive heart failure), or systemic vasodilation (eg, sepsis).
- **Intrinsic:** Caused by **tubular epithelial or glomerular damage**; resorptive capacity is lost. Etiologies include acute tubular necrosis (due to renal ischemia or nephrotoxins) or glomerular diseases (eg, glomerulonephritis, nephrotic syndrome).
- **Postrenal:** Caused by **urinary tract obstruction** with normal nephron capacity. Etiologies include bilateral calculi, enlarged prostate, or a renal tumor in an individual with a sole functional kidney.

This patient with severe blood loss was at risk for prerenal and intrinsic renal failure; however, his rapid **improvement with hydration** suggests a prerenal (hypovolemic) etiology. His laboratory results reflect intact renal tubular function, with compensatory mechanisms to restore blood volume. Increased tubular sodium reabsorption results in **low urine sodium (<20 mEq/L)** and **low fractional excretion of sodium** (FENa), whereas increased water reabsorption leads to **high urine osmolarity**. Urea reabsorption also increases to help concentrate the urine, resulting

to renal ischemia or nephrotoxins) or glomerular diseases (eg, glomerulonephritis, nephrotic syndrome).

- **Postrenal:** Caused by **urinary tract obstruction** with normal nephron capacity. Etiologies include bilateral calculi, enlarged prostate, or a renal tumor in an individual with a sole functional kidney.

This patient with severe blood loss was at risk for prerenal and intrinsic renal failure; however, his rapid **improvement with hydration** suggests a prerenal (hypovolemic) etiology. His laboratory results reflect intact renal tubular function, with compensatory mechanisms to restore blood volume. Increased tubular sodium reabsorption results in **low urine sodium (<20 mEq/L)** and **low fractional excretion of sodium** (FENa), whereas increased water reabsorption leads to **high urine osmolarity**. Urea reabsorption also increases to help concentrate the urine, resulting in increased serum levels of urea; creatinine continues to be excreted, resulting in the characteristic **BUN/creatinine ratio >20**.

In contrast, intrinsic ARF reflects tubular epithelium damage and loss of renal reabsorptive capacity. Water, sodium, and urea are excreted in the urine, leading to lower urine osmolarity, higher urinary sodium, higher urinary FENa, and a normal serum BUN/creatinine ratio.

**(Choice A)** Dark, granular, "muddy brown" casts seen on urinalysis are composed of degenerating tubular epithelial cells. This finding is associated with acute tubular necrosis, which is a common cause of intrinsic ARF.

**(Choices B, C, and D)** A serum BUN/creatinine ratio <15, urine FENa >2%, and urine osmolarity <350 mOsm/kg are characteristic of intrinsic ARF. These alterations in the laboratory indices of renal function represent the diminished ability of tubular epithelial cells to reabsorb urea, sodium, and water, respectively.

**Educational objective:**
Blood volume loss can cause prerenal or intrinsic acute renal failure (ARF). Prerenal ARF is associated with normal nephron function (eg, low urine sodium level, low fractionated sodium excretion, high urine osmolarity, and a high BUN/creatinine ratio), whereas intrinsic ARF features diminished renal reabsorptive capacity (eg, lower urine osmolarity, higher urinary sodium, normal serum BUN/creatinine ratio).

| Pathology | Renal, Urinary Systems & Electrolytes | Prerenal azotemia |
|---|---|---|
| Subject | System | Topic |

Copyright © UWorld. All rights reserved.

A 5-year-old girl is brought to the clinic due to 2 days of dark red urine. The patient was treated for facial impetigo 1 month ago. Blood pressure is 140/90 mm Hg. Urinalysis reveals hematuria, mild proteinuria, and occasional red blood cell casts. Which of the following changes would most likely be present on this patient's renal biopsy?

- A. Diffuse capillary wall thickening on light microscopy
- B. Discrete subepithelial humps on electron microscopy
- C. Glomerular basement membrane fibrin deposition on electron microscopy
- D. Glomerular basement membrane splitting on light microscopy
- E. Linear IgG and C3 deposits on immunofluorescent microscopy

Submit

A 5-year-old girl is brought to the clinic due to 2 days of dark red urine. The patient was treated for facial impetigo 1 month ago. Blood pressure is 140/90 mm Hg. Urinalysis reveals hematuria, mild proteinuria, and occasional red blood cell casts. Which of the following changes would most likely be present on this patient's renal biopsy?

- A. Diffuse capillary wall thickening on light microscopy (2%)
- ✓ B. Discrete subepithelial humps on electron microscopy (72%)
- C. Glomerular basement membrane fibrin deposition on electron microscopy (4%)
- D. Glomerular basement membrane splitting on light microscopy (2%)
- E. Linear IgG and C3 deposits on immunofluorescent microscopy (17%)

Omitted
Correct answer
B

72%
Answered correctly

01 sec
Time Spent

03/22/2020
Last Updated

Explanation

| Pathological findings in nephritic syndromes | | |
|---|---|---|
| | **Cause of glomerular injury** | **Characteristic biopsy features** |
| **Poststreptococcal** | Antibodies against streptococcal antigens that deposit in GBM | IF - C3 granular staining along GBM |

**Pathological findings in nephritic syndromes**

| | Cause of glomerular injury | Characteristic biopsy features |
|---|---|---|
| **Poststreptococcal glomerulonephritis** | Antibodies against streptococcal antigens that deposit in GBM | IF - C3 granular staining along GBM<br>EM - **Subepithelial humps** |
| **Anti-GBM disease** | Antibodies against type IV collagen in GBM | LM - Glomerular crescents<br>IF - **Linear staining (IgG)** along GBM |
| **Rapidly progressive glomerulonephritis** | **Severe** immunologic injury (eg, anti-GBM antibodies, immune complex deposition) | LM - Glomerular **crescents**<br>IF - Fibrin in crescents |
| **IgA nephropathy** | Deposition of IgA-containing complexes | LM - Mesangial hypercellularity<br>IF - **IgA in mesangium** |
| **Alport syndrome** | Defective type IV collagen in GBM | EM - **Lamellated appearance of GBM** |

**EM** = electron microscopy; **GBM** = glomerular basement membrane; **IF** = immunofluorescence; **LM** = light microscopy.

This patient has **nephritic syndrome**, characterized by hypertension, mild proteinuria, and hematuria with red blood cell casts in the urine sediment. In association with a recent skin infection, this presentation suggests **poststreptococcal glomerulonephritis** (PSGN), the most common cause of nephritic syndrome in children. PSGN is an **immune complex–mediated** disease that occurs 2-4 weeks after exposure to group A beta-hemolytic *Streptococcus* (eg, pharyngitis, skin infection). Antigens expressed on nephritogenic streptococcal species combine with antibodies to form immune complexes, which are later deposited on the glomerular basement membrane (GBM).

On light microscopy, all glomeruli are enlarged and hypercellular due to leukocyte infiltration and proliferation of endothelial and mesangial cells.

| | | |
|---|---|---|
| | | of GBM |

EM = electron microscopy; GBM = glomerular basement membrane; IF = immunofluorescence; LM = light microscopy.

This patient has **nephritic syndrome**, characterized by hypertension, mild proteinuria, and hematuria with red blood cell casts in the urine sediment. In association with a recent skin infection, this presentation suggests **poststreptococcal glomerulonephritis** (PSGN), the most common cause of nephritic syndrome in children. PSGN is an **immune complex–mediated** disease that occurs 2-4 weeks after exposure to group A beta-hemolytic *Streptococcus* (eg, pharyngitis, skin infection). Antigens expressed on nephritogenic streptococcal species combine with antibodies to form immune complexes, which are later deposited on the glomerular basement membrane (GBM).

On light microscopy, all glomeruli are enlarged and hypercellular due to leukocyte infiltration and proliferation of endothelial and mesangial cells. On electron microscopy, **electron-dense deposits** ("humps") on the epithelial side of the GBM are seen. Immunofluorescence reveals coarse, **granular deposits of IgG and C3** that have a characteristic "lumpy-bumpy" appearance.

**(Choice A)** Uniform, diffuse thickening of glomerular capillary walls on light microscopy is characteristic of membranous glomerulopathy, one of the most common causes of nephrotic syndrome in adults. Manifestations of nephrotic syndrome include generalized edema, marked proteinuria (>3.5 g/day), hypoalbuminemia, hyperlipidemia, and lipiduria.

**(Choices C and E)** In contrast to PSGN, which demonstrates granular deposits of IgG and C3 along the GBM, linear IgG and C3 deposits on immunofluorescence microscopy are characteristic of Goodpasture syndrome (anti-GBM disease). This commonly presents with rapidly progressive (crescentic) glomerulonephritis. Damage to the GBM results in leakage of plasma proteins and heavy fibrin deposition in the glomerulus, resulting in parietal cell proliferation and crescent formation. This disease is uncommon in children, and renal involvement is often accompanied by pulmonary symptoms (eg, hemoptysis).

**(Choice D)** GBM splitting is seen in membranoproliferative glomerulonephritis (MPGN) and Alport syndrome. Alport syndrome causes nephritic syndrome but is most commonly X-linked and therefore more common in males; it is not associated with recent streptococcal infections. MPGN causes nephrotic syndrome.

**Educational objective:**
Poststreptococcal glomerulonephritis is an immune complex–deposition disease that occurs 2-4 weeks after exposure to group A beta-hemolytic *Streptococcus* species (eg, pharyngitis, skin infection). Light microscopy shows enlarged, hypercellular glomeruli. Immunofluorescence

On light microscopy, all glomeruli are enlarged and hypercellular due to leukocyte infiltration and proliferation of endothelial and mesangial cells. On electron microscopy, **electron-dense deposits** ("humps") on the epithelial side of the GBM are seen. Immunofluorescence reveals coarse, **granular deposits of IgG and C3** that have a characteristic "lumpy-bumpy" appearance.

**(Choice A)** Uniform, diffuse thickening of glomerular capillary walls on light microscopy is characteristic of membranous glomerulopathy, one of the most common causes of nephrotic syndrome in adults. Manifestations of nephrotic syndrome include generalized edema, marked proteinuria (>3.5 g/day), hypoalbuminemia, hyperlipidemia, and lipiduria.

**(Choices C and E)** In contrast to PSGN, which demonstrates granular deposits of IgG and C3 along the GBM, linear IgG and C3 deposits on immunofluorescence microscopy are characteristic of Goodpasture syndrome (anti-GBM disease). This commonly presents with rapidly progressive (crescentic) glomerulonephritis. Damage to the GBM results in leakage of plasma proteins and heavy fibrin deposition in the glomerulus, resulting in parietal cell proliferation and crescent formation. This disease is uncommon in children, and renal involvement is often accompanied by pulmonary symptoms (eg, hemoptysis).

**(Choice D)** GBM splitting is seen in membranoproliferative glomerulonephritis (MPGN) and Alport syndrome. Alport syndrome causes nephritic syndrome but is most commonly X-linked and therefore more common in males; it is not associated with recent streptococcal infections. MPGN causes nephrotic syndrome.

**Educational objective:**
Poststreptococcal glomerulonephritis is an immune complex–deposition disease that occurs 2-4 weeks after exposure to group A beta-hemolytic *Streptococcus* species (eg, pharyngitis, skin infection). Light microscopy shows enlarged, hypercellular glomeruli. Immunofluorescence demonstrates a "lumpy-bumpy" granular deposits of IgG and C3 on the glomerular basement membrane, and subepithelial, electron-dense deposits are seen on electron microscopy.

| Pathology | Renal, Urinary Systems & Electrolytes | Poststreptococcal Glomerulonephritis |
|---|---|---|
| Subject | System | Topic |

Copyright © UWorld. All rights reserved.

Settings

1
2
3
4
5
6
7
8
9
10
11
12
13
14
15
16
17
18
19
20
21
22
23
24
25
26
27
28
29
30

Item 30 of 39
Question Id: 11

Mark | Previous | Next | Full Screen | Tutorial | Lab Values | Notes | Calculator | Reverse Color | Text Zoom | Settings

Exhibit Display

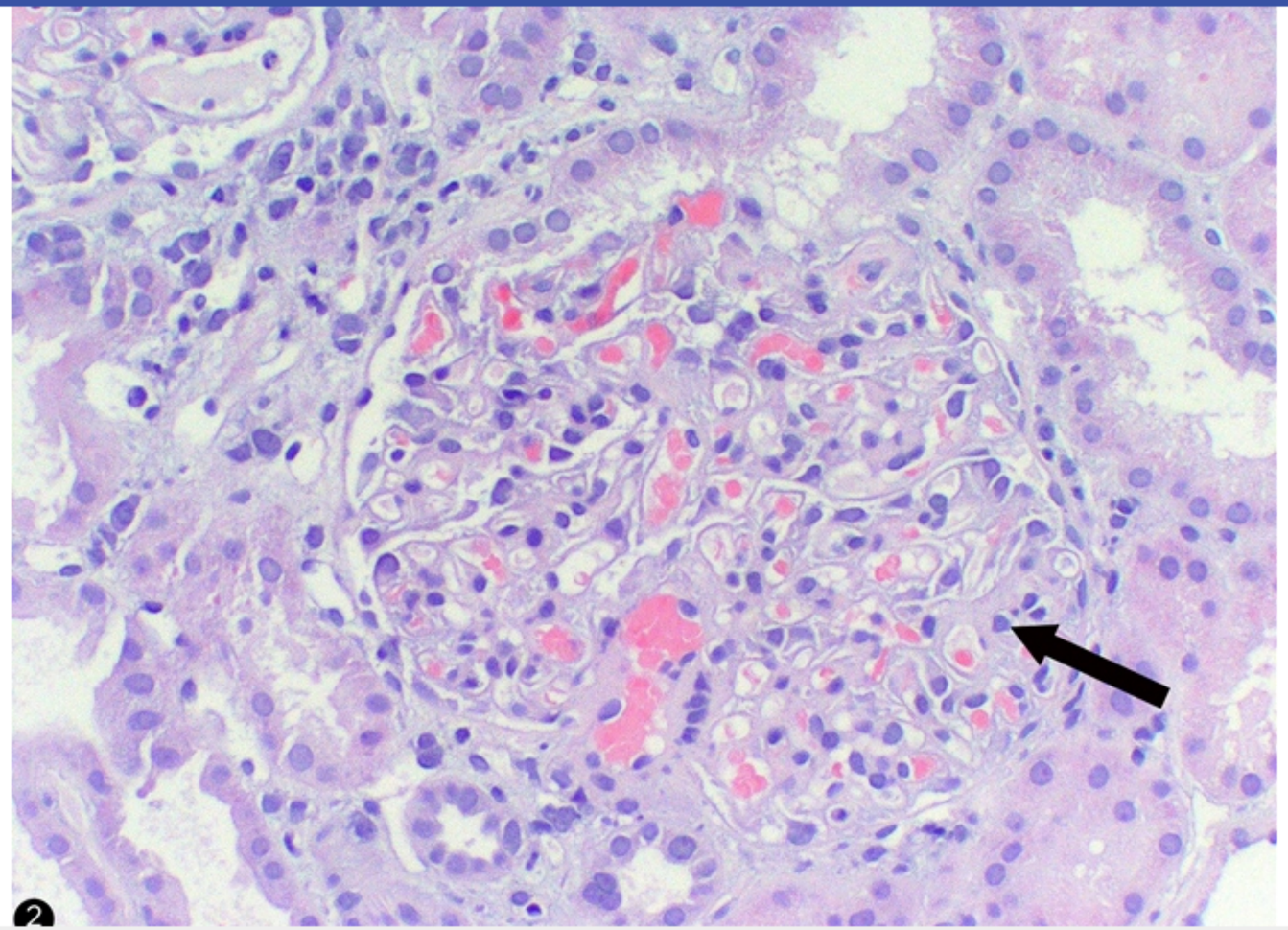

Zoom In | Zoom Out | Reset | Add To New Card | Existing Card

Block Time Remaining: 00:05:47
TUTOR

4 | Feedback | Suspend | End Block

Settings

1
2
3
4
5
6
7
8
9
10
11
12
13
14
15
16
17
18
19
20
21
22
23
24
25
26
27
28
29
30

Item 30 of 39
Question Id: 11

Mark | Previous | Next | Full Screen | Tutorial | Lab Values | Notes | Calculator | Reverse Color | Text Zoom | Settings

Exhibit Display

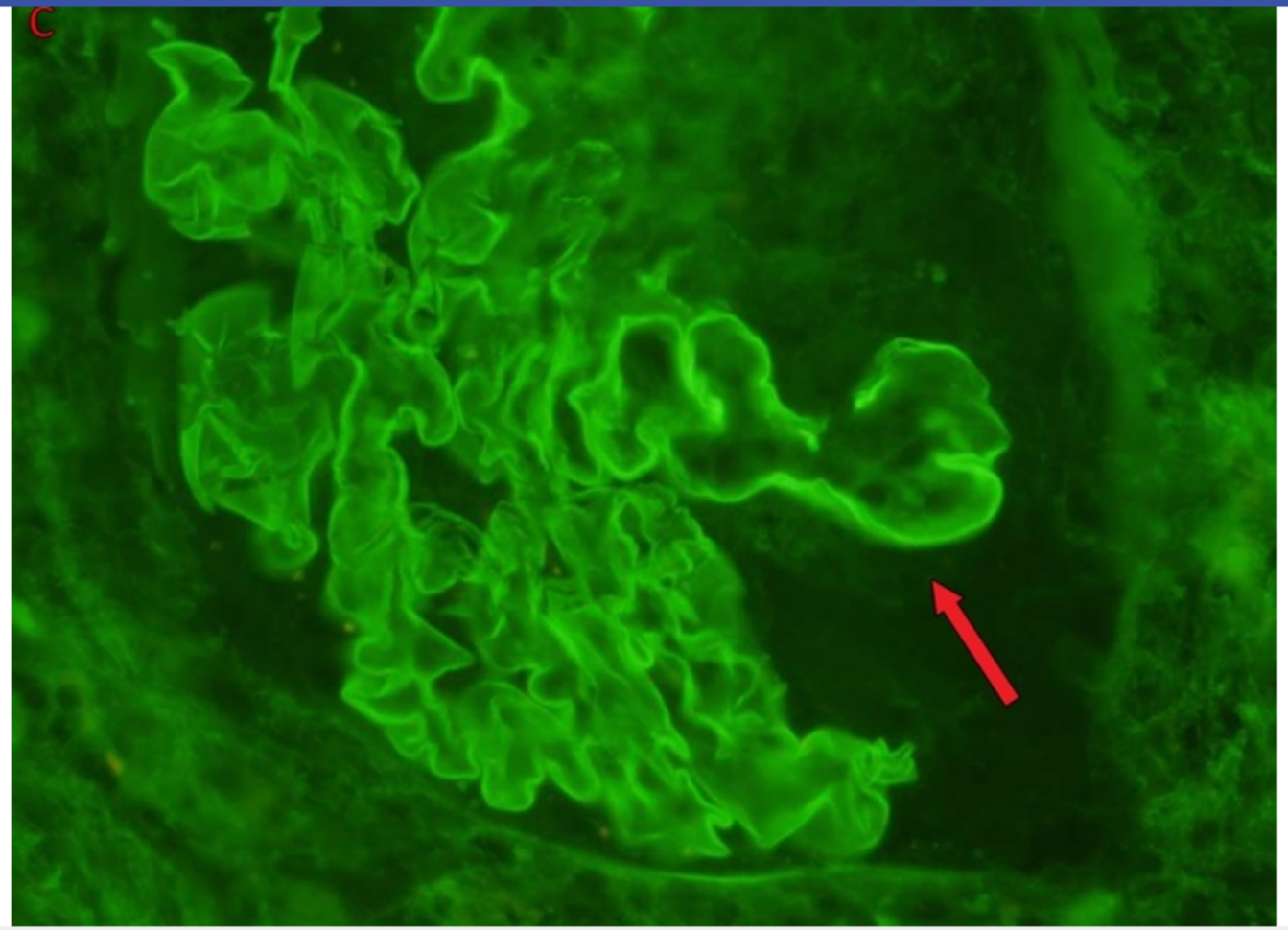

Zoom In | Zoom Out | Reset | Add To New Card | Existing Card

Block Time Remaining: 00:05:47
TUTOR

4 | Feedback | Suspend | End Block

A 7-year-old boy is brought to the office by his mother due to facial puffiness that is especially noticeable in the morning. He has a history of mild, intermittent asthma that is well controlled with albuterol as needed. Temperature is 36.1 C (97 F), blood pressure is 98/62 mm Hg, and pulse is 89/min and regular. Physical examination shows bilateral lower extremity pitting edema. Nephrotic-range proteinuria consisting mainly of albumin is revealed on urinalysis. Which of the following mechanisms is the most likely cause of this patient's abnormal laboratory findings?

A. Impaired tubular reabsorption of filtered proteins

B. Increased filtration of plasma proteins

C. Inflammation of the urinary tract

D. Necrosis of skeletal muscle fibers

E. Overproduction of low-molecular-weight proteins

Submit

A 7-year-old boy is brought to the office by his mother due to facial puffiness that is especially noticeable in the morning. He has a history of mild, intermittent asthma that is well controlled with albuterol as needed. Temperature is 36.1 C (97 F), blood pressure is 98/62 mm Hg, and pulse is 89/min and regular. Physical examination shows bilateral lower extremity pitting edema. Nephrotic-range proteinuria consisting mainly of albumin is revealed on urinalysis. Which of the following mechanisms is the most likely cause of this patient's abnormal laboratory findings?

A. Impaired tubular reabsorption of filtered proteins (12%)

✓ B. Increased filtration of plasma proteins (82%)

C. Inflammation of the urinary tract (1%)

D. Necrosis of skeletal muscle fibers (0%)

E. Overproduction of low-molecular-weight proteins (2%)

Omitted
Correct answer
B

82%
Answered correctly

02 secs
Time Spent

04/03/2020
Last Updated

Explanation

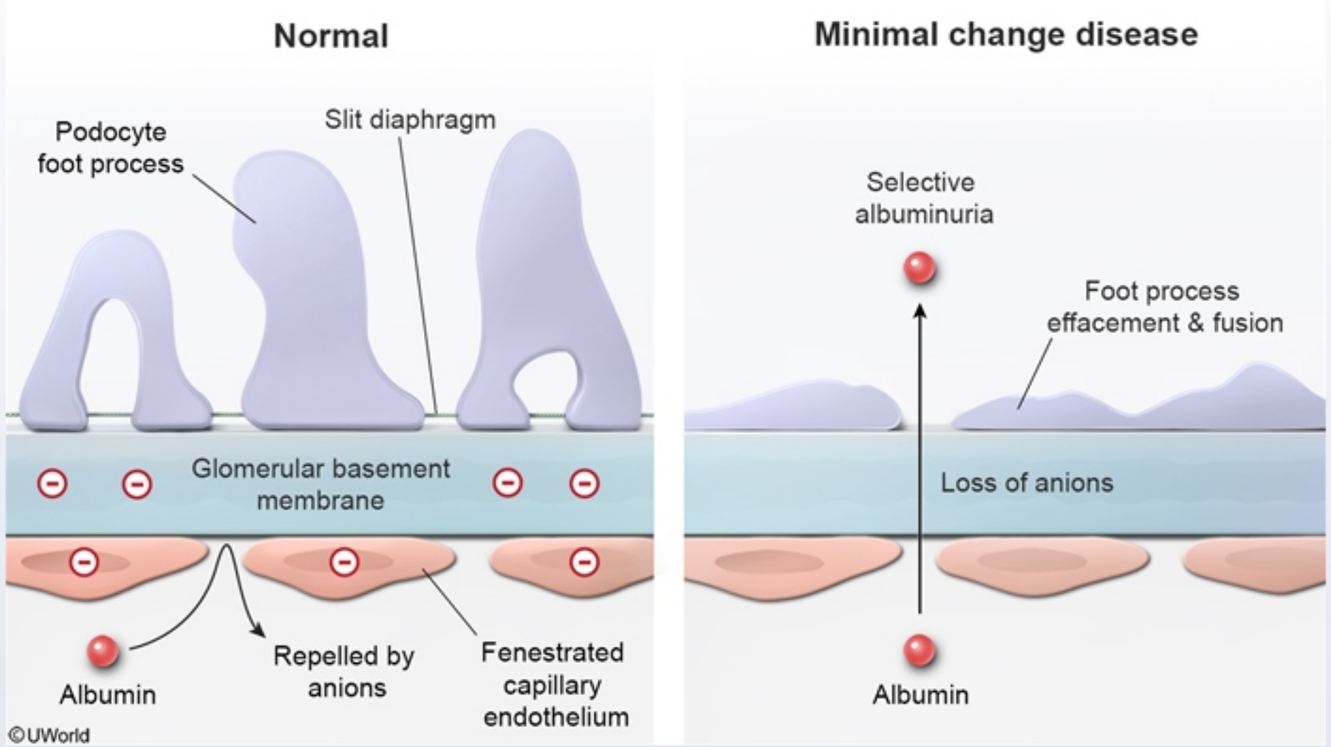


This child with volume overload (eg, facial puffiness, edema) and nephrotic-range proteinuria consisting mainly of albumin most likely has **minimal change disease**, the most common cause of **nephrotic syndrome** in **children**.

Renal filtration of macromolecules is mediated by the glomerular filtration barrier, which consists of fenestrated endothelium, the glomerular basement membrane (GBM), and podocytes. This barrier has selective permeability based on molecular size and charge. Size selectivity is dependent on pores in the GBM and the thin membrane between the foot processes of podocytes (slit diaphragm). Charge selectively is reliant on polyanions (eg, heparan sulfate) on the GBM and endothelial cells, which repel negatively charged molecules such as albumin.

Albumin is small enough to fit through pores in the GBM and slit diaphragms, but it is not normally filtered through the glomerular filtration barrier due to its negative charge. In patients with minimal change disease, systemic T-cell dysfunction leads to the production of glomerular permeability

This child with volume overload (eg, facial puffiness, edema) and nephrotic range proteinuria consisting mainly of albumin most likely has **minimal change disease**, the most common cause of **nephrotic syndrome** in **children**.

Renal filtration of macromolecules is mediated by the glomerular filtration barrier, which consists of fenestrated endothelium, the glomerular basement membrane (GBM), and podocytes. This barrier has selective permeability based on molecular size and charge. Size selectivity is dependent on pores in the GBM and the thin membrane between the foot processes of podocytes (slit diaphragm). Charge selectively is reliant on polyanions (eg, heparan sulfate) on the GBM and endothelial cells, which repel negatively charged molecules such as albumin.

Albumin is small enough to fit through pores in the GBM and slit diaphragms, but it is not normally filtered through the glomerular filtration barrier due to its negative charge. In patients with minimal change disease, systemic T-cell dysfunction leads to the production of glomerular permeability factor, a cytokine that causes **podocyte foot process fusion** and decreases the anionic properties of the GBM. **Loss of negative charge** leads to increased filtration of negatively charged plasma proteins and selective loss of albumin in the urine (**selective albuminuria**).

**(Choice A)** Low-molecular-weight proteins (eg, beta-2 microglobulin, immunoglobulin light chains) are normally filtered by the glomerulus and almost completely reabsorbed in the proximal tubule. Tubular proteinuria occurs when proximal tubular function is disrupted (eg, tubulointerstitial nephritis).

**(Choice C)** Inflammation of the urinary tract (eg, due to infection) causes production of a proteinaceous inflammatory exudate that can leak into the urine. However, the proteinuria is generally mild (non-nephrotic range) and often accompanied by leukocyturia.

**(Choices D and E)** Overflow proteinuria can occur if a particular protein is produced in excess amounts, leading to increased glomerular filtration and excretion of that protein. This can occur with excess light chain production in multiple myeloma or in rhabdomyolysis, in which necrosis of the skeletal muscle leads to increased excretion of myoglobin in the urine.

**Educational objective:**
Minimal change disease is the most common cause of nephrotic syndrome in children. Systemic T-cell dysfunction leads to the production of glomerular permeability factor, which causes podocyte foot process fusion and decreases the anionic properties of the glomerular basement membrane. The loss of negative charge leads to selective albuminuria.

**References**

- Role of the podocyte in proteinuria.

A 72-year-old man is brought to the emergency department due to diarrhea and vomiting for the last 24 hours. The patient's daughter states that he has been unable to take in much fluid during this time. He has hypertension treated with hydrochlorothiazide, which he has not taken since the onset of symptoms. Blood pressure is 90/60 mm Hg and pulse is 105/min. Examination shows dry mucous membranes. Urinalysis reveals concentrated urine with a specific gravity of 1.030. Which of the following changes in renal plasma flow (RPF), glomerular filtration rate (GFR), and filtration fraction (FF) are most likely to be present in this patient as compared with the normal state?

| | RPF | GFR | FF |
|---|---|---|---|
| A. | ↓↓ | ↓ | ↑ |
| B. | ↓↓ | ↓ | ↓ |
| C. | ↓↓ | ↑ | ↓ |
| D. | ↓ | ↑ | ↑ |
| E. | ↑ | ↑ | ↓ |

Submit

A 72-year-old man is brought to the emergency department due to diarrhea and vomiting for the last 24 hours. The patient's daughter states that he has been unable to take in much fluid during this time. He has hypertension treated with hydrochlorothiazide, which he has not taken since the onset of symptoms. Blood pressure is 90/60 mm Hg and pulse is 105/min. Examination shows dry mucous membranes. Urinalysis reveals concentrated urine with a specific gravity of 1.030. Which of the following changes in renal plasma flow (RPF), glomerular filtration rate (GFR), and filtration fraction (FF) are most likely to be present in this patient as compared with the normal state?

| | RPF | GFR | FF |
|---|---|---|---|
| ✓ A. | ↓↓ (54%) | ↓ | ↑ |
| B. | ↓↓ (26%) | ↓ | ↓ |
| C. | ↓↓ (5%) | ↑ | ↓ |
| D. | ↓ (12%) | ↑ | ↑ |
| E. | ↑ (1%) | ↑ | ↓ |

Omitted
Correct answer
A

54%
Answered correctly

01 sec
Time Spent

01/27/2020
Last Updated

Explanation

## Glomerular filtration rate autoregulation

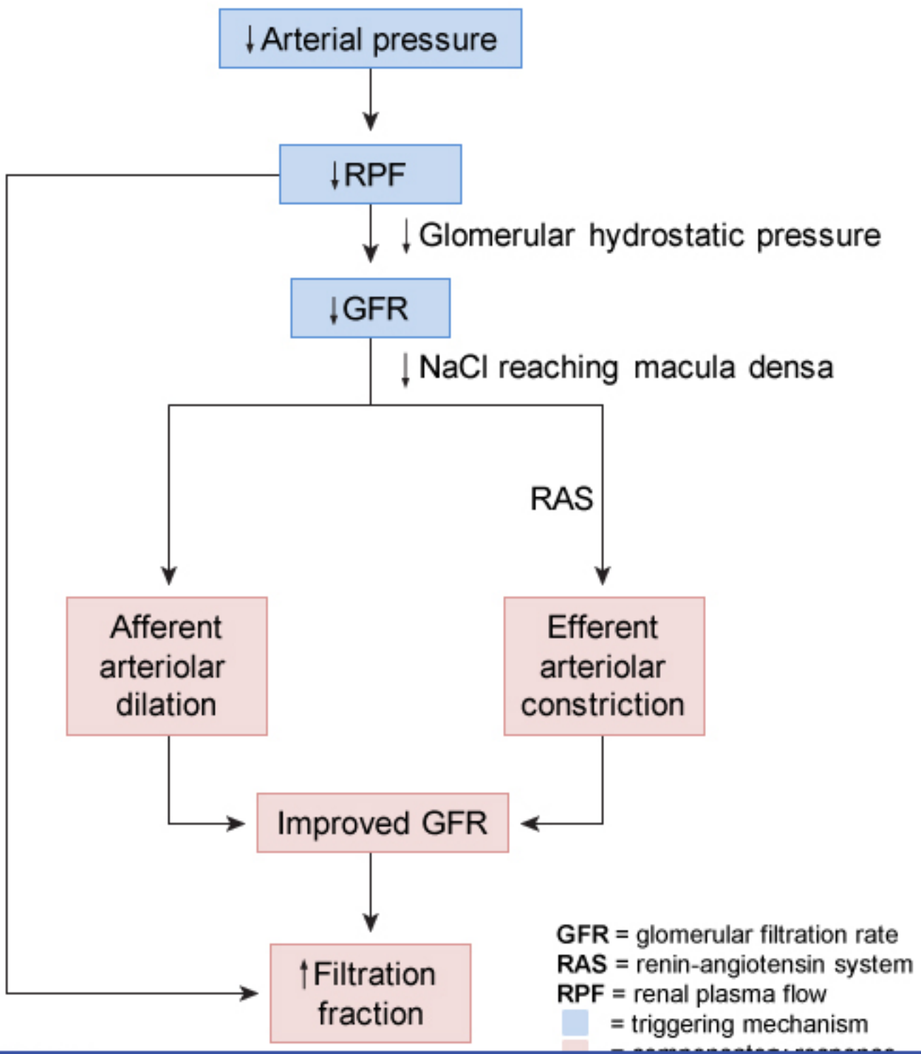

Filtration of fluid through the glomeruli depends on the **renal plasma flow** (RPF) and the **glomerular filtration rate** (GFR). The GFR is the volume of fluid filtered from the renal glomerular capillaries into the Bowman capsule per unit of time. The RPF is the volume of plasma delivered to the kidney per unit of time. The **filtration fraction** (FF) is the ratio of GFR to RPF (FF = GFR/RPF). On average, approximately one-fifth of the plasma that passes through the glomerular capillaries is filtered into the Bowman capsule.

This patient is severely hypovolemic due to profuse diarrhea and vomiting. The decline in circulating blood volume is sensed by arterial and cardiac baroreceptors and triggers increased systemic arteriolar vasoconstriction. Renal vasoconstriction further lowers the RPF, which is already decreased due to the decline in circulating blood volume. Decreased RPF causes glomerular perfusion pressure to drop, lowering the GFR and reducing **distal tubule sodium delivery**. This stimulates secretion of renin and increased **angiotensin II** production. Angiotensin II preferentially constricts the efferent glomerular arteriole, which increases hydrostatic pressure in the glomerular capillaries to maintain GFR (**autoregulation**). Due to this compensatory mechanism, the decrease in GFR is less pronounced than the decrease in RPF, resulting in an increased FF **(Choices B, C, and E)**. As RPF continues to decline, increasing glomerular oncotic pressure will eventually overwhelm the compensatory increase in hydrostatic pressure, leading to a precipitous drop in GFR and subsequent renal failure.

**(Choice D)** Autoregulation improves but often cannot completely normalize the GFR in the setting of decreased renal perfusion pressure. If the net GFR were increased above normal, it would result in decreased renin formation and loss of the angiotensin II-driven arteriolar constriction required to maintain it.

**Educational objective:**
Hypovolemia results in a reduced renal plasma flow (RPF) and glomerular filtration rate (GFR). This leads to compensatory efferent arteriolar vasoconstriction, which raises the filtration fraction and maintains GFR at near-normal levels. As RPF continues to decline, increasing glomerular oncotic pressure will eventually overwhelm the compensatory increase in hydrostatic pressure, leading to a precipitous drop in GFR and renal failure.

| Pathology | Renal, Urinary Systems & Electrolytes | Prerenal azotemia |
|---|---|---|
| Subject | System | Topic |

Copyright © UWorld. All rights reserved.

A 21-year-old man is brought to the emergency department due to diffuse muscle aches and weakness. He has also noticed darkening of his urine. The patient recently joined the military and was participating in rigorous training exercises in hot weather earlier in the day. He has no significant medical conditions and takes no medications. Medical evaluation and laboratory testing performed prior to military enlistment showed no abnormalities. Temperature is 36.7 C (98 F), blood pressure is 100/60 mm Hg, pulse is 105/min, and respirations are 16/min. Physical examination shows dry mucous membranes and muscle tenderness over the bilateral thighs and calves. Laboratory results are as follows:

| | |
|---|---|
| Sodium | 136 mEq/L |
| Potassium | 5.6 mEq/L |
| Chloride | 100 mEq/L |
| Bicarbonate | 18 mEq/L |
| Blood urea nitrogen | 36 mg/dL |
| Creatinine | 2.0 mg/dL |
| Calcium | 6.8 mg/dL |
| Phosphorus | 7.8 mg/dL |
| Creatine kinase | 22,000 U/L (normal: 30-170) |

Which of the following urine microscopy findings is most likely to be seen in this patient?

A. Dysmorphic red blood cells
B. Eosinophils
C. Granular casts
D. Isomorphic red blood cells

| | |
|---|---|
| Potassium | 5.6 mEq/L |
| Chloride | 100 mEq/L |
| Bicarbonate | 18 mEq/L |
| Blood urea nitrogen | 36 mg/dL |
| Creatinine | 2.0 mg/dL |
| Calcium | 6.8 mg/dL |
| Phosphorus | 7.8 mg/dL |
| Creatine kinase | 22,000 U/L (normal: 30-170) |

Which of the following urine microscopy findings is most likely to be seen in this patient?

- A. Dysmorphic red blood cells (16%)
- B. Eosinophils (1%)
- ✓ C. Granular casts (54%)
- D. Isomorphic red blood cells (9%)
- E. Polymorphonuclear leukocytes (1%)
- F. Red blood cell casts (16%)

Omitted
Correct answer

54%
Answered correctly

03 secs
Time Spent

01/29/2020
Last Updated

| Urinary casts | Composition | Associated conditions |
|---|---|---|
| **Hyaline** | Tamm-Horsfall protein | Nonspecific, concentrated urine |
| **Fatty** | Lipid droplets | Nephrotic syndrome |
| **Waxy** | Degenerated hyaline cast | Chronic kidney disease |
| **Granular (muddy brown)** | Sloughed tubular epithelial cells with pigmented granules | Acute tubular necrosis |
| **WBC** | White blood cells | Pyelonephritis, interstitial nephritis |
| **RBC** | Red blood cells | Glomerulonephritis |

This patient's presentation is consistent with **rhabdomyolysis**, which is characterized by skeletal muscle necrosis and the release of intracellular breakdown products into the circulation. The condition is most commonly caused by trauma, sepsis, drugs/toxins (eg, statins, alcohol, cocaine), and **overexertion** (particularly in hot climates). Patients classically have **myalgia and weakness** (predominantly in the proximal muscles, lower back, and calves) and dark urine (due to **myoglobinuria**). Laboratory studies often show markedly **elevated creatine kinase** levels and acute kidney injury with electrolyte disturbances (eg, hyperkalemia, hyperphosphatemia, hypocalcemia, metabolic acidosis).

**Acute kidney injury** in rhabdomyolysis occurs due to myoglobin degradation and heme pigment release. Heme pigment causes acute tubular necrosis (ATN) through direct cytotoxicity and renal vasoconstriction (ie, ischemia). In ATN, injured tubular epithelial cells, with their deeply pigmented, granular contents, slough off into the tubular lumen, forming granular, muddy brown casts. Heme pigment in myoglobin cross-reacts with the urine dipstick reagent that detects hemoglobin, leading to a false-positive result for blood in urine; however, microscopy shows no red blood cells (RBCs).

This patient's presentation is consistent with **rhabdomyolysis**, which is characterized by skeletal muscle necrosis and the release of intracellular breakdown products into the circulation. The condition is most commonly caused by trauma, sepsis, drugs/toxins (eg, statins, alcohol, cocaine), and **overexertion** (particularly in hot climates). Patients classically have **myalgia and weakness** (predominantly in the proximal muscles, lower back, and calves) and dark urine (due to **myoglobinuria**). Laboratory studies often show markedly **elevated creatine kinase** levels and acute kidney injury with electrolyte disturbances (eg, hyperkalemia, hyperphosphatemia, hypocalcemia, metabolic acidosis).

**Acute kidney injury** in rhabdomyolysis occurs due to myoglobin degradation and heme pigment release. Heme pigment causes acute tubular necrosis (ATN) through direct cytotoxicity and renal vasoconstriction (ie, ischemia). In ATN, injured tubular epithelial cells, with their deeply pigmented, granular contents, slough off into the tubular lumen, forming granular, muddy brown casts. Heme pigment in myoglobin cross-reacts with the urine dipstick reagent that detects hemoglobin, leading to a false-positive result for blood in urine; however, microscopy shows no red blood cells (RBCs).

**(Choices A, D, and F)** Dysmorphic RBCs and RBC casts are typically seen in patients with glomerulonephritis. Dysmorphic RBCs have abnormal shapes due to deformation as they pass through the glomerular basement membrane and osmotic stress in the renal tubules. Normal-appearing (isomorphic) RBCs are seen in nonglomerular sources of hematuria, such as nephrolithiasis or urinary tract malignancies.

**(Choice B)** Urinary eosinophils are suggestive of acute interstitial nephritis (AIN), although they may be associated with other conditions (eg, kidney transplant rejection, pyelonephritis). AIN results from immune-mediated tubulointerstitial injury often caused by medications (eg, nonsteroidal anti-inflammatory drugs, penicillins). Patients classically have some combination of rash, fever, and eosinophilia.

**(Choice E)** Polymorphonuclear leukocytes in the urine indicate inflammation, which most commonly occurs due to infection. Interstitial nephritis, renal tuberculosis, and gonorrhea/chlamydia urethritis should be considered in patients with negative urine cultures (sterile pyuria).

**Educational objective:**
Rhabdomyolysis usually presents with myalgia, proximal muscle weakness, and dark urine (myoglobinuria) in the setting of trauma, sepsis, or overexertion. Kidney injury occurs due to heme pigment-mediated tubular injury, leading to acute tubular necrosis. Urine microscopy typically reveals granular, muddy brown casts.

Pathology Renal, Urinary Systems & Electrolytes Rhabdomyolysis

breakdown products into the circulation. The condition is most commonly caused by trauma, sepsis, drugs/toxins (eg, statins, alcohol, cocaine),

**Exhibit Display**

Acute tubular necrosis Acute tubular necrosis

Zoom In Zoom Out Reset Add To New Card | Existing Card

breakdown products into the circulation. The condition is most commonly caused by trauma, sepsis, drugs/toxins (eg, statins, alcohol, cocaine),

**Exhibit Display**

Acute tubular necrosis Acute tubular necrosis

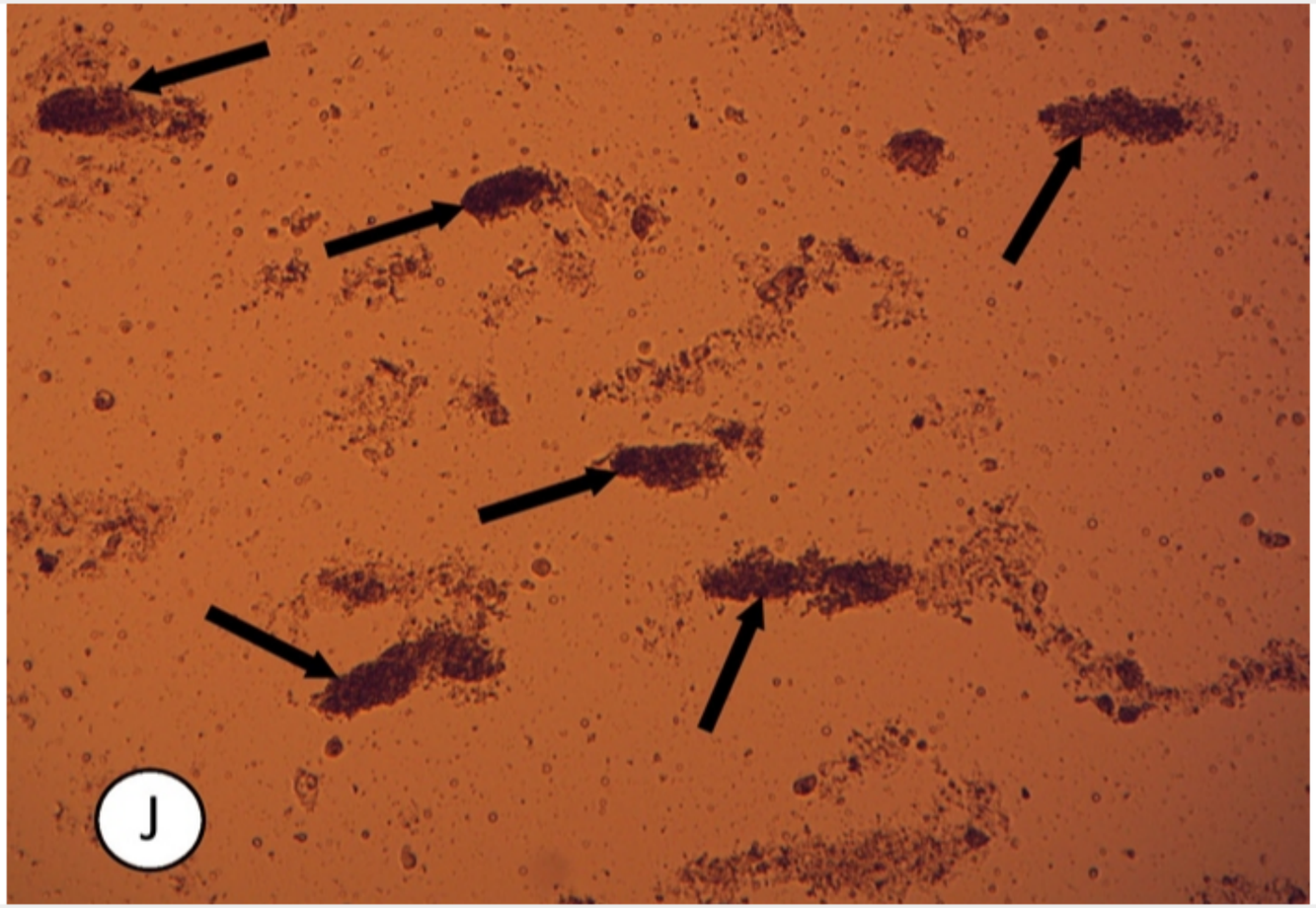


Zoom In Zoom Out Reset Add To New Card | Existing Card

A 41-year-old woman is being evaluated for peripheral edema. The patient has gained 6.8 kg (15 lb) over the past 8 weeks. Her urine is "frothy." She has no other medical problems and takes no medications. The patient does not use tobacco, alcohol, or illicit drugs. Blood pressure is 140/90 mm Hg and pulse is 80/min. Examination shows generalized edema. Heart sounds are normal. The abdomen is soft and nontender. Serum creatinine is 1.1 mg/dL. Urinalysis shows 4+ protein, 0-3 leukocytes/hpf, and oval fat bodies. Serum contains IgG4 antibodies to the phospholipase A2 receptor (PLA2R), a transmembrane protein abundant on podocytes. Which of the following is the most likely diagnosis?

- A. Focal segmental glomerulosclerosis
- B. Membranous nephropathy
- C. Minimal change disease
- D. Mixed cryoglobulinemia
- E. Multiple myeloma

Submit

A 41-year-old woman is being evaluated for peripheral edema. The patient has gained 6.8 kg (15 lb) over the past 8 weeks. Her urine is "frothy." She has no other medical problems and takes no medications. The patient does not use tobacco, alcohol, or illicit drugs. Blood pressure is 140/90 mm Hg and pulse is 80/min. Examination shows generalized edema. Heart sounds are normal. The abdomen is soft and nontender. Serum creatinine is 1.1 mg/dL. Urinalysis shows 4+ protein, 0-3 leukocytes/hpf, and oval fat bodies. Serum contains IgG4 antibodies to the phospholipase A2 receptor (PLA2R), a transmembrane protein abundant on podocytes. Which of the following is the most likely diagnosis?

- A. Focal segmental glomerulosclerosis (13%)
- ✓ B. Membranous nephropathy (73%)
- C. Minimal change disease (8%)
- D. Mixed cryoglobulinemia (2%)
- E. Multiple myeloma (1%)

Omitted
Correct answer
B

73%
Answered correctly

02 secs
Time Spent

03/28/2020
Last Updated

Explanation

This patient with weight gain and edema with 4+ protein and oval fat bodies on urinalysis has **nephrotic syndrome**. The presence of **phospholipase A2 receptor** (PLA2R) antibodies suggests a diagnosis of membranous nephropathy. Antibodies against PLA2R, primarily IgG4, can lead to immune deposition in the glomerulus and are thought to be a major factor in the pathogenesis of primary (idiopathic) **membranous nephropathy**, a common cause of nephrotic syndrome in adults.

Explanation

This patient with weight gain and edema with 4+ protein and oval fat bodies on urinalysis has **nephrotic syndrome**. The presence of **phospholipase A2 receptor** (PLA2R) antibodies suggests a diagnosis of membranous nephropathy. Antibodies against PLA2R, primarily IgG4, can lead to immune deposition in the glomerulus and are thought to be a major factor in the pathogenesis of primary (idiopathic) **membranous nephropathy**, a common cause of nephrotic syndrome in adults.

Anti-PLA2R antibodies are highly specific for membranous nephropathy; positive titers effectively rule out other causes of nephrotic syndrome (eg, focal segmental glomerulosclerosis) and may eliminate the need for invasive renal biopsy. In addition, **titers correlate with disease activity**, and serial measurements can be used to determine the efficacy of immunosuppressive therapy.

**(Choice A)** Focal segmental glomerulosclerosis causes nephrotic syndrome but is caused by direct (eg, cytotoxic drugs) or indirect (eg, glomerular hyperfiltration) podocyte injury. It is not associated with anti-PLA2R antibodies.

**(Choice C)** Minimal change disease may be due to abnormal T-cell production of a glomerular permeability factor that affects the glomerular capillary wall, leading to fusion of the foot processes and marked proteinuria. There has been no association with anti-PLA2R antibodies.

**(Choice D)** Mixed cryoglobulinemia is associated with IgM deposition in the glomerulus, leading to basement membrane thickening and cellular proliferation. Renal disease typically presents as membranoproliferative glomerulonephritis with hematuria and red blood cell casts. It is most common in patients with chronic hepatitis C infection.

**(Choice E)** Renal disease in multiple myeloma is due to deposition of light chains (ie, cast nephropathy) and is not associated with anti-PLA2R antibodies.

**Educational objective:**
Primary (idiopathic) membranous nephropathy is associated with IgG4 antibodies to the phospholipase A2 receptor, which might play a role in development of the disease. Antibody titers are useful for diagnosis and correlate with disease activity.

**References**

- M-type phospholipase A2 receptor as target antigen in idiopathic membranous nephropathy.

**nephropathy**, a common cause of nephrotic syndrome in adults.

Anti-PLA2R antibodies are highly specific for membranous nephropathy; positive titers effectively rule out other causes of nephrotic syndrome (eg, focal segmental glomerulosclerosis) and may eliminate the need for invasive renal biopsy. In addition, **titers correlate with disease activity**, and serial measurements can be used to determine the efficacy of immunosuppressive therapy.

**(Choice A)** Focal segmental glomerulosclerosis causes nephrotic syndrome but is caused by direct (eg, cytotoxic drugs) or indirect (eg, glomerular hyperfiltration) podocyte injury. It is not associated with anti-PLA2R antibodies.

**(Choice C)** Minimal change disease may be due to abnormal T-cell production of a glomerular permeability factor that affects the glomerular capillary wall, leading to fusion of the foot processes and marked proteinuria. There has been no association with anti-PLA2R antibodies.

**(Choice D)** Mixed cryoglobulinemia is associated with IgM deposition in the glomerulus, leading to basement membrane thickening and cellular proliferation. Renal disease typically presents as membranoproliferative glomerulonephritis with hematuria and red blood cell casts. It is most common in patients with chronic hepatitis C infection.

**(Choice E)** Renal disease in multiple myeloma is due to deposition of light chains (ie, cast nephropathy) and is not associated with anti-PLA2R antibodies.

**Educational objective:**
Primary (idiopathic) membranous nephropathy is associated with IgG4 antibodies to the phospholipase A2 receptor, which might play a role in development of the disease. Antibody titers are useful for diagnosis and correlate with disease activity.

**References**

- M-type phospholipase A2 receptor as target antigen in idiopathic membranous nephropathy.

| Pathology | Renal, Urinary Systems & Electrolytes | Membranous nephropathy |
|---|---|---|
| Subject | System | Topic |

Copyright © UWorld. All rights reserved.

A 60-year-old woman is being evaluated for abnormal renal function. She is found to have a serum creatinine of 2.2 mg/dL on routine laboratory monitoring; her creatinine level a year ago was 1.2 mg/dL. The patient has a history of nonischemic cardiomyopathy and systolic heart failure and has been on a stable medical regimen for the past 2 years. She has no dyspnea, fever, rash, or lower extremity swelling but has been taking ibuprofen for 2 weeks due to left knee osteoarthritis. Urinalysis reveals the following:

| | |
|---|---|
| Protein | none |
| White blood cells | none |
| Red blood cells | none |
| Sediment | none |

Ibuprofen is discontinued, and her kidney function returns to normal in a week. Which of the following best explains this patient's transient deterioration in renal function?

- A. Impaired afferent arteriolar vasodilation
- B. Impaired efferent arteriolar vasodilation
- C. Interstitial inflammation
- D. Toxic injury to the proximal tubules
- E. Vasculitis of the glomerular capillaries

Submit

A 60-year-old woman is being evaluated for abnormal renal function. She is found to have a serum creatinine of 2.2 mg/dL on routine laboratory monitoring; her creatinine level a year ago was 1.2 mg/dL. The patient has a history of nonischemic cardiomyopathy and systolic heart failure and has been on a stable medical regimen for the past 2 years. She has no dyspnea, fever, rash, or lower extremity swelling but has been taking ibuprofen for 2 weeks due to left knee osteoarthritis. Urinalysis reveals the following:

| | |
|---|---|
| Protein | none |
| White blood cells | none |
| Red blood cells | none |
| Sediment | none |

Ibuprofen is discontinued, and her kidney function returns to normal in a week. Which of the following best explains this patient's transient deterioration in renal function?

- ✓ A. Impaired afferent arteriolar vasodilation (77%)
- B. Impaired efferent arteriolar vasodilation (6%)
- C. Interstitial inflammation (10%)
- D. Toxic injury to the proximal tubules (5%)
- E. Vasculitis of the glomerular capillaries (0%)

Omitted
Correct answer
A

77%
Answered correctly

02 secs
Time Spent

03/24/2020
Last Updated

## NSAID induced acute kidney injury

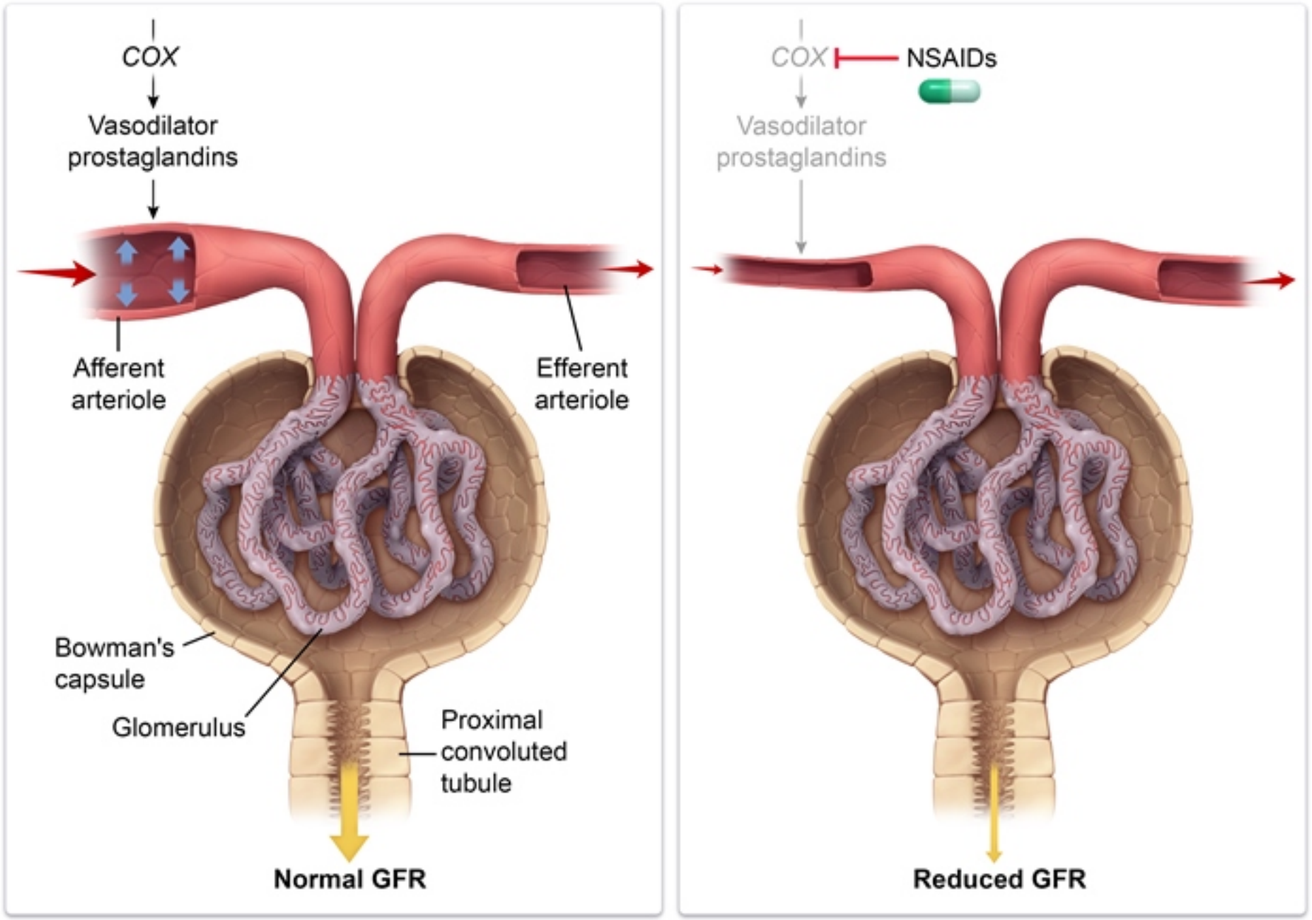


**COX** = Cyclooxygenase; **GFR** = glomerular filtration rate.

©UWorld

This patient developed acute kidney injury after taking ibuprofen. **Nonsteroidal anti-inflammatory drugs** (NSAIDs) (eg, ibuprofen, aspirin,

This patient developed acute kidney injury after taking ibuprofen. **Nonsteroidal anti-inflammatory drugs** (NSAIDs) (eg, ibuprofen, aspirin, naproxen) exert their anti-inflammatory, analgesic, and antipyretic effects through the inhibition of the cyclooxygenase enzymes. These enzymes are the rate-limiting step in the formation of prostanoids (ie, prostaglandins, thromboxane), which are involved in mediating pain and inflammation.

Prostaglandins also help maintain renal perfusion by dilating the afferent arteriole, particularly in patients with intravascular volume depletion (eg, congestive heart failure, diarrhea, excessive diuresis) or chronic kidney disease. In such patients, **increased prostaglandin synthesis** is necessary to **preserve renal blood flow** and maintain glomerular filtration rate. In at-risk patients, **inhibition of afferent dilation** with NSAIDs results in reduced glomerular filtration and **prerenal azotemia** with elevations in creatinine and blood urea nitrogen (ratio >20:1).

NSAID-induced acute kidney injury is often diagnosed incidentally on laboratory tests performed for other reasons, and patients are generally asymptomatic. **Urinalysis** is typically **bland** without proteinuria, hematuria, or casts. Prolonged NSAID use can cause chronic kidney disease (analgesic nephropathy) due to papillary necrosis and chronic interstitial nephritis.

**(Choice B)** Activation of the renin-angiotensin-aldosterone system results in efferent arteriole constriction, and ACE inhibitors (eg, lisinopril) cause efferent vasodilation. These medications can cause acute kidney injury, particularly in patients with volume depletion or bilateral renal artery stenosis. However, NSAID-induced kidney injury is due to impaired afferent arteriole vasodilation.

**(Choice C)** NSAIDs are a common cause of acute interstitial nephritis (AIN). However, urinalysis in AIN typically demonstrates white blood cells and white blood cell casts, and patients commonly develop fevers and rash.

**(Choice D)** Acute tubular necrosis (ATN) can occur due to toxic (eg, aminoglycosides, radiocontrast agents) or ischemic (eg, hypotension) insults. However, urinalysis would demonstrate muddy-brown, granular casts, and NSAIDs are not commonly associated with ATN.

**(Choice E)** Vasculitis involving the glomerular capillaries (eg, granulomatosis with polyangiitis, microscopic polyangiitis) causes a nephritic syndrome; urinalysis would demonstrate red blood cells and red blood cell casts. In addition, patients with vasculitides typically have associated systemic symptoms (eg, fever, fatigue, weight loss).

**Educational objective:**
Patients with intravascular volume depletion (eg, congestive heart failure, diarrhea, excessive diuresis) and chronic kidney disease depend on renal prostaglandin production to dilate the afferent glomerular arteriole and maintain the glomerular filtration rate. Nonsteroidal anti-inflammatory drugs inhibit prostaglandin synthesis, which can cause prerenal azotemia in at-risk patients.

necessary to **preserve renal blood flow** and maintain glomerular filtration rate. In at-risk patients, **inhibition of afferent dilation** with NSAIDs results in reduced glomerular filtration and **prerenal azotemia** with elevations in creatinine and blood urea nitrogen (ratio >20:1).

NSAID-induced acute kidney injury is often diagnosed incidentally on laboratory tests performed for other reasons, and patients are generally asymptomatic. **Urinalysis** is typically **bland** without proteinuria, hematuria, or casts. Prolonged NSAID use can cause chronic kidney disease (analgesic nephropathy) due to papillary necrosis and chronic interstitial nephritis.

**(Choice B)** Activation of the renin-angiotensin-aldosterone system results in efferent arteriole constriction, and ACE inhibitors (eg, lisinopril) cause efferent vasodilation. These medications can cause acute kidney injury, particularly in patients with volume depletion or bilateral renal artery stenosis. However, NSAID-induced kidney injury is due to impaired afferent arteriole vasodilation.

**(Choice C)** NSAIDs are a common cause of acute interstitial nephritis (AIN). However, urinalysis in AIN typically demonstrates white blood cells and white blood cell casts, and patients commonly develop fevers and rash.

**(Choice D)** Acute tubular necrosis (ATN) can occur due to toxic (eg, aminoglycosides, radiocontrast agents) or ischemic (eg, hypotension) insults. However, urinalysis would demonstrate muddy-brown, granular casts, and NSAIDs are not commonly associated with ATN.

**(Choice E)** Vasculitis involving the glomerular capillaries (eg, granulomatosis with polyangiitis, microscopic polyangiitis) causes a nephritic syndrome; urinalysis would demonstrate red blood cells and red blood cell casts. In addition, patients with vasculitides typically have associated systemic symptoms (eg, fever, fatigue, weight loss).

**Educational objective:**
Patients with intravascular volume depletion (eg, congestive heart failure, diarrhea, excessive diuresis) and chronic kidney disease depend on renal prostaglandin production to dilate the afferent glomerular arteriole and maintain the glomerular filtration rate. Nonsteroidal anti-inflammatory drugs inhibit prostaglandin synthesis, which can cause prerenal azotemia in at-risk patients.

| Pathology | Renal, Urinary Systems & Electrolytes | NSAIDs |
|---|---|---|
| Subject | System | Topic |

Copyright © UWorld. All rights reserved.

A 5-year-old boy is brought to the office with generalized edema that developed following a mild upper respiratory infection. Medical history is unremarkable. Blood pressure and heart rate are normal. Serum creatinine levels are normal. Urinalysis shows massive proteinuria with no hematuria. Further analysis reveals that urine protein consists principally of albumin with only trace amounts of IgG and alpha-2-macroglobulin. Which of the following pathologic changes is the most likely cause of this patient's urinary protein loss?

A. Glomerular crescent formation

B. Loss of glomerular basement membrane anions

C. Nodular glomerulosclerosis

D. Thinning of the glomerular basement membrane

E. Tubular necrosis and epithelial shedding

Submit

A 5-year-old boy is brought to the office with generalized edema that developed following a mild upper respiratory infection. Medical history is unremarkable. Blood pressure and heart rate are normal. Serum creatinine levels are normal. Urinalysis shows massive proteinuria with no hematuria. Further analysis reveals that urine protein consists principally of albumin with only trace amounts of IgG and alpha-2-macroglobulin. Which of the following pathologic changes is the most likely cause of this patient's urinary protein loss?

- A. Glomerular crescent formation (3%)
- ✓ B. Loss of glomerular basement membrane anions (77%)
- C. Nodular glomerulosclerosis (3%)
- D. Thinning of the glomerular basement membrane (13%)
- E. Tubular necrosis and epithelial shedding (1%)

Omitted
Correct answer
B

77%
Answered correctly

01 sec
Time Spent

01/14/2020
Last Updated

Explanation

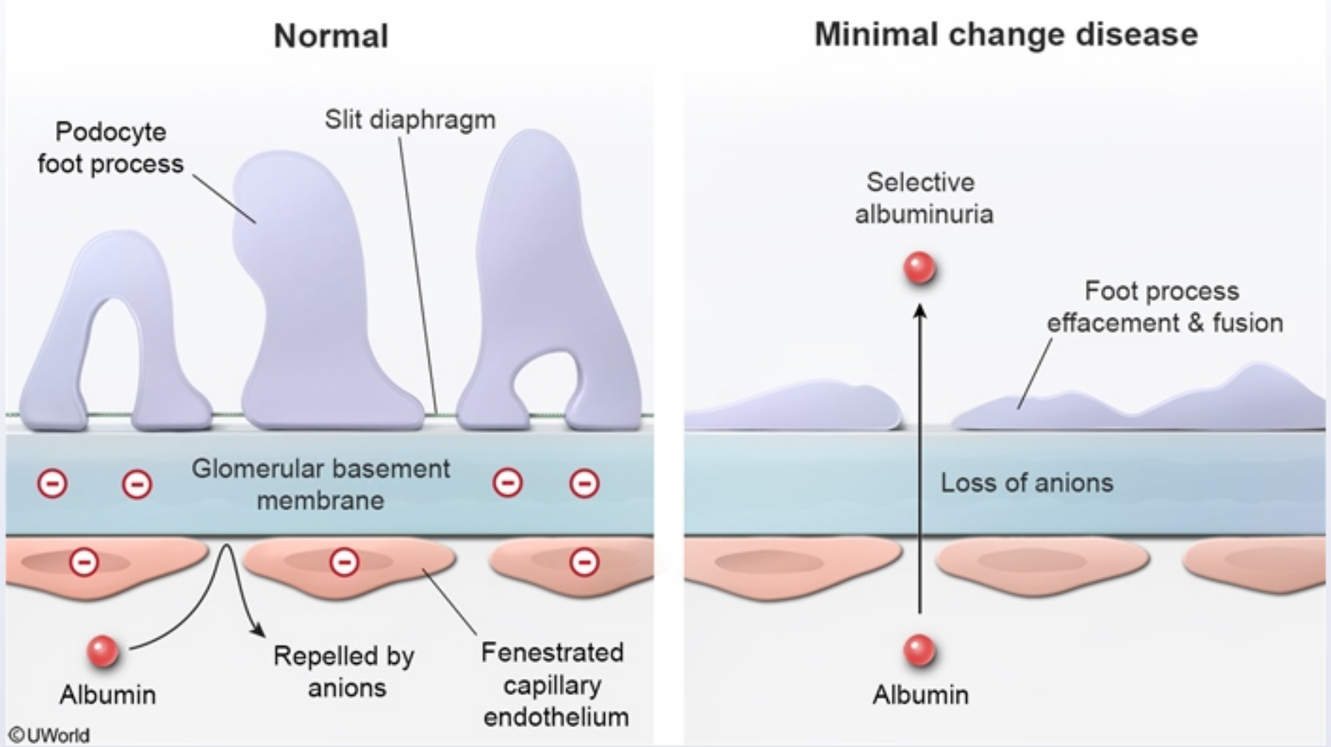


This pediatric patient presenting with generalized edema and massive proteinuria following an upper respiratory infection likely has **minimal change disease**, the most common cause of nephrotic syndrome in children.

Minimal change disease is caused by **immune dysregulation**, as suggested by its association with respiratory infections, immunizations, and atopic disorders, as well as its excellent response to corticosteroids. Immune dysfunction leads to overproduction of a **glomerular permeability factor** (possibly IL-13) that directly **damages podocytes**, leading to foot process effacement and fusion as well as decreased anionic properties of the glomerular basement membrane. **Loss of negative charge** leads to selective loss of albumin in the urine (**selective albuminuria**), in contrast to the nonselective proteinuria seen with other forms of nephrotic syndrome (eg, membranous nephropathy, focal segmental glomerulosclerosis).

©UWorld

This pediatric patient presenting with generalized edema and massive proteinuria following an upper respiratory infection likely has **minimal change disease**, the most common cause of nephrotic syndrome in children.

Minimal change disease is caused by **immune dysregulation**, as suggested by its association with respiratory infections, immunizations, and atopic disorders, as well as its excellent response to corticosteroids. Immune dysfunction leads to overproduction of a **glomerular permeability factor** (possibly IL-13) that directly **damages podocytes**, leading to foot process effacement and fusion as well as decreased anionic properties of the glomerular basement membrane. **Loss of negative charge** leads to selective loss of albumin in the urine (**selective albuminuria**), in contrast to the nonselective proteinuria seen with other forms of nephrotic syndrome (eg, membranous nephropathy, focal segmental glomerulosclerosis).

Despite the dramatic clinical picture, light microscopy and immunofluorescence studies show completely normal kidneys; the characteristic effacement of the podocyte foot processes can be detected only by electron microscopy.

**(Choice A)** Crescent formation is a sign of severe glomerular injury; it is associated with rapidly progressive glomerulonephritis (RPGN), which can occur secondary to multiple diseases (eg, anti–glomerular basement membrane disorder, antineutrophil cytoplasmic antibody vasculitides). However, RPGN typically presents with renal insufficiency and nephritic urine sediment (ie, hematuria, red blood cell casts); massive proteinuria would be unexpected.

**(Choice C)** Nodular glomerulosclerosis (Kimmelstiel-Wilson lesions) occurs in patients with diabetic nephropathy and is characterized by ovoid nodules of hyaline material within the mesangium. Although diabetic nephropathy may present as nephrotic syndrome, patients are typically middle-aged to elderly with a long history of diabetes mellitus.

**(Choice D)** Thinning of the glomerular basement membrane is seen in thin basement membrane nephropathy and Alport syndrome. Thin basement membrane nephropathy is a benign condition typically associated with microscopic hematuria. Alport syndrome is caused by an inherited defect in the formation of type IV collagen; patients have hearing loss, ocular abnormalities, hematuria, and progressive renal insufficiency.

**(Choice E)** Focal tubular epithelial necrosis and cell shedding occur in acute tubular necrosis, which typically follows renal ischemia or exposure to nephrotoxins (eg, aminoglycosides). It manifests as acute renal injury with muddy brown casts, not nephrotic syndrome.

Despite the dramatic clinical picture, light microscopy and immunofluorescence studies show completely normal kidneys; the characteristic effacement of the podocyte foot processes can be detected only by electron microscopy.

**(Choice A)** Crescent formation is a sign of severe glomerular injury; it is associated with rapidly progressive glomerulonephritis (RPGN), which can occur secondary to multiple diseases (eg, anti–glomerular basement membrane disorder, antineutrophil cytoplasmic antibody vasculitides). However, RPGN typically presents with renal insufficiency and nephritic urine sediment (ie, hematuria, red blood cell casts); massive proteinuria would be unexpected.

**(Choice C)** Nodular glomerulosclerosis (Kimmelstiel-Wilson lesions) occurs in patients with diabetic nephropathy and is characterized by ovoid nodules of hyaline material within the mesangium. Although diabetic nephropathy may present as nephrotic syndrome, patients are typically middle-aged to elderly with a long history of diabetes mellitus.

**(Choice D)** Thinning of the glomerular basement membrane is seen in thin basement membrane nephropathy and Alport syndrome. Thin basement membrane nephropathy is a benign condition typically associated with microscopic hematuria. Alport syndrome is caused by an inherited defect in the formation of type IV collagen; patients have hearing loss, ocular abnormalities, hematuria, and progressive renal insufficiency.

**(Choice E)** Focal tubular epithelial necrosis and cell shedding occur in acute tubular necrosis, which typically follows renal ischemia or exposure to nephrotoxins (eg, aminoglycosides). It manifests as acute renal injury with muddy brown casts, not nephrotic syndrome.

**Educational objective:**
Minimal change disease is caused by immune dysregulation and overproduction of a glomerular permeability factor, which damages podocytes and decreases the anionic properties of the glomerular basement membrane. This results in selective loss of albumin in the urine, in contrast to the nonselective proteinuria seen in other forms of nephrotic syndrome.

| Pathology | Renal, Urinary Systems & Electrolytes | Glomerular disorders |
|---|---|---|
| Subject | System | Topic |

Copyright © UWorld. All rights reserved.

1 2 3 4 5 6 7 8 9 10 11 12 13 14 15 16 17 18 19 20 21 22 23 24 25 26 27 28 29 30

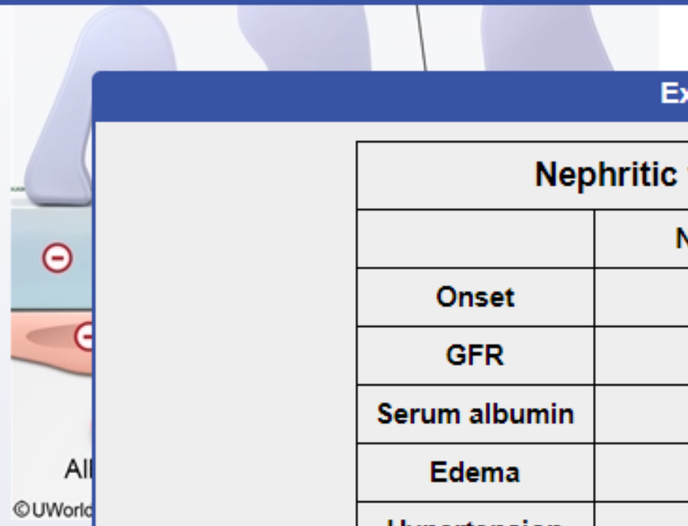


This pediatric patient pres
**change disease**, the mos

Minimal change disease is
atopic disorders, as well a
**factor** (possibly IL-13) tha
the glomerular basement
contrast to the nonselectiv
glomerulosclerosis).

Despite the dramatic clinic
effacement of the podocyt

**(Choice A)** Crescent form
can occur secondary to m
However, RPGN typically presents with renal insufficiency and nephritic urine sediment (ie, hematuria, red blood cell casts); massive proteinuria

## Exhibit Display

| Nephritic vs nephrotic syndrome | | |
|---|---|---|
| | **Nephritic** | **Nephrotic** |
| **Onset** | Abrupt | Insidious |
| **GFR** | Low | Normal or low |
| **Serum albumin** | Normal | Low |
| **Edema** | ± | ++ |
| **Hypertension** | ++ | ± |
| **Casts** | RBC casts | Fatty or none |
| **Proteinuria** | ± | ++ |
| **Hematuria** | ++ | ± |
| **Pyuria** | + | None |

GFR = glomerular filtration rate; RBC = red blood cell.
+ = present; ++ = significant.

Add To New Card | Existing Card

1
2
3
4
5
6
7
8
9
10
11
12
13
14
15
16
17
18
19
20
21
22
23
24
25
26
27
28
29
30

contrast to the nonselective proteinuria seen with other forms of nephrotic syndrome (eg, membranous nephropathy, focal segmental

Exhibit Display

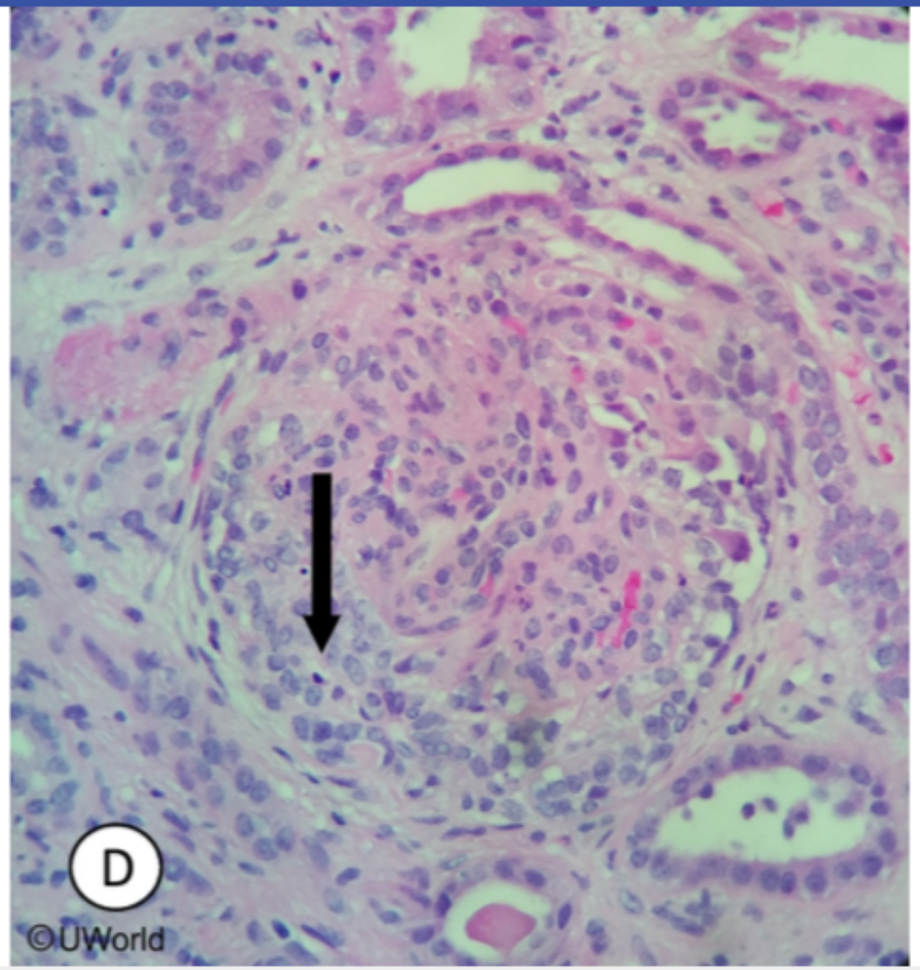


Zoom In | Zoom Out | Reset | Add To New Card | Existing Card

A 30-year-old man is admitted to the hospital due to seizures. The repeated, prolonged tonic-clonic seizures were terminated with intravenous lorazepam in the emergency department. Medical history is significant for amphetamine abuse. The patient develops decreased urine output 24 hours after hospital admission. Temperature is 37.1 C (98.8 F), blood pressure is 140/90 mm Hg, pulse is 88/min, and respirations are 18/min. Examination shows bibasilar lung crackles and mild edema of the lower extremities. Laboratory results are as follows:

| Serum chemistry | |
|---|---|
| Blood urea nitrogen | 40 mg/dL |
| Creatinine | 4.2 mg/dL |
| Potassium | 6.4 mEq/L |

| Urinalysis | |
|---|---|
| Protein | 2+ |
| Blood | 3+ |
| White blood cells | negative |
| Red blood cells | negative |

Which of the following is the most likely cause of this patient's kidney injury?

A. Glomerular injury due to immune complexes
B. Inflammatory reaction of the tubular interstitium
C. Renal infarction due to arterial obstruction
D. Tubular injury due to light-chain deposition

| | |
|---|---|
| Blood urea nitrogen | 40 mg/dL |
| Creatinine | 4.2 mg/dL |
| Potassium | 6.4 mEq/L |

Urinalysis

| | |
|---|---|
| Protein | 2+ |
| Blood | 3+ |
| White blood cells | negative |
| Red blood cells | negative |

Which of the following is the most likely cause of this patient's kidney injury?

- A. Glomerular injury due to immune complexes
- B. Inflammatory reaction of the tubular interstitium
- C. Renal infarction due to arterial obstruction
- D. Tubular injury due to light-chain deposition
- E. Tubular injury due to released hemoglobin
- F. Tubular injury due to released myoglobin

Submit

| | |
|---|---|
| Blood urea nitrogen | 40 mg/dL |
| Creatinine | 4.2 mg/dL |
| Potassium | 6.4 mEq/L |

Urinalysis

| | |
|---|---|
| Protein | 2+ |
| Blood | 3+ |
| White blood cells | negative |
| Red blood cells | negative |

Which of the following is the most likely cause of this patient's kidney injury?

A. Glomerular injury due to immune complexes (7%)

B. Inflammatory reaction of the tubular interstitium (20%)

C. Renal infarction due to arterial obstruction (10%)

D. Tubular injury due to light-chain deposition (2%)

E. Tubular injury due to released hemoglobin (4%)

✓ F. Tubular injury due to released myoglobin (54%)

Omitted
Correct answer

54%
Answered correctly

05 secs
Time Spent

04/27/2020
Last Updated

| Rhabdomyolysis | |
|---|---|
| **Risk factors** | • Crush injury<br>• Prolonged muscle activity (eg, seizure, marathon running)<br>• Drug/medication use (eg, statins, amphetamines, heroin) |
| **Etiology** | • Myocyte necrosis, release of intracellular contents (eg, myoglobin)<br>• Kidney injury: Heme pigment–induced acute tubular necrosis |
| **Laboratory findings** | • ↑↑ Creatine kinase<br>• Myoglobinuria (UA with positive blood but no RBCs on microscopy)<br>• Acute kidney injury & electrolyte abnormalities (eg, ↑ K, ↑ P, ↓ Ca) |

**Ca** = calcium; **K** = potassium; **P** = phosphorus; **RBCs** = red blood cells; **UA** = urinalysis.

This patient with acute kidney injury, hyperkalemia, and urinalysis with 3+ blood but no red blood cells has **rhabdomyolysis**, likely induced by his prolonged seizure. Rhabdomyolysis is characterized by myocyte injury with the release of intracellular muscle contents (ie, myoglobin, electrolytes) into the circulation. It is common in crush injuries, prolonged muscle activity (eg, seizure), or drug use. **Positive blood** on urine dipstick (a reaction that detects the heme pigment in both hemoglobin and myoglobin) in the **absence of red blood cells** on microscopic urinalysis suggests **myoglobinuria**.

Renal injury in rhabdomyolysis results from **myoglobin** filtration and degradation within the glomeruli. **Heme pigment** is released, which causes **acute tubular necrosis** by direct cytotoxicity and renal vasoconstriction. Hyperkalemia, hyperphosphatemia, and hyperuricemia also occur due to myocyte lysis.

**(Choice A)** Immune complex–mediated glomerular injury is seen in a variety of diseases (eg, IgA nephropathy, poststreptococcal glomerulonephritis), but these diseases do not cause myoglobinuria. Urinary cast formation or severe proteinuria are more common manifestations.

**(Choice B)** Acute interstitial nephritis, an inflammatory reaction of the tubular interstitium, is typically associated with a medication exposure (eg, antibiotics) and presents with some combination of fever, eosinophilia, and rash. Urinalysis shows white blood cell casts, not myoglobinuria.

**acute tubular necrosis** by direct cytotoxicity and renal vasoconstriction. Hyperkalemia, hyperphosphatemia, and hyperuricemia also occur due to myocyte lysis.

**(Choice A)** Immune complex–mediated glomerular injury is seen in a variety of diseases (eg, IgA nephropathy, poststreptococcal glomerulonephritis), but these diseases do not cause myoglobinuria. Urinary cast formation or severe proteinuria are more common manifestations.

**(Choice B)** Acute interstitial nephritis, an inflammatory reaction of the tubular interstitium, is typically associated with a medication exposure (eg, antibiotics) and presents with some combination of fever, eosinophilia, and rash. Urinalysis shows white blood cell casts, not myoglobinuria.

**(Choice C)** Renal infarctions can be due to thromboembolic or atheroembolic disease and typically occur in older patients with established atherosclerosis or hypercoagulability. Hematuria with red cells would be expected on urinalysis.

**(Choice D)** Multiple myeloma causes renal injury due to light chain–complex deposition in the renal tubules. This malignancy occurs in older patients and presents with hypercalcemia, anemia, and bone pain. It causes proteinuria (ie, Bence Jones protein), not myoglobinuria.

**(Choice E)** Tubular injury due to released hemoglobin can also cause a heme pigment–induced kidney injury and may occur with hemolytic diseases (eg, paroxysmal nocturnal hemoglobinuria) or incompatible blood transfusion. However, renal failure after a prolonged seizure is more suggestive of rhabdomyolysis.

**Educational objective:**
Rhabdomyolysis is characterized by the release of intracellular muscle contents (eg, myoglobin, electrolytes) due to myocyte injury; it is common with crush injuries, seizures, or drug use (eg, statins). Heme pigment (released from myoglobin after degradation in the kidney) is toxic to tubular cells and can cause acute tubular necrosis. Positive blood on urine dipstick in the absence of red blood cells on microscopic urinalysis suggests myoglobinuria.

| Pathology | Renal, Urinary Systems & Electrolytes | Rhabdomyolysis |
|---|---|---|
| Subject | System | Topic |

Copyright © UWorld. All rights reserved.

A 76-year-old man comes to the office due to bilateral flank pain and nausea. The patient has not urinated for 24 hours. His medical history is significant for diet-controlled type 2 diabetes and degenerative arthritis of the knee. He occasionally takes naproxen for pain. Temperature is 37.3 C (99.1 F), blood pressure is 140/90 mm Hg, and pulse is 90/min. Cardiopulmonary examination shows no abnormalities. Abdominal examination shows suprapubic fullness. Laboratory results show a blood urea nitrogen level of 32 mg/dL and creatinine level of 2.6 mg/dL. Four weeks ago, his laboratory studies were normal. Which of the following is the most likely cause of this patient's renal dysfunction?

A. Diabetic nephropathy

B. Interstitial nephritis

C. Renal tubule injury due to ischemia

D. Renal tubule injury due to protein casts

E. Urethral compression

Submit

A 76-year-old man comes to the office due to bilateral flank pain and nausea. The patient has not urinated for 24 hours. His medical history is significant for diet-controlled type 2 diabetes and degenerative arthritis of the knee. He occasionally takes naproxen for pain. Temperature is 37.3 C (99.1 F), blood pressure is 140/90 mm Hg, and pulse is 90/min. Cardiopulmonary examination shows no abnormalities. Abdominal examination shows suprapubic fullness. Laboratory results show a blood urea nitrogen level of 32 mg/dL and creatinine level of 2.6 mg/dL. Four weeks ago, his laboratory studies were normal. Which of the following is the most likely cause of this patient's renal dysfunction?

A. Diabetic nephropathy (6%)

B. Interstitial nephritis (21%)

C. Renal tubule injury due to ischemia (11%)

D. Renal tubule injury due to protein casts (2%)

✓ E. Urethral compression (58%)

Omitted
Correct answer
E

58%
Answered correctly

01 sec
Time Spent

01/16/2020
Last Updated

Explanation

This patient with **anuria** and **suprapubic fullness** (suggesting a distended bladder) has **acute urinary retention** (AUR). AUR is characterized by the inability to voluntarily micturate, which leads to suprapubic pain with **bladder distension**, often palpable above the pelvic brim. As urine refluxes into the ureters and kidneys, dilation of the ureters, renal pelvis, and calyces (hydronephrosis) results in **acute kidney injury**, bilateral flank pain, and costovertebral angle tenderness. Elevations in creatinine and blood urea nitrogen are also common, but the ratio between the two is variable.

Explanation

This patient with **anuria** and **suprapubic fullness** (suggesting a distended bladder) has **acute urinary retention** (AUR). AUR is characterized by the inability to voluntarily micturate, which leads to suprapubic pain with **bladder distension**, often palpable above the pelvic brim. As urine refluxes into the ureters and kidneys, dilation of the ureters, renal pelvis, and calyces (hydronephrosis) results in **acute kidney injury**, bilateral flank pain, and costovertebral angle tenderness. Elevations in creatinine and blood urea nitrogen are also common, but the ratio between the two is variable.

Etiologies of AUR include:

- Bladder outlet obstruction: By far the most common cause of urinary retention, bladder outlet obstructions are precipitated by **urethral compression**, typically due to **benign prostatic hyperplasia** (particularly in men age >50). Other etiologies include transitional cell carcinoma, and rectal or uterine malignancy.
- Medications: AUR is commonly caused by anticholinergic medications (eg, oxybutynin, atropine) and sympathomimetics (eg, pseudoephedrine).
- Neurologic dysfunction: Diabetic neuropathy, spinal cord injury, and stroke can result in a neurogenic bladder.

**(Choice A)** Diabetic nephropathy typically presents with proteinuria and chronic kidney disease rather than acute anuria with bilateral flank pain. This patient had normal baseline renal function 4 weeks ago, ruling out chronic kidney disease.

**(Choice B)** Interstitial nephritis typically occurs after introduction of new medications and is often accompanied by fever and rash. It can cause impaired urine production (oliguria), but an overly distended bladder and flank pain would be unexpected.

**(Choices C and D)** Ischemia (eg, due to hypotension) can cause tubular necrosis. Abundant protein casts can form in multiple myeloma, leading to obstruction and necrosis of the renal tubules. Both cause intrinsic renal injury with an elevation in creatinine; however, a distended bladder would be unexpected.

**Educational objective:**
Acute urinary retention is characterized by anuria and bladder distension, and can result in hydronephrosis and acute kidney injury. A palpable, distended bladder is present on examination, and abdominal and flank pain may be present. The most common cause of urinary retention is

Etiologies of AUR include:

- Bladder outlet obstruction: By far the most common cause of urinary retention, bladder outlet obstructions are precipitated by **urethral compression**, typically due to **benign prostatic hyperplasia** (particularly in men age >50). Other etiologies include transitional cell carcinoma, and rectal or uterine malignancy.
- Medications: AUR is commonly caused by anticholinergic medications (eg, oxybutynin, atropine) and sympathomimetics (eg, pseudoephedrine).
- Neurologic dysfunction: Diabetic neuropathy, spinal cord injury, and stroke can result in a neurogenic bladder.

**(Choice A)** Diabetic nephropathy typically presents with proteinuria and chronic kidney disease rather than acute anuria with bilateral flank pain. This patient had normal baseline renal function 4 weeks ago, ruling out chronic kidney disease.

**(Choice B)** Interstitial nephritis typically occurs after introduction of new medications and is often accompanied by fever and rash. It can cause impaired urine production (oliguria), but an overly distended bladder and flank pain would be unexpected.

**(Choices C and D)** Ischemia (eg, due to hypotension) can cause tubular necrosis. Abundant protein casts can form in multiple myeloma, leading to obstruction and necrosis of the renal tubules. Both cause intrinsic renal injury with an elevation in creatinine; however, a distended bladder would be unexpected.

**Educational objective:**
Acute urinary retention is characterized by anuria and bladder distension, and can result in hydronephrosis and acute kidney injury. A palpable, distended bladder is present on examination, and abdominal and flank pain may be present. The most common cause of urinary retention is bladder outlet obstruction (urethral compression) due to benign prostatic hyperplasia.

| Pathology | Renal, Urinary Systems & Electrolytes | Urinary tract obstruction |
|---|---|---|
| Subject | System | Topic |

Copyright © UWorld. All rights reserved.

A 62-year-old hospitalized man is evaluated for new-onset renal failure. The patient was admitted 3 days ago due to precordial chest pain. He was found to have an elevated troponin I level but no ST-segment elevation on ECG. Percutaneous catheterization revealed 3-vessel coronary artery disease, and no coronary interventions were performed. The patient has continued to receive medical treatment while awaiting coronary artery bypass graft surgery. Today, he was noted to have elevated blood urea nitrogen and serum creatinine levels. The patient has had no fever, and blood pressure and heart rate have been within normal limits. Physical examination shows no new findings. Which of the following pathologic findings is most likely present in this patient?

A. Diffuse necrosis of the proximal tubular cells

B. Extensive crescents in the glomeruli

C. Fibrin-like material lining the arteriolar walls

D. Mononuclear cell infiltrate in the interstitium

E. Needle-shaped clefts in the arterioles

Submit

A 62-year-old hospitalized man is evaluated for new-onset renal failure. The patient was admitted 3 days ago due to precordial chest pain. He was found to have an elevated troponin I level but no ST-segment elevation on ECG. Percutaneous catheterization revealed 3-vessel coronary artery disease, and no coronary interventions were performed. The patient has continued to receive medical treatment while awaiting coronary artery bypass graft surgery. Today, he was noted to have elevated blood urea nitrogen and serum creatinine levels. The patient has had no fever, and blood pressure and heart rate have been within normal limits. Physical examination shows no new findings. Which of the following pathologic findings is most likely present in this patient?

- ✓ A. Diffuse necrosis of the proximal tubular cells (49%)
- B. Extensive crescents in the glomeruli (6%)
- C. Fibrin-like material lining the arteriolar walls (14%)
- D. Mononuclear cell infiltrate in the interstitium (6%)
- E. Needle-shaped clefts in the arterioles (22%)

Omitted
Correct answer
A

49%
Answered correctly

03 secs
Time Spent

03/09/2020
Last Updated

Explanation

| Contrast-induced nephropathy | |
|---|---|
| Presentation | • Acute rise in serum creatinine and blood urea nitrogen 24-48 hr after contrast administration, followed by a |

| Contrast-induced nephropathy | |
|---|---|
| **Presentation** | • Acute rise in serum creatinine and blood urea nitrogen 24-48 hr after contrast administration, followed by a gradual return to baseline |
| **Etiology** | • Direct cytotoxicity of intravenous contrast on tubular cells<br>• Renal vasoconstriction |
| **Laboratory findings** | • Histology: extensive necrosis of proximal tubular cells<br>• Muddy brown casts on urinalysis |

This patient developed acute kidney injury after undergoing percutaneous catheterization, a procedure that uses contrast material to evaluate the patency of the coronary arteries. In a patient with normal vital signs, this presentation suggests **contrast-induced nephropathy** (CIN). Patients with CIN typically have an acute rise in creatinine and blood urea nitrogen within 24-48 hours of contrast administration, followed by a gradual return to baseline.

The etiology of CIN remains unclear but is likely multifactorial and includes:

- Direct cytotoxicity causing acute tubular necrosis, resulting in **diffuse necrosis of the proximal tubular cells** visible on histologic specimens and **muddy brown casts** on urinalysis
- Renal vasoconstriction causing medullary ischemia

Preventive measures include avoidance of nonsteroidal anti-inflammatory drugs, which can worsen vasoconstriction, periprocedural administration of intravenous normal saline, and using the smallest possible volume of contrast medium.

**(Choice B)** Glomerular crescents are seen in crescentic glomerulonephritis, which can occur in multiple renal diseases (eg, Goodpasture syndrome, microscopic polyangiitis). However, patients typically have nephritic syndrome, characterized by hematuria with red blood cell casts, hypertension, and edema.

**(Choice C)** Fibrinoid necrosis is visualized histologically as fibrin material lining the arteriolar walls. This pattern is typically seen in the setting of

return to baseline.

The etiology of CIN remains unclear but is likely multifactorial and includes:

- Direct cytotoxicity causing acute tubular necrosis, resulting in **diffuse necrosis of the proximal tubular cells** visible on histologic specimens and **muddy brown casts** on urinalysis
- Renal vasoconstriction causing medullary ischemia

Preventive measures include avoidance of nonsteroidal anti-inflammatory drugs, which can worsen vasoconstriction, periprocedural administration of intravenous normal saline, and using the smallest possible volume of contrast medium.

**(Choice B)** Glomerular crescents are seen in crescentic glomerulonephritis, which can occur in multiple renal diseases (eg, Goodpasture syndrome, microscopic polyangiitis). However, patients typically have nephritic syndrome, characterized by hematuria with red blood cell casts, hypertension, and edema.

**(Choice C)** Fibrinoid necrosis is visualized histologically as fibrin material lining the arteriolar walls. This pattern is typically seen in the setting of hypertensive (malignant) nephrosclerosis, which occurs due to markedly elevated blood pressure causing vascular endothelial damage. This patient's blood pressure has been normal.

**(Choice D)** Mononuclear cell infiltrate in the interstitium is consistent with interstitial nephritis. Interstitial nephritis typically occurs after initiation of new drugs (eg, penicillin, cephalosporin) and typically presents with fever, rash, and sterile pyuria.

**(Choice E)** Needle-shaped clefts in the arterioles is seen in atheroembolization (ie, embolization of cholesterol plaques), which can occur following coronary angiography; however, it typically presents with sequelae of atheroemboli in other organs and tissues (eg, livedo reticularis, blue toes).

**Educational objective:**
Contrast-induced nephropathy is characterized by an acute rise in creatinine and blood urea nitrogen after radiologic contrast administration, followed by a gradual return to baseline. It is characterized histologically by diffuse necrosis of the proximal tubular cells (ie, acute tubular necrosis). Urinalysis usually demonstrates muddy brown casts.

return to baseline.

Exhibit Display

## Crescentic glomerulonephritis

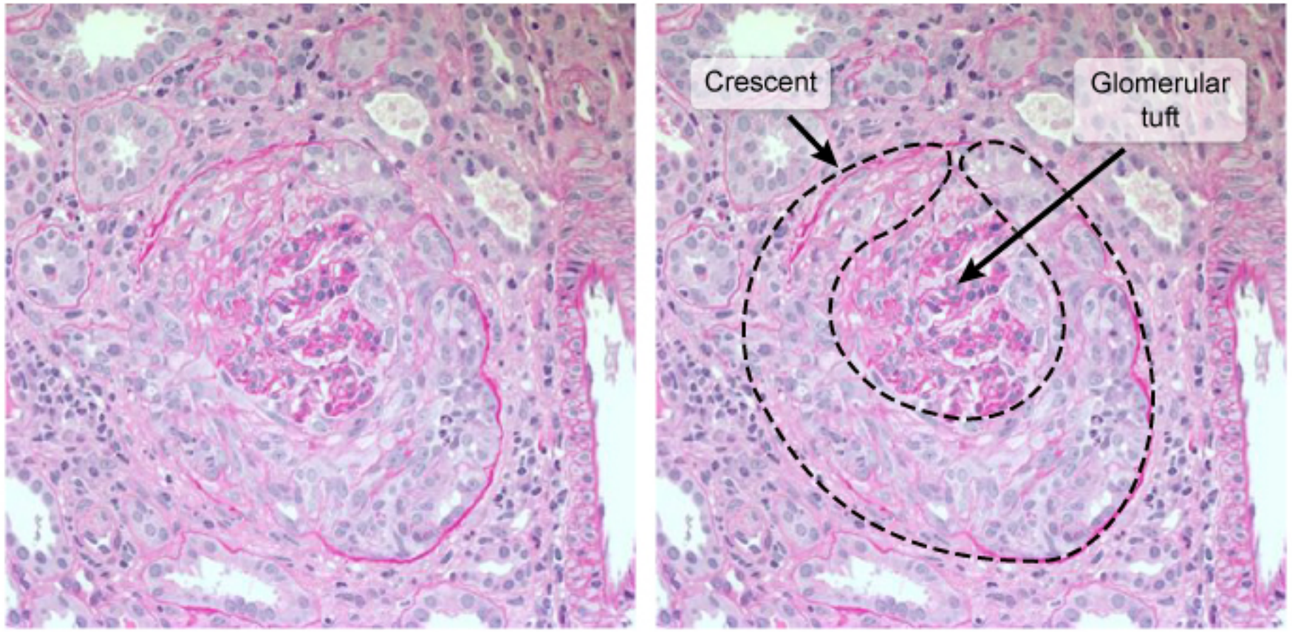


©UWorld

Zoom In | Zoom Out | Reset | Add To Flash Card